

## SHORT REPORT



WILEY

# Biallelic *TMEM260* variants cause truncus arteriosus, with or without renal defects

Alistair T. Pagnamenta<sup>1</sup> | Adam Jackson<sup>2,3</sup> | Rahat Perveen<sup>2</sup> | Glenda Beaman<sup>2</sup> | Gemma Petts<sup>4</sup> | Asheeta Gupta<sup>5</sup> | Zerin Hyder<sup>2</sup> | Brian Hon-Yin Chung<sup>6</sup> | Anita Sik-Yau Kan<sup>7</sup> | Ka Wang Cheung<sup>7</sup> | Wilhelmina S. Kerstjens-Frederikse<sup>8</sup> | Kristin M. Abbott<sup>8</sup> | Genomics England Research Consortium | Orly Elpeleg<sup>9</sup> | Jenny C. Taylor<sup>1</sup> | Siddharth Banka<sup>2,3</sup> | Asaf Ta-Shma<sup>10</sup>

<sup>1</sup>NIHR Biomedical Research Centre, Wellcome Centre for Human Genetics, University of Oxford, Oxford, UK

<sup>2</sup>Division of Evolution, Infection and Genomics, University of Manchester, Manchester, UK

<sup>3</sup>Manchester Centre for Genomic Medicine, St. Mary's Hospital, Manchester University NHS Foundation Trust, Health Innovation Manchester, Manchester, UK

<sup>4</sup>Department of Paediatric Histopathology, Royal Manchester Children's Hospital, Manchester, UK

<sup>5</sup>Birmingham Children's Hospital, Birmingham, UK

<sup>6</sup>Department of Paediatrics and Adolescent Medicine, LKS Faculty of Medicine, The University of Hong Kong, Pok Fu Lam, Hong Kong

<sup>7</sup>Department of Obstetrics and Gynaecology, Queen Mary Hospital, Pok Fu Lam, Hong Kong

<sup>8</sup>Department of Genetics, University of Groningen, University Medical Center Groningen, Groningen, the Netherlands

<sup>9</sup>Department of Genetics, Hadassah Medical Organization and Faculty of Medicine, Hebrew University of Jerusalem, Jerusalem, Israel

<sup>10</sup>Department of Pediatric Cardiology, Hadassah Medical Organization and Faculty of Medicine, Hebrew University of Jerusalem, Jerusalem, Israel

## Correspondence

Asaf Ta-Shma, Department of Pediatric Cardiology, Hadassah Medical Organization and Faculty of Medicine, Hebrew University of Jerusalem, Jerusalem, Israel.  
Email: atashma@gmail.com

Siddharth Banka, Division of Evolution, Infection and Genomics, University of Manchester, Manchester, UK.  
Email: siddharth.banka@manchester.ac.uk

## Funding information

Cancer Research UK; European Union's Horizon 2020, Grant/Award Number: 779257; Medical Research Council; NHS England; NIHR Oxford Biomedical Research Centre Programme; Society for the Relief of Disabled Children, Hong Kong; Wellcome Trust, Grant/Award Number: 203141/Z/16/Z

## Abstract

Only two families have been reported with biallelic *TMEM260* variants segregating with structural heart defects and renal anomalies syndrome (SHDRA). With a combination of genome, exome sequencing and RNA studies, we identified eight individuals from five families with biallelic *TMEM260* variants. Variants included one multi-exon deletion, four nonsense/frameshifts, two splicing changes and one missense change. Together with the published cases, analysis of clinical data revealed ventricular septal defects (12/12), mostly secondary to truncus arteriosus (10/12), elevated creatinine levels (6/12), horse-shoe kidneys (1/12) and renal cysts (1/12) in patients. Three pregnancies were terminated on detection of severe congenital anomalies. Six patients died between the ages of 6 weeks and 5 years. Using a range of stringencies, carrier frequency for SHDRA was estimated at 0.0007–0.007 across ancestries. In conclusion, this study confirms the genetic basis of SHDRA, expands its known mutational spectrum and clarifies its clinical features. We demonstrate that SHDRA is a

The member of Genomics England Research Consortium are present in Appendix.

Alistair T. Pagnamenta, Adam Jackson, Siddharth Banka and Asaf Ta-Shma contributed equally to this work.

This is an open access article under the terms of the Creative Commons Attribution License, which permits use, distribution and reproduction in any medium, provided the original work is properly cited.

© 2021 The Authors. *Clinical Genetics* published by John Wiley & Sons Ltd.

severe condition associated with substantial mortality in early childhood and characterised by congenital cardiac malformations with a variable renal phenotype.

#### KEYWORDS

exome sequencing, genome sequencing, kidney, phenotypic variability, renal failure, SHDRA, structural heart defects and renal anomalies syndrome, *TMEM260*, truncus arteriosus

## 1 | INTRODUCTION

*TMEM260* is a 79.5 kDa protein with eight transmembrane spans ([www.uniprot.org/uniprot/Q9NX78](http://www.uniprot.org/uniprot/Q9NX78)) located mainly in the nucleoplasm and within focal adhesion sites ([www.proteinatlas.org](http://www.proteinatlas.org)).<sup>1</sup> *TMEM260* encodes at least four protein-coding transcripts. Of these, two (ENST00000261556.11 and ENST00000538838.5) are considered to be the main transcripts. They differ in the utilisation of an internal exon as well as the final three exons, which in the short isoform are non-coding.

Five individuals from two families with biallelic truncating *TMEM260* variants and brain, cardiac, renal, and digit abnormalities were reported in 2017.<sup>2</sup> The condition is now listed on OMIM as “structural heart defects and renal anomalies syndrome” (SHDRA; MIM #617478). Notably, the variants in both families mapped to the long isoform, raising the possibility of SHDRA being an isoform-specific disorder. Since the original publication, there have been no further reports in the literature. Knowledge about the variant and the clinical spectrum of this condition is therefore limited (Supplementary background). In this study, we describe eight affected individuals from five families, confirming that biallelic *TMEM260* loss of function variants cause SHDRA and helping to define its clinical spectrum.

## 2 | MATERIALS AND METHODS

Whole genome sequencing in Families 1 and 2 was performed as part of the 100 000 genomes project (100KGP; <https://doi.org/10.6084/m9.figshare.4530893.v6>, Cambridge South REC: 14/EE/1112). Families 3–5 were identified via whole exome sequencing (WES) pipelines and international collaboration. RNA analysis was performed for Family 1 using PaxGene blood samples. Carrier frequency for SHDRA was calculated as described previously.<sup>3</sup> More details are in Supplemental methods and Tables S1–S2.

## 3 | RESULTS

### 3.1 | Compound-heterozygous *TMEM260* variants in fetuses with congenital heart anomalies

In F1-II-3 (Figure 1A), type I truncus arteriosus (TA) with pulmonary stenosis and ventricular septal defect (VSD) were detected on antenatal anomaly scan at 20 weeks gestation (Table 1). The pregnancy was

terminated at 21 weeks. Post-mortem examination confirmed the cardiac anomalies (Figure S1) and did not reveal any other abnormalities. In F1-II-4 a large peri-membranous outlet VSD, type I TA with small pulmonary trunk and small pulmonary artery branches were detected antenatally and the pregnancy was terminated at 24 weeks gestation. Post-mortem examination confirmed the cardiac anomalies and revealed a horseshoe kidney. The placenta was also abnormal with a two-vessel cord and omphalomesenteric duct remnant.

Trio WGS was performed as part of the 100KGP on F1-II-4 and both parents. Although the initial analysis focussing on several panels from PanelApp was negative, a scan for Mendelian inconsistencies highlighted an apparently homozygous NM\_017799.4:c.344G > A:p.(Arg115Lys) *TMEM260* variant in F1-II-4 (Figure 1B). As expected, the father (F1-I-1) was heterozygous for the c.344G > A *TMEM260* variant, but the mother (F1-I-2) was apparently homozygous for the wild-type allele. Review of read alignments revealed a maternally inherited 4891 bp deletion (Figure 1B) encompassing exons 2–3. Sanger sequencing and digital droplet PCR confirmed that F1-II-3 was also hemizygous for c.344G > A. Neither of the unaffected brothers (F1-II-1 and F1-II-2) had inherited both *TMEM260* variants.

Although the c.344G > A variant was initially annotated as p.Arg115Lys, it involves the last base of exon 3 and results in a drop in the predicted splicing efficiency (MaxEntScan: 9.65 → 2.69). We, therefore, performed RT-PCR on peripheral blood sample from F1-I-1, which showed the presence of two bands, with only the larger band seen in controls (Figure 1C). Sanger sequencing confirmed exon 3 skipping (Figure 1D, Figure S2), resulting in a frameshift of exon 4 (p.Val65AlafsTer32). Similarly, the expected exon 1–4 junction was detected by RT-PCR in the maternal sample (Figure S3), resulting in p.(Glu55PhefsTer20). Collectively, the genetic studies, RNA analysis and similarity of the fetuses' phenotypes with features reported previously,<sup>2</sup> strongly suggest these *TMEM260* variants are disease-causing.

### 3.2 | Identification of additional SHDRA patients

To expand the cohort of patients with SHDRA we interrogated the 100KGP database further and identified a homozygous c.1410C > G:p.Tyr470Ter *TMEM260* variant in Family 2 (Figure 1E). F2-II-2 exhibited a common arterial trunk, tricuspid atresia, VSD, partial anomalous pulmonary venous connection, bilateral hearing loss, global developmental delay, protein losing enteropathy and deteriorating renal function from the age of 15 months (Figure S4). Multi-organ

**TABLE 1** Genetic and clinical information for five newly reported families with rare biallelic variants in *TMEM260*. cDNA and protein coordinates are based on the longer canonical isoform (NM\_017799.4)

Family number	Family 1	Family 2	Family 3	Family 4	Family 5	Ta-Shma et al. 2017 <sup>2</sup>	Totals
Ethnicity	White British	Pakistani	Ashkenazi Jewish	Sudanese	Chinese	Ashkenazi Jewish, Arabic	White British, Pakistani, Arabic, Ashkenazi Jewish (2), Sudanese, Chinese
Parental consanguinity	No	Yes	No	No (no ROH >10 Mb detected)	No	2/2 Families	3/7 Families
Genomic coordinates (GRCh38)	chr14:5658912G > A, chr14:56582233-56587124del <sup>p</sup>	chr14:56625393C > G	chr14:56621697C > T, chr14:56633089GT > G	chr14:56633141GTAT C > G	chr14:5658759A > G, chr14:56634918G > C	chr14:56621697C > T, chr14:56633141GTAT C > G	–
cDNA coordinates	c.(344G > A)(161_344del)	c.1410C > G	c.(1393C > T)(1644delT)	c.1698_1701delCTAT	c.193-2A > G, c.174AG > C	c.1393C > T, c.1698_1701delCTAT	–
Protein coordinates	p.(Arg115Lys <sup>20</sup> ); (Glu55Phefs*20)	p.Tyr470Ter	p.(Gln465Ter)(Pro549Leufs*46)	p.Tyr567Thrfs*27	p.(?) (Glu582Gln)	p.Gln465Ter, p.Tyr567Thrfs*27	2 stopgain, 2 frameshift, one multi-exon deletion, one missense/splice
CADD (splice predictions)	34 (SpliceAI = 0.69, MaxEntScan diff = 6.964), NA	34	41 (SpliceAI = 0.06), 32	NA	34 (SpliceAI = 1.00, MaxEntScan diff = 7.955), 28.3	41 (SpliceAI = 0.06), NA	28.3–41
Isoforms involved	Short and long	Long	Long	Long	Short and long, long	Long	–
gnomAD AF (v.2.1.1)	2/249706; NA	2/250342	19/273758, 2/251170	Absent	Absent, absent	19/273758, absent	Allele counts of 0–19
Individual ID	F1-II-3	F2-II-2	F3-II-2	F4-II-2	F5-II-1	NA	–
Gender	Female	Male	Male	Male	Female	2 M, 2F	7 M, 5F
Methods	Sanger sequencing	Trio genome sequencing (HiSeqX) as part of 100KGP	Exome + Sanger	Exome + Sanger	Exome + Sanger	Duo exome sequencing (Agilent Sureselect)	Sanger, exome and genome sequencing
Deceased	TOP at 21 weeks	TOP at 24 weeks	Died at 5 years	Died at 3 months	No (currently 5 years old)	Died at 4 months	3/4 are deceased (6 weeks, 2 months, 1 year)
Cardiac defects	–	–	–	–	–	–	–
Septal defect(s)	VSD	VSD (subvalvular)	VSD	VSD	VSD	VSD	VSD 4/4, ASD 1/4
Truncus arteriosus	+ (type I)	+ (type I)	+ (type I, s/p complete repair)	+ (type I, complete repair at 1 week of age)	+ (type I, complete repair at 1 week of age)	+ (type I)	10/12
Tetralogy of Fallot, pulmonary atresia and major aortopulmonary collateral arteries	–	–	–	–	–	–	4/12
Pulmonary stenosis	+	+	–	–	–	–	–
Interrupted aortic arch	–	–	–	–	–	–	1/12
Right aortic arch	–	–	–	–	–	+	2/12

(Continues)

TABLE 1 (Continued)

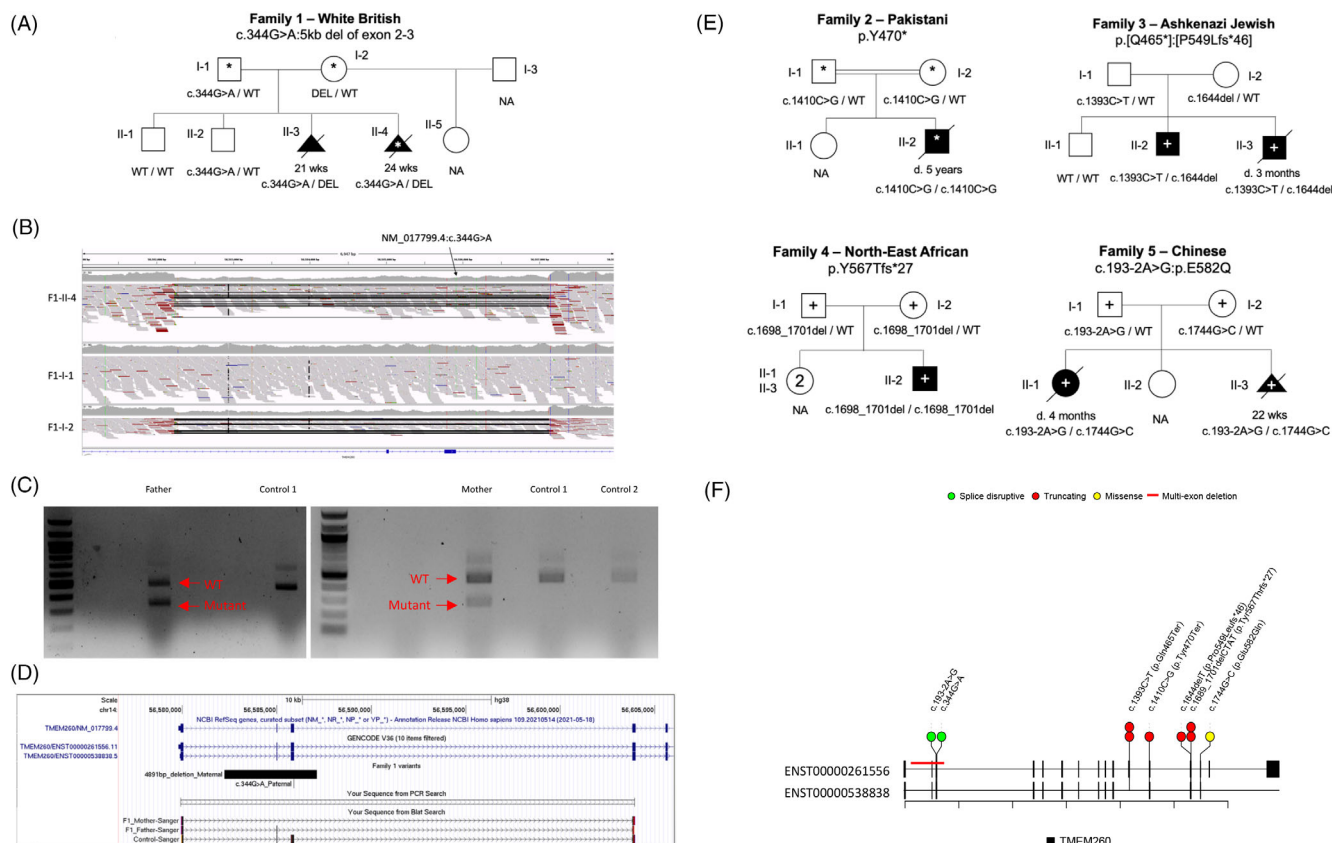
Cardiac defects									
Tricuspid valve atresia	-	-	-	-	-	-	-	1/4	2/12
Partial anomalous pulmonary venous return	-	-	-	-	-	-	-	1/4	2/12
+ (Partially anomalous pulmonary venous connection(s)-left pulmonary vein--innominate)									
Neurodevelopmental defects									
Agenesis of corpus callosum	-	-	-	-	-	-	-	-	2/3
Microcephaly	-	-	-	-	-	-	-	-	1/4
Developmental delay	N/A	N/A	+	-	N/A	-	N/A	N/A	-
Renal defects									
Renal failure	N/A	N/A	-	-	+	+	+	N/A	-
Elevated creatinine levels (normal: 0.2-0.9 mg/dl)	N/A	N/A	-	-	-	-	-	N/A	3/3 elevated (1.3-1.9 mg/dl)
Anuria/Oliguria	N/A	N/A	-	-	+	-	-	N/A	2/4
Urine protein	N/A	N/A	-	-	-	-	-	N/A	NA
Renal cysts	-	-	-	-	-	-	-	-	1/4
Horseshoe kidney	-	+	-	-	-	-	-	NA	1/12
Limb defects									
Polydactyly	-	-	-	-	-	-	-	-	1/4
Overriding toes	-	-	-	-	-	-	-	-	1/4
Other									
Other features									
Prenatal findings/polyhydramnios	Two-vessel cord with omphalomesenteric duct remnant. Non-transformed maternal decidua vessels associated with extra-placental membranes (of uncertain significance)							Single umbilical artery	
Hearing loss, upper respiratory tract infection requiring PICU, protein losing enteropathy, cyanosis								Vertical midline linear skin defect over chest wall, single umbilical artery, left pre-auricular sinus necrotizing enterocolitis with perforation of transverse colon at day 10	Edema (3/4), cyanosis (2/4), facial dysmorphism (1/4), low set ears (1/4), webbed neck (1/4), hypotonia (1/4), bilateral preauricular skin tags (1/4), facial port-wine nevus (1/4), undescended right testis (1/4)
Severe and prolonged chylothorax following surgery									
No									

Abbreviations: ASD, atrial septal defect; NA, not available; N/A, not applicable; ROH, region of homozygosity; VSD, ventricular septal defect.

\*Deletion removes exons 2 and 3.

<sup>b</sup>Annotated as missense but results in exon skipping and c.193\_344del:p.(Val65AlaIns\*32) in a splicing defect.

<sup>c</sup>Only molecularly confirmed cases from T-a-Shma et al. 2017 (PMID: 28318500) are included.



**FIGURE 1** Clinical and variant spectrum of SHDRA. (A) Pedigree of Family 1. (B) IGV screenshot showing Illumina read-alignments supporting a rare deletion of *TMEM260*. Split read pairs (red) indicate the start and end of the deletion, concomitant with a drop in coverage. The deletion is inherited from the mother and resolves the Mendelian inconsistency. Figure S9 shows a zoomed in view of c.344G > A. (C) RT-PCR results for Family 1. A larger band is seen in all samples, representing the wild-type allele. Smaller bands are seen in both paternal and maternal samples. (D) Custom UCSC session showing position of the maternal deletion and paternal c.344G > A. RT-PCR primer positions are indicated by in silico PCR. FASTA sequences generated by Sanger sequencing (Blat Search) indicate exon 3 skipping in the father and exon 2–3 skipping in the mother. (E) Pedigrees and genetic segregation results for four other families with biallelic *TMEM260* variants. NA, DNA unavailable; \*, sequencing as part of the 100KGP; +, exome sequencing. (F) Distribution of variants found in this study. c.1393C > T and c.1689\_1701delCTAT (double circles) were previously described.<sup>2</sup> The last three exons of isoform ENST00000538838 (grey) are non-coding, hence the only variants to affect both isoforms are c.193-2A > G, c.344G > A and the deletion [Colour figure can be viewed at wileyonlinelibrary.com]

failure following cardiac surgery led to death at age 5 (Table S1, Supplementary Case Histories).

Through international collaboration, we uncovered three further families ascertained via WES (Figure 1E,F). This included a novel c.1644del:p.Pro549LeufsTer46 allele *in trans* with the previously described<sup>2</sup> c.1393C > T:p.Gln465Ter in a sib-pair (Family 3). The elder brother presented with type I TA, mild truncal valve insufficiency, a large VSD, with normal renal function (max. Creatinine of 39  $\mu\text{mol/L}$ ) and normal neurodevelopment at the age of 5 years. The younger brother was born with Type I TA, mild to moderate truncal valve insufficiency and a large VSD (Video S1). A few days after cardiac surgery he developed severe chylothorax and progressive renal failure (Figure S5) and died at approaching 4 months from multi-organ failure. In Family 4 we identified previously described<sup>2</sup> homozygous c.1698\_1701del:p.Tyr567ThrfsTer27 *TMEM260* variant in 2 year old boy with Type I TA and VSD, and normal renal function (maximum creatinine level of 37  $\mu\text{mol/L}$ ) and normal neurodevelopment. In Family 5 we identified novel compound-heterozygous *TMEM260* variants: c.193-2A > G and

c.1744G > C:p.Glu582Gln in a girl who died at the age of 4 months. The missense variant is predicted damaging by SIFT/PolyPhen2. The girl was born with TA type I, hypoplastic right ventricle, small main and branch pulmonary arteries, VSD and atrial septal defect. During her neonatal period, she developed necrotizing enterocolitis with perforation of transverse colon, renal impairment (Figure S6) and died at 4 months. Type I TA and VSD were detected antenatally in the proband's sibling (Figure S7) and the pregnancy was terminated at 22 weeks. The same compound-heterozygous *TMEM260* variants were also identified in the foetus.

### 3.3 | SHDRA carrier frequency is 0.7–7 per 1000 individuals

Next, we estimated the carrier frequency of SHDRA using a range of stringency thresholds (Figure S8A). The most stringent criteria included only variants that would be predicted to result in loss-of-

function (without low-confidence flags) and known ClinVar pathogenic or likely pathogenic variants. The least stringent criteria included all variants with a CADD score over 30, a spliceAI score over 0.8 as well as loss-of-function alleles and ClinVar pathogenic and likely pathogenic alleles. This analysis showed that per-ancestry gene carrier rate (GCR) for *TMEM260* ranges between 0.001 and 0.007 for least stringent parameters to 0.0007–0.005 for the most stringent. Only 16/94 predicted deleterious variants using the lowest stringency threshold are missense variants (Figure S8B). The GCR was found to be higher in individuals with African/African-American ancestry and lowest in Finnish ancestry. The higher GCR in the African/African-American population is due to a possible founder variant (p.Lys696ThrfsTer7, rs568247949) which has “Likely pathogenic” status in ClinVar with a single submission (SCV000992576.2).

## 4 | DISCUSSION

We present eight individuals, from five independent families, with biallelic *TMEM260* variants (Figure 1). In combination with clinical data published previously,<sup>2</sup> our results suggest congenital cardiac malformations to be the most consistent phenotype of SHDRA. All 12 patients are reported to have VSD and 10/12 had TA (Table 1). In most of these patients, VSD is likely to be secondary to TA. Notably, TA is one of the rarest congenital cardiac anomalies with few known genetic associations in *NKX2-5*,<sup>4</sup> *NKX2-6*,<sup>5</sup> *GATA6*<sup>6</sup> as well as *TBX1*.<sup>7</sup> Interestingly, *TMEM260*, is predicted to be one of 1442 target genes for *GATA6* predicted using known transcription factor binding site motifs from the TRANSFAC dataset.<sup>8</sup> The JASPAR database of transcription factor binding sites predicts a *GATA6* binding site within intron 5 of *TMEM260* although the functionality of this motif is unknown.<sup>9</sup>

Our results show that the renal phenotype of SHDRA is highly variable. Horseshoe kidney and cysts were noted in one patient each. The renal failure seen in three individuals could be pre-renal injury and acute tubular necrosis secondary to cardiac failure and systemic illness. However, the decline in glomerular filtration prior to the onset of cardiac failure in F2-II-2 suggests the possibility of underlying renal dysfunction. Further studies should address whether the variable renal involvement is secondary to cardiac complications or a primary component of the condition. The intra-familial variability in renal phenotype indicates that this may not be solely due to the precise *TMEM260* variant(s) that are involved. A more likely hypothesis is that there is a congenital predisposition to renal failure, leaving the individual vulnerable to a rapid deterioration that can be precipitated by clinical (e.g., cardiac/intestinal) insults.

The combination of congenital heart disease, especially conotruncal defects with renal abnormalities is unusual. Conotruncal abnormalities are seen in 22q11.21 deletion syndrome, in which renal abnormalities, such as hypoplasia or agenesis of the kidney, multicystic dysplasia and vesicoureteral reflux, are thought to occur in over 30% of patients.<sup>10</sup> Another dominant disorder with some phenotypic overlap, including TA and hypoplastic kidneys, is Townes-Brocks syndrome (MIM #107480) due to heterozygous mutations in

*SALL1*.<sup>11,12</sup> The association of cardiac, cerebral and renal malformations is also reminiscent of ciliopathies, although generally the cardiac features linked to these group of disorders do not include TA.

Antenatal detection of severe congenital malformations led to termination of pregnancy in three cases described here. Out of nine live born pregnancies, six patients died within the age ranges of 6 weeks to 5 years. One of the two individuals whom survived to 5-years old (F2-II-2) had developmental delay and hearing loss. However, due to insufficient numbers it is difficult to confidently associate these features with SHDRA. We note that two other individuals in the present study who survived beyond their first year, were cognitively normal. Although facial dysmorphism was reported in 1/4 of the original cohort, that feature was not replicated here.

This study substantially expands the known mutation spectrum of SHDRA. Including the patients presented here, a total of eight different *TMEM260* variants in 12 individuals from seven families have now been identified (Figure 1F). Of these, two variants are stop-gains, two are frameshifts, one is a multi-exon deletion, two disrupt splicing and one is missense. All variants are supported by in silico tools, including CADD scores, which are 28.3–41 (Table 1). The distribution of the variants confirms that variants affecting only the longer isoform are sufficient to cause SHDRA.

We show that the carrier frequency for SHDRA could be up to 1 in 140 in certain populations (Figure S8). This analysis also identified a potential founder variant in the African/African-American population that requires further functional studies to validate its “Likely Pathogenic” status in ClinVar. The c.1698\_1701del seen in Family 4 and in an Arabic family described previously<sup>2</sup> may also represent a founder mutation.

In conclusion, our description of five families with biallelic *TMEM260* variants confirms the genetic basis of SHDRA and helps delineate the mutational/phenotypic spectrum of the condition. The strong association with TA has important implications for genetic counselling, prenatal diagnostics as well as postnatal targeted genetic testing.

## ACKNOWLEDGEMENTS

We thank Katherine Bull for critical comments. Support was provided by the NIHR Oxford Biomedical Research Centre, the Wellcome Trust (203141/Z/16/Z), the Society for the Relief of Disabled Children, Hong Kong (BHC) and Solve-RD (SB, AJ). The Solve-RD project received funding from the European Union's Horizon 2020 research and innovation program (grant 779257).

## CONFLICT OF INTEREST

No conflicting interests are declared.

## PEER REVIEW

The peer review history for this article is available at <https://publons.com/publon/10.1111/cge.14071>.

## DATA AVAILABILITY STATEMENT

Researchers can apply to access 100KGP data at [www.genomicsengland.co.uk/join-a-gecip-domain](http://www.genomicsengland.co.uk/join-a-gecip-domain). Other data can be made available upon request.

## ORCID

Alistair T. Pagnamenta  <https://orcid.org/0000-0001-7334-0602>

Brian Hon-Yin Chung  <https://orcid.org/0000-0002-7044-5916>

## REFERENCES

- Uhlen M, Fagerberg L, Hallström BM, et al. Proteomics. Tissue-based map of the human proteome. *Science*. 2015;347:1260419. doi:10.1126/science.1260419
- Ta-Shma A, Khan TN, Vivante A, et al. Mutations in TMEM260 cause a pediatric neurodevelopmental, cardiac, and renal syndrome. *Am J Hum Genet*. 2017;100:666-675. doi:10.1016/j.ajhg.2017.02.007
- Guo MH, Gregg AR. Estimating yields of prenatal carrier screening and implications for design of expanded carrier screening panels. *Genet Med*. 2019;21:1940-1947. doi:10.1038/s41436-019-0472-7
- Su W, Zhu P, Wang R, et al. Congenital heart diseases and their association with the variant distribution features on susceptibility genes. *Clin Genet*. 2017;91:349-354. doi:10.1111/cge.12835
- Ta-Shma A, el-lahham N, Edvardson S, et al. Conotruncal malformations and absent thymus due to a deleterious NKX2-6 mutation. *J Med Genet*. 2014;51:268-270. doi:10.1136/jmedgenet-2013-102100
- Zhang E, Hong N, Chen S, et al. Targeted sequencing identifies novel GATA6 variants in a large cohort of patients with conotruncal heart defects. *Gene*. 2018;641:341-348. doi:10.1016/j.gene.2017.10.083
- Yagi H, Furutani Y, Hamada H, et al. Role of TBX1 in human del22q11.2 syndrome. *Lancet*. 2003;362:1366-1373. doi:10.1016/s0140-6736(03)14632-6
- Matys V, Fricke E, Geffers R, et al. TRANSFAC: transcriptional regulation, from patterns to profiles. *Nucleic Acids Res*. 2003;31:374-378. doi:10.1093/nar/gkg108
- Fornes O, Castro-Mondragon JA, Khan A, et al. JASPAR 2020: update of the open-access database of transcription factor binding profiles. *Nucleic Acids Res*. 2020;48:D87-D92. doi:10.1093/nar/gkz1001
- Van Batavia JP et al. Anomalies of the genitourinary tract in children with 22q11.2 deletion syndrome. *Am J Med Genet A*. 2019;179:381-385. doi:10.1002/ajmg.a.61020
- Barakat AY, Butler MG, Salter JE, Fogo A. Townes-brocks syndrome: report of three additional patients with previously undescribed renal and cardiac abnormalities. *Dysmorphol Clin Genet*. 1988;2:104-108.
- Kiefer SM, Ohlemiller KK, Yang J, McDill B, Kohlhase J, Rauchman M. Expression of a truncated Sall1 transcriptional repressor is responsible for Townes-brocks syndrome birth defects. *Hum Mol Genet*. 2003;12:2221-2227. doi:10.1093/hmg/ddg233

## SUPPORTING INFORMATION

Additional supporting information may be found in the online version of the article at the publisher's website.

**How to cite this article:** Pagnamenta AT, Jackson A, Perveen R, et al. Biallelic *TMEM260* variants cause truncus arteriosus, with or without renal defects. *Clinical Genetics*. 2022;101(1):127-133. doi:10.1111/cge.14071

## APPENDIX A

### A.1. | The Genomics England Research Consortium (27th May 2021)

John C. Ambrose<sup>1</sup>; Prabhu Arumugam<sup>1</sup>; Roel Bevers<sup>1</sup>; Marta Bleda<sup>1</sup>; Freya Boardman-Pretty<sup>1,2</sup>; Christopher R. Boustred<sup>1</sup>; Helen Brittain<sup>1</sup>; Mark J. Caulfield<sup>1,2</sup>; Georgia C. Chan<sup>1</sup>; Greg Elgar<sup>1,2</sup>; Tom Fowler<sup>1</sup>; Adam Giess<sup>1</sup>; Angela Hamblin<sup>1</sup>; Shirley Henderson<sup>1,2</sup>; Tim J. P. Hubbard<sup>1</sup>; Rob Jackson<sup>1</sup>; Louise J. Jones<sup>1,2</sup>; Dalia Kasperaviciute<sup>1,2</sup>; Melis Kayikci<sup>1</sup>; Athanasios Kousathanas<sup>1</sup>; Lea Lahnstein<sup>1</sup>; Sarah E. A. Leigh<sup>1</sup>; Ivonne U. S. Leong<sup>1</sup>; Javier F. Lopez<sup>1</sup>; Fiona Maleady-Crowe<sup>1</sup>; Meriel McEntagart<sup>1</sup>; Federico Minnici<sup>1</sup>; Loukas Moutsianas<sup>1,2</sup>; Michael Mueller<sup>1,2</sup>; Nirupa Murugaesu<sup>1</sup>; Anna C. Need<sup>1,2</sup>; Peter O'Donovan<sup>1</sup>; Chris A. Odhams<sup>1</sup>; Christine Patch<sup>1,2</sup>; Mariana Buongiorno Pereira<sup>1</sup>; Daniel Perez-Gil<sup>1</sup>; John Pullinger<sup>1</sup>; Tahrima Rahim<sup>1</sup>; Augusto Rendon<sup>1</sup>; Tim Rogers<sup>1</sup>; Kevin Savage<sup>1</sup>; Kushmita Sawant<sup>1</sup>; Richard H. Scott<sup>1</sup>; Afshan Siddiq<sup>1</sup>; Alexander Sieghart<sup>1</sup>; Samuel C. Smith<sup>1</sup>; Alona Sosinsky<sup>1,2</sup>; Alexander Stuckey<sup>1</sup>; Mélanie Tanguy<sup>1</sup>; Ana Lisa Taylor Tavares<sup>1</sup>; Ellen R. A. Thomas<sup>1,2</sup>; Simon R. Thompson<sup>1</sup>; Arianna Tucci<sup>1,2</sup>; Matthew J. Welland<sup>1</sup>; Eleanor Williams<sup>1</sup>; Katarzyna Witkowska<sup>1,2</sup>; Suzanne M. Wood<sup>1,2</sup>.

Acknowledgements for the GERC are listed in the supporting information.

<sup>1</sup>Genomics England, London, UK

<sup>2</sup>William Harvey Research Institute, Queen Mary University of London, London, EC1M 6BQ, UK