

## **Appendix 1**

## Skeletal Report

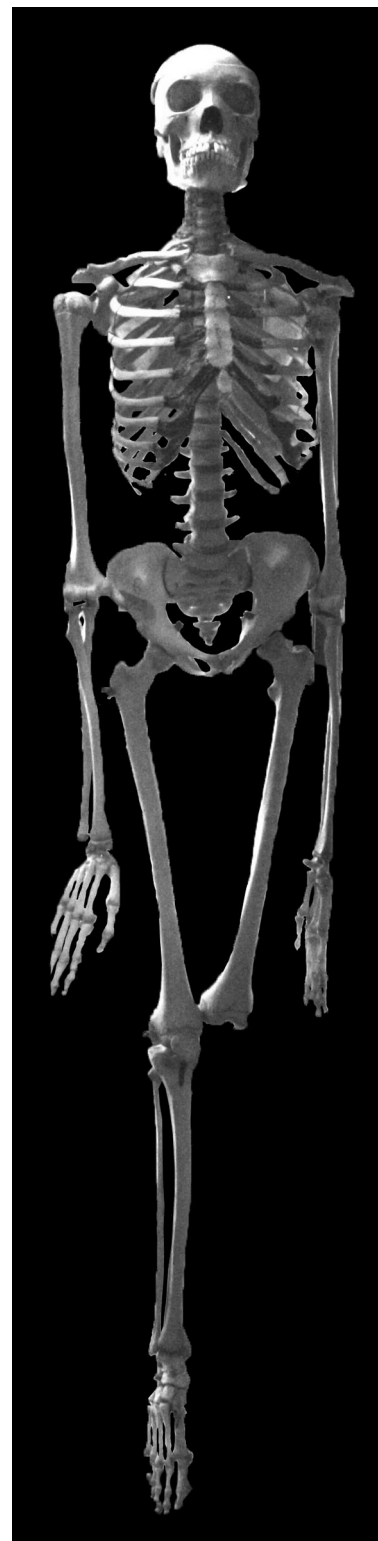### **Skeleton of a Sub-Saharan African Individual who was castrated**

Curated at the Musée Testut Latarjet d'Anatomie de Lyon,  
University of Lyon, France

Date of Examination: April 2010

The Musée Testut Latarjet d'Anatomie de Lyon holds in their collection the skeleton of an individual brought to Lyon, France, by Professor Louis C. É. Lortet in 1896. This individual was brought to the museum as an example of the effects of castration on the human skeleton. Believed to be from the Shillouk region of modern-day Sudan (between Khartoum and Bahr-el-Gagal) and between the ages of 24 and 25 years at death, this individual had been a servant in one of the households of Cairo and had died of unknown causes (they were not discussed in Lortet's article).<sup>1</sup> After Dr. Rollet examined the skeleton in the forensic medical laboratory at the University of Lyon, it was donated to the Anatomical Museum, where it has since remained. The left lower leg of the skeleton, including the tibia, fibula, tarsals, metatarsals, and phalanges was removed by a former curator for study and never returned. Permission was obtained from the museum to perform a macroscopic examination of the skeleton and record osteometric measurements.

The skeleton is wired and glued into anatomical articulation and hangs upright in a case in the museum. When viewing the skeleton in a vertical position, it is possible to see a disproportion in the skeleton similar to the proportional nonconformities in living castrates observed by Pittard and Wagenseil.<sup>2</sup> The hands hang by the knees, and the lower limbs are

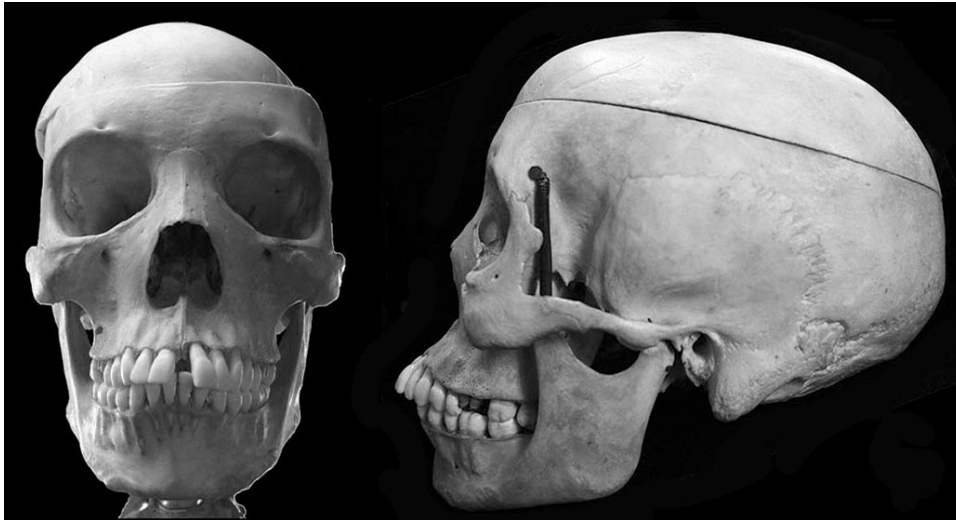

**Figure 1: The Lyon castrate hanging in the museum case, showing the disproportion visible in the skeleton. Photograph by author.**

<sup>1</sup> (Lortet, 1896)

<sup>2</sup> (Pittard, 1934; Wagenseil, 1933, 1927)

much longer than the torso. The pelvis appears small and oddly shaped, and the large, robust mandible dominates the face (**Figure 1**). However, once the skeleton is laid out horizontally for examination, most of the visual skeletal disproportion disappears, except in the hands and feet.

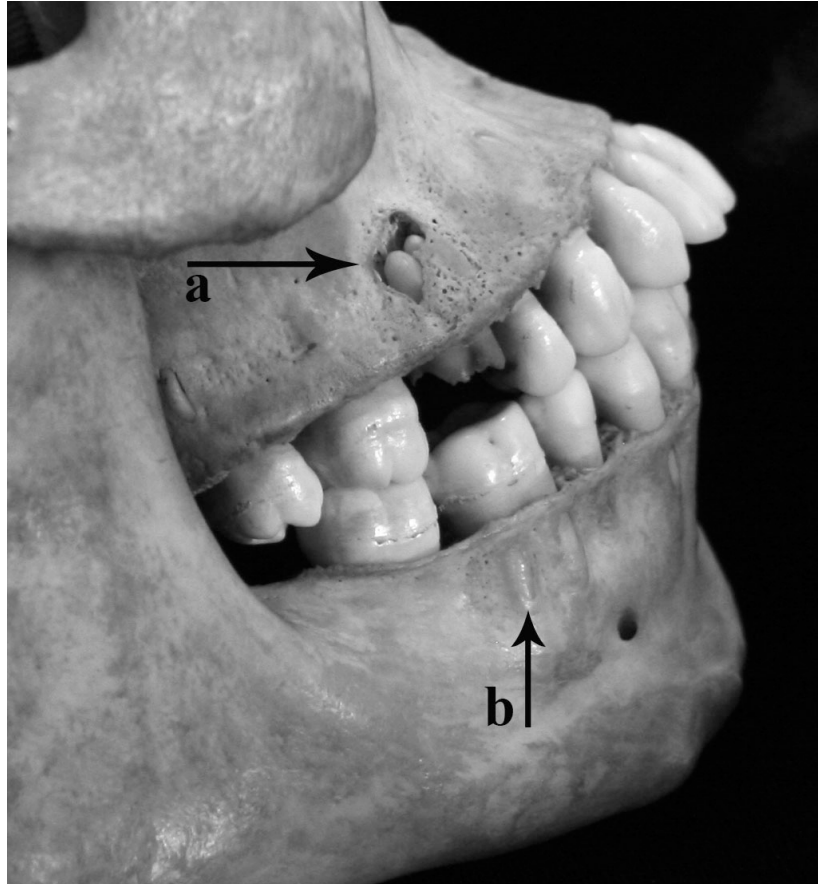


**Figure 2:** Detailed anterior and left lateral views of the skull of the Lyon castrate. Photo by author.

The mandible is heavy and square, with little build-up of the mental eminence, a broad, short ramus, and a shallow mandibular notch (**Figure 2**). The maxilla is strongly prognathic, with a very obvious fusion line between the two maxillary bones, and the zygomas and the zygomatic arches are delicate and do not extend past the external auditory meatus. The mastoid processes are short and anteriorly angled. There is no development of the superciliary ridges, the supraorbital margins are somewhat sharp, the orbits are trapezoidal in shape, and there is no evidence of the nuchal crest or the external occipital protuberances, giving the skull a very feminine appearance.

The adult dentition is erupted, and the maxillary third molars are present, but the mandibular third molars are absent. As the alveolar bone is smooth and shows no signs of remodelling or indications that the third molars are about to erupt, this individual may not have possessed these teeth. There is slight calculus growth limited to the molars and lines of enamel hypoplasia are present on several teeth, most notably the upper second molars, approximately 1-2 mm from the dentine-enamel junction. It is possible that the enamel

hypoplasia on the molars relates to the timing of the castration of the individual.<sup>3</sup> The alveolar bone is very thin and has been resorbed along its superior and anterior surfaces, likely due to receding gums, exposing the roots of several teeth (**Figure 3**).



**Figure 3: Dentition of the Lyon castrate, displaying the abscess caused by the incomplete removal of the right upper first molar (a) and the resorption of the alveolar bone (b). Photo by author.**

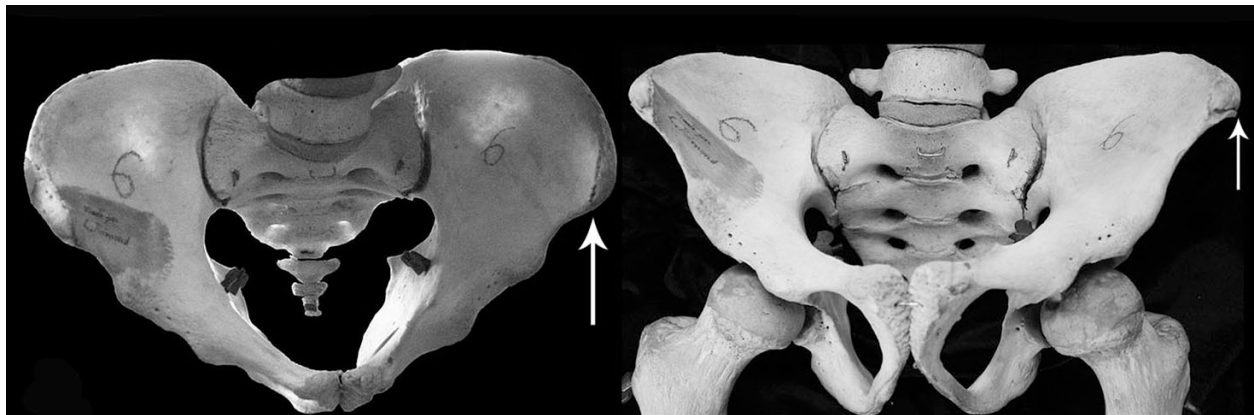Both upper first molars have been sheared bilaterally at the dentine-enamel junction, possibly by a singular traumatic event, which resulted in the death of the roots, leaving them jagged and dead. On the right upper first molar, this appears to have resulted in an infection that created an abscess in the anterior surface of the maxilla. As there is little evidence of wear on the root surface, it is more likely that this damage was due to a singular traumatic event rather than slow, activity-related wear. There is some remodeling around the rim of the abscess, indicating that the abscess was only partially healed at time of death (**Figure 3**),

---

<sup>3</sup> (Ritzman et al., 2008)

which, coupled with the jagged edge of the roots, indicates that the teeth were damaged shortly before death, but not perimortem. The cause of the tooth removal is unclear, but as it is bilateral, it was likely either deliberate or a result of repeated activity, such as the duties he performed in the household for which he worked. It most likely is not linked to initiation rites having to do with his childhood kin group, as the roots are fully formed, which happens in modern populations around age ten, by which point he most likely was already castrated and employed in Cairo.

The long bones of the Lyon castrate are thin, long, and very gracile. This is most prominent in the hands and feet, which display the excess elongation of the extremities (**Figure 1**). All of the appendicular skeleton and most of the axial skeleton still possess open epiphyses. Few to no muscle attachment sites are visible, giving the impression of an individual who did not perform heavy labour. Most of the skeleton displayed evidence of osteoporosis, including high porosity on the vertebral bodies and thinning of the iliac fossae.

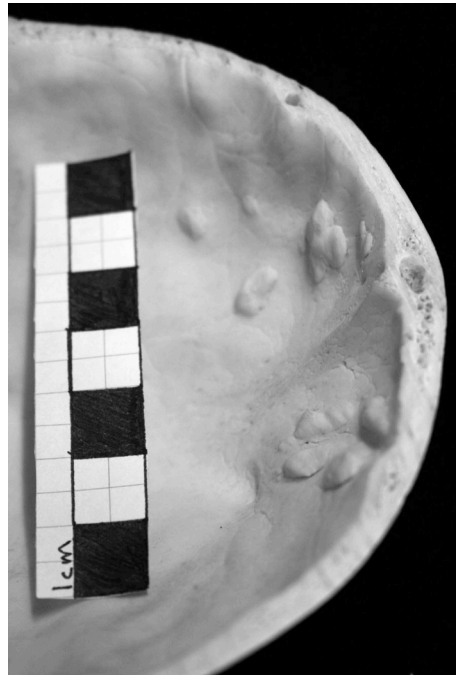


**Figure 4:** Detailed anterior and superior views of the pelvis of the Lyon castrate, displaying the thinning of the iliac fossae and the shape of the subpubic angle and sciatic notches, with arrows marking the open epiphyses. Photo by author.

The Lyon castrate's true pelvis (the area of the pelvis containing the pelvic inlet and outlet and bounded by the ilium below the iliopectineal line, the pubis, the pubic rami, the ischium, the sacrum, and the coccyx) displays a mixture of masculine traits (small but upright, with a narrow, "V"-shaped subpubic angle and hooked sciatic notches) and feminine traits (wide and "D"-shaped obturator foramina, a thin ischiopubic ramus, and a shallow, less curved sacrum) (**Figure 4**). The ilia flare laterally and posteriorly at a very obtuse angle, forming a very wide but shallow false pelvis. The acetabulae are very shallow

and anterior and the pelvic outlet is narrow anterior-posteriorly, creating a triangular pelvic inlet. From the superior view of the pelvis, the ilia and true pelvis seem to form a “heart” shape. Epiphyses are either fusing or completely missing along the iliac crest and the ischium. The delay in fusion of the iliac crest could be causing the outward splay of the ilia.

The Lyon castrate shows signs of *Hyperostosis Frontalis Interna* (HFI) on the internal table of his frontal bone (**Figure 5**). As he died in his early twenties, he would not have had long to develop the condition, but he appears to be between the first two of Hershkovitz’s four developmental stages of HFI.<sup>4</sup> This stage is seen in modern women in their thirties.<sup>5</sup>



**Figure 5: The internal table of the frontal bone of the Lyon castrate, showing early-stage *Hyperostosis Frontalis Interna*. Photo by author.**

Subsequent to the examination of the Lyon castrate, Belcastro and colleagues published work on the remains of Farinelli.<sup>6</sup> While Farinelli’s remains were fragmentary, enough of a portion of his frontal bone had survived to suggest that he also had been

---

<sup>4</sup> (Hershkovitz et al., 1999)

<sup>5</sup> (May et al., 2011)

<sup>6</sup> (Belcastro et al., 2011)

affected by HFI.<sup>7</sup> Farinelli possessed an advanced case of HFI, most likely due to a combination of his advanced age at death<sup>8</sup> and his extended lack of exposure to androgenic steroids, which has been proven to encourage development of the condition (**Figure 6**).<sup>9</sup> The presence of HFI in both the Lyon castrate and Farinelli may mean that this condition can be used as an indicator of castrate status.



**Figure 6:** Frontal bone from Farinelli, displaying the advanced state of *Hyperostosis Frontalis Interna* (from Belcastro et al., 2011).

Table of Bone Measurements

Element	Length		Proximal Breadth		Distal Breadth	
	L	R	L	R	L	R
Clavicle	153.0	150.0				
Humerus	380.0	385.0	42.2	43.5	61.2	60.1
Radius	305.0	308.0	22.8	22.3	25.4	27.9
Ulna	329.0	330.0	24.3	23.0	13.5	13.3
MC1	55.3	57.3				
MC2	76.7	81.5				
MC3	77.7	78.8				
MC4	65.4	64.9				
MC5	58.8	61.0				
Femur	530.0	535.0	44.8	44.2	80.5	78.6
Tibia		470.0		73.0		45.8
Fibula		440.0		23.3		23.8
MT1		71.0				
MT2		88.4				
MT3		84.6				
MT4		82.0				
MT5		81.2				

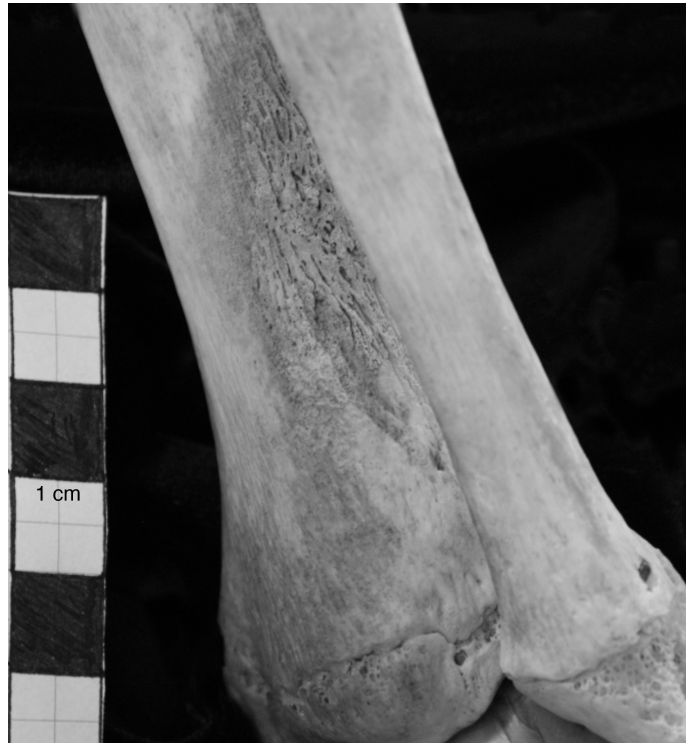**Table 1:** Table of bone measurements (in mm) of the Lyon castrate.

<sup>7</sup> As discussed in Chapter Five.

<sup>8</sup> (Belcastro et al., 2011)

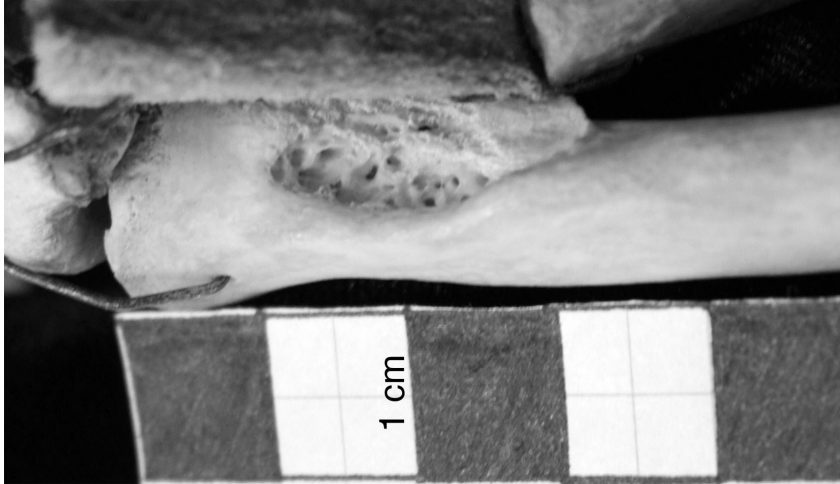<sup>9</sup> (May et al., 2010)

The length of the articulated skeleton was measured at 198 cm. The articulation of the skeleton made taking measurements challenging, but a number of long bone lengths and breadths were obtained, as shown in **Table 1**. The castrate had the following non-metric traits: bilateral supraorbital foramina, lambdoid ossicles, and a unilateral perforated septal aperture in the left humerus.



**Figure 7: Lesion and bone growth on the lateral aspect of the right tibia.**

No indication of the cause of death was visible on the skeleton. However, there is a large lesion filled with bony outgrowth 4.38 cm long inferior-superiorly by approximately 1.88 cm wide medial-laterally on the right tibia directly superior to the distal tibial articulation with the talar bones (**Figure 7**) and periosteal new bone formation on the entire lateral surface of the tibia and part of the medial surface of the fibula, which indicates a non-specific infection perimortem. In addition, a possible avulsion fracture (**Figure 8**) is located on the anterior inferior aspect of the medial end of the left clavicle, 2.0 cm long medial-laterally, at least 0.9 cm wide anterior-posteriorly, and 0.4 cm deep. The rounded edges of the lesion indicate that healing was occurring at the time of death.



**Figure 8: Possible avulsion fracture in left clavicle.**

**Skeletal Report**  
**Nekht-Ankh**  
**Museum No. 21470**

Curated at the Manchester Museum, Manchester, UK  
Date of Examination: August 2012

In 1907, Flinders Petrie offered a pair of mummies from the 12<sup>th</sup> Dynasty (1991-1783 B.C., part of the Middle Kingdom (2030-1640 B.C.)) in Rifeh, Egypt to the Manchester Museum. The collection consisted of two male mummies, two body (anthropoid) coffins, two sarcophagi, two boat models with sailors, a canopic chest with contents, and five statuettes.<sup>1</sup> He offered to allot the collection to the Manchester Museum for the contribution of £500 to his next field season. The mummies were unwrapped by Dr. Margaret Murray at Manchester University in 1907, and a manuscript about the scientific study of the tomb group was published in 1910,<sup>2</sup> and included a description of the two mummies as they appeared after their unwrapping. The physician who oversaw the anatomical investigation of the mummies felt that the skeleton of one of the brothers, Nekht-Ankh, displayed eunuchoid characteristics including slender, delicate bones and faint muscle attachment sites.<sup>3</sup> No subsequent study of the mummies has disputed this claim.<sup>4</sup>

When Nekht-Ankh was unwrapped in the early 1900s, it was discovered that the body had mostly fallen to pieces, but that the bones were intact and in roughly the correct position within the wrappings.<sup>5</sup> At the unwrapping, the skin and hair were preserved on the face and skull, but have since mostly either fallen off or been removed. The mummy is now mostly skeletonized, though some parts of the skeleton (especially the hands and feet) retain flesh. This is apparently common in Middle Kingdom mummies, as the process of mummification was very diverse at this time, often without evisceration and complete desiccation of the body, leading to many skeletonized mummies.<sup>6</sup> In addition, at the unwrapping, the remains were described as “quite moist, and many of the bandages were as wet as though they had been dipped in water, owing to deliquescence of the salt in damp

---

<sup>1</sup> (Murray, 1910)

<sup>2</sup> (Murray, 1910)

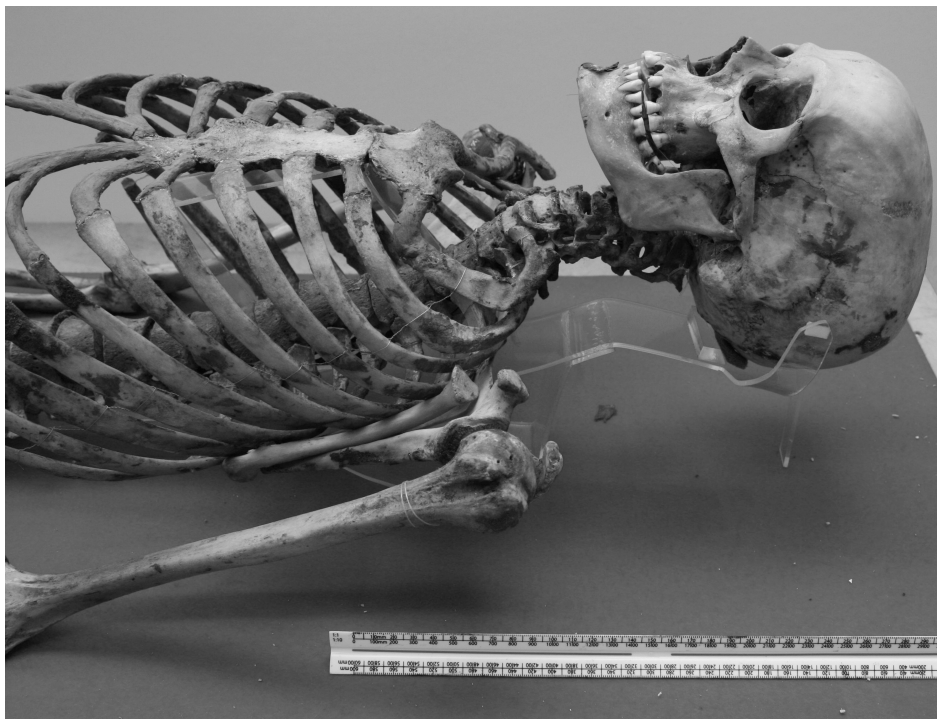<sup>3</sup> (Cameron, 1910)

<sup>4</sup> (David, 1979, 2007)

<sup>5</sup> (Murray, 1910)

<sup>6</sup> (Aufderheide, 2003)

air.”<sup>7</sup> This added moisture and the potentially rough travel between Egypt and Manchester might have contributed to the mummy’s decay. The flesh which remains is mostly found on the right side of the mummy, possibly because his body coffin was placed in his sarcophagus on its left side to allow the spirit of the deceased to “look out” through the eyes painted on the outside of the sarcophagus, a common practice in Middle Kingdom Egypt.<sup>8</sup> The skin, hair, flesh, and other soft tissues (including the laryngeal cartilages and the stomach and intestines from the canopic jars) that have detached from the skeleton are stored in the museum and are available for study.



**Figure 1: Nekht-Ankh reassembled anatomically on a frame and wooden backboard. Photo by author; scale in cm.**

Permission was gained to examine the mummy of Nekht-Ankh in August 2012 for signs of castration while the Two Brothers’ mummies were removed from display during the reorganisation and creation of the Ancient Worlds galleries at the Manchester Museum. This examination of Nekht-Ankh was performed in order to assess the likelihood of his being a castrate. Nekht-Ankh’s skeleton has been reassembled in anatomical position and mounted in a reclining position on a frame and backboard (**Figure 1**). This provided some logistical

---

<sup>7</sup> (Murray, 1910: 31)

<sup>8</sup> (Cockburn et al., 1998; Richards, 2005)

and methodological challenges in examining the skeleton that made it impossible to take certain measurements and to make certain age and sex assessments. It precluded the ability to photograph the superior view of the pelvic girdle. The observation of the interior of the skull was not possible because of the size of the foramen magnum, which restricted access by the tools available. Thus it was not possible to assess the presence of HFI. Due to the delicate nature of the mummy, it was not possible to take it to the Manchester University Hospital for a CT scan or radiographs.

Cameron, the attending physician at the unwrapping, originally assessed Nekht-Ankh's age at sixty years by cranial suture closure. While this is a common ageing method, more accurate methods have been devised in the last hundred years.<sup>9</sup> These include tooth eruption and wear (difficult in Egyptian populations given the generally gritty food consumed);<sup>10</sup> epiphyseal fusion (difficult in castrates);<sup>11</sup> and developmental and degenerative changes in the fourth rib, the pubic symphysis, and the auricular surface (all of which were unavailable due to the articulation of the skeleton). All of Nekht-Ankh's teeth had erupted, including the third molars, indicating that he was older than twenty years, and all the teeth were highly worn, with the dentine exposed on most teeth but not worn down to or past the roots, giving a minimum age of forty-five plus years by Brothwell's standard (**Figure 2**).<sup>12</sup> As the ancient Egyptians are known to have additional wear to their teeth due to blown sand entering their food, dental attrition is not as accurate an ageing method for Nekht-Ankh as it would be for other populations. All epiphyses except the junction between the manubrium and the sternal body were fully fused, indicating that he was over thirty when he died. Cameron states that the coronal and sagittal sutures were obliterated on the interior surface of the cranium.<sup>13</sup> The majority of the cranial sutures were fusing but still very visible on the external table of the cranium. It was not possible to assess the state of the sutures on the internal table of the cranium, as the foramen magnum was too small to allow the passage of both a dental mirror and a light to the inside to inspect the interior sufficiently. Nekht-Ankh appears to be a mature adult, but due to the curation of the mummy

---

<sup>9</sup> (Brickley and McKinley, 2004; Buikstra and Ubelaker, 1994)

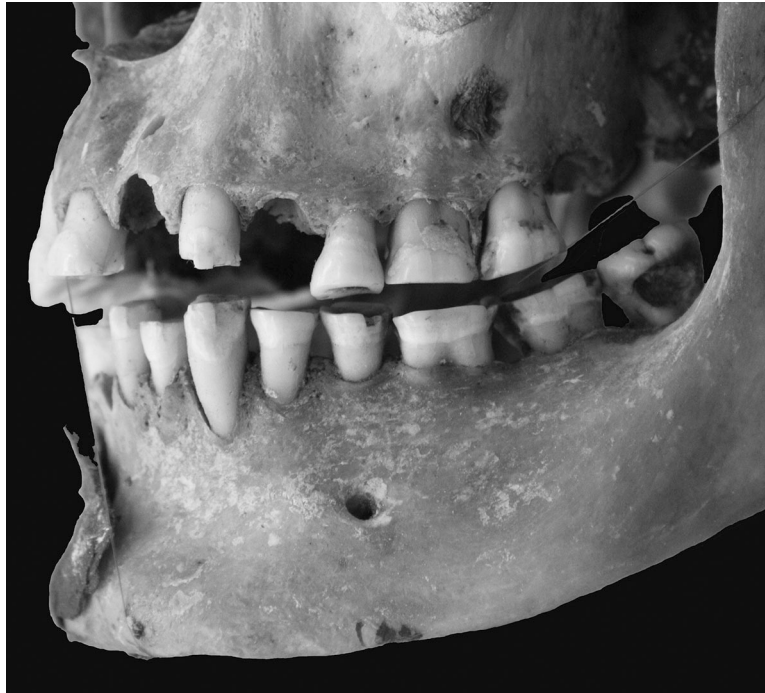<sup>10</sup> (Harris and Ponitz, 1980)

<sup>11</sup> (Eng et al., 2010)

<sup>12</sup> (Brothwell, 1989)

<sup>13</sup> (Cameron, 1910)

(i.e., wired into anatomical position), it is not possible to more accurately define an age category.



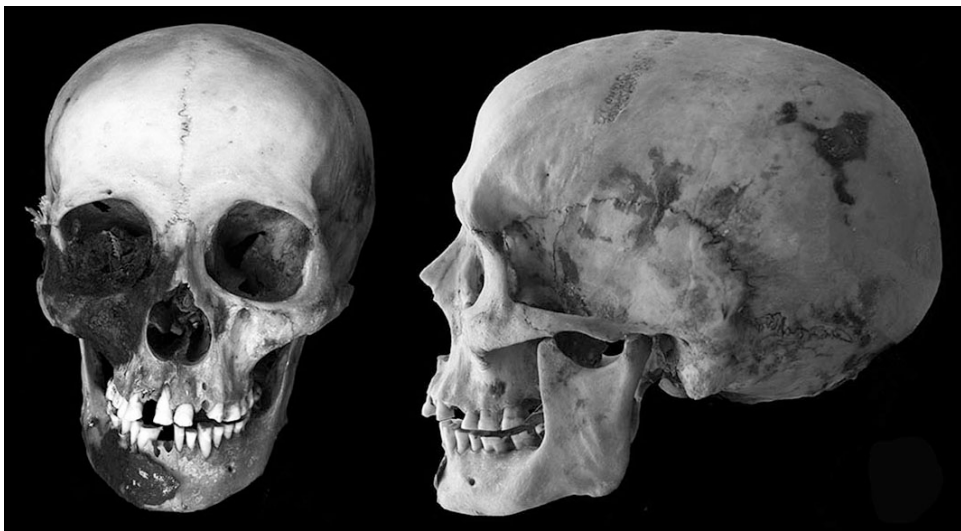**Figure 2: Nekht-Ankh's dentition, displaying his erupted third molars and heavily worn teeth. Photo by author.**

Nekht-Ankh's skull displays a flattening of the area between the foramen magnum and the external occipital protuberance, as in many of the other castrate skulls (**Figure 3**). Whether this is due to castration is brought into question, as there is no visible difference in this area between Nekht-Ankh and Khnum-Nekht.<sup>14</sup> When the mummy was initially unwrapped, the upper right lateral incisor was missing. As is visible in **Figure 2**, more teeth have come loose from the skull since the unwrapping. Nekht Ankh is now missing both upper lateral incisors, the left upper first premolar, both upper third molars, and both right lower incisors (medial and lateral). Both lower third molars have large caries in the buccal surfaces at the dentine-enamel junction, and the lower right first and second molars have caries on their adjoining surfaces. The mandible is small and square, with a prominent mental eminence and an almost ninety degree gonial angle. The body of the mandibular ramus is short and wide, with a shallow notch. The maxilla is slightly prognathic, though

---

<sup>14</sup> (Cameron, 1910)

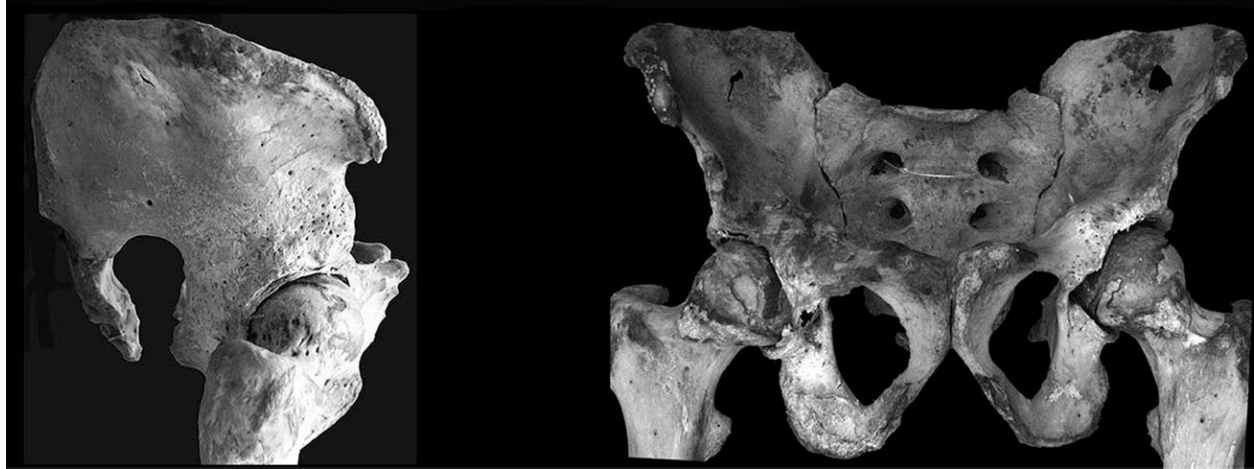
Cameron originally described Nekht-Ankh's face as extremely orthognous (**Figure 3**). The nasal bones are very straight and long, the nasal aperture is wide and tall, and there is no evidence of the suture between the two maxillary bones. The superciliary ridges are fairly well developed, but the supraorbital margin is sharp. The zygomatic arches are very gracile and delicate, and do not extend beyond the external auditory meatus. The mastoid processes are short and anteriorly directed, and there is little to no suggestion of the nuchal crest or external occipital protuberances. All of these cranial features suggest a very gracile, feminine individual.



**Figure 3:** Detailed anterior and left lateral views of the skull of Nekht-Ankh. Photo by author.

The entire skeleton is very gracile, with no evidence for major development of the muscle attachment sites and no particular elongation of the long bones. There is evidence of osteoporosis throughout the skeleton, most obviously in the thinness of the iliac fossae, the bodies of the scapulae, and the porosity of the vertebral bodies. The pelvis is very masculine in appearance, with a narrow subpubic angle and very narrow sciatic notches (**Figure 4**). The ischiopubic rami are neither thick nor thin, and the obturator foramina are “D”-shaped. The acetabulae are wide and shallow, placed semi-anteriorly on the pelvic girdle. The true and false pelvis are both very vertical and narrow, with very little splay of the ilia. The sacrum is not particularly curved, leaving a fairly broad pelvic outlet. Overall, Nekht-Ankh's appearance is very gracile and slightly feminine, but the majority of his secondary sex

markers appear masculine. It is possible that he is a castrate, but likely that he is a postpubertal castrate rather than prepubertal.



**Figure 4: Detailed anterior and right lateral views of the pelvis of Nekht-Ankh, displaying the shape of the subpubic angle and sciatic notch. Photo by author.**

As the skeleton was very tightly articulated and tissue remained on the proximal and distal extremities of the bones of the right side of the skeleton, it was not possible to take many measurements. Long bone lengths and breadths are summarized in **Table 1**.

Table of Nekht-Ankh's Long Bone Measurements

Element	Length		Proximal Breadth		Distal Breadth	
	L	R	L	R	L	R
Clavicle	145.3					
Humerus	300.0	310.0			56.4	
Radius	248.0	250.0				
Femur	440.0	440.0			71.5	
Tibia	360.0	360.0	71.3		44.3	

**Table 1: Table of bone measurements (in mm) for Nekht-Ankh.**

Nekht- Ankh possessed the following metric traits: a metopic suture, bilateral supraorbital foramina, lambdoid ossicles, bilateral auditory exostoses, at least a unilateral mental foramen (the right side of the mandible was obscured by tissue), and bilateral truly perforated septal apertures. He had a small amount of periosteal bone formation on the lateral border of the left orbit of the frontal bone, near the frontal-zygomatic suture and on the tubercle of the left zygomatic bone. The right upper lateral incisor had been removed

antemortem, as the alveolar socket is resorbed and there is no indication of infection. The reason for the tooth removal is unclear, but may have been related to a problem with the tooth or a cultural practice. There is lamellar bone formation on the lateral and medial anterior surfaces of both tibiae, though the causal factor is unclear as there is no accompanying bone reaction on either fibulae or tarsals and its extent is difficult to judge, as it is partially covered by fragmentary tissues on the bones. There are some “patellar whiskers” on both patellae, though these are also mostly obscured by tissue. There is a small (6 mm by 2 mm) lesion on the superior-posterior surface of the left clavicle, a third of the distance from the lateral end. The scapulae are very thin, with postmortem perforations on the right scapula on the superior fossa between the acromion and coracoid processes and the lower portion of the subscapular fossa, 2 cm superior to the inferior angle of the scapula, midway between the lateral and medial borders. There is porosity on the anterior and lateral bodies of all the thoracic and lumbar vertebrae, partially obscured by tissue. There is some concave curvature to the anterior and lateral surfaces of the lumbar vertebrae, accentuated by osteophytic growth on the vertebral margins. The sacrum is also porous, and both ilia show thinning in the iliac fossa, with a postmortem perforation 2 cm long anterior-posteriorly and 1 cm wide superior-inferiorly through the left iliac fossa 5 cm from the superior border and superior to the sciatic notch and a postmortem perforation in the right iliac fossa 1 cm long anterior-posteriorly and 0.5 cm wide superior-inferiorly 5 cm from the superior border and superior to the sciatic notch.