Development of Tissue and Imaging Biomarkers of Rotator Cuff Tendinopathy



Richard James Murphy

Worcester College

DPhil

Michaelmas Term 2012

Supervisors: A.J.Carr, D.J.Beard

Nuffield Department of Orthopaedics, Rheumatology and Musculoskeletal Sciences

Acknowledgements

Over the last few years I have undertaken a journey that has culminated in this book of words. However, this thesis represents only the tiniest fraction of the events, experiences and relationships that have contributed to the personal evolution through which I have travelled in completing my DPhil. Finishing it feels like a great achievement although, as is human nature, it was the vast number of mistakes, challenges and periods of adversity that provided the most valuable lessons and nurtured my development. These learning experiences, many of which were difficult at the time, could not be taken advantage of without the help of a huge support network of colleagues, friends and family. It is this enormous group of people to whom I owe a great debt of gratitude in getting me to this position.

On the day he offered me this opportunity Prof. Andy Carr made me promise only one thing: that I would finish what I started! Since that day, as my main supervisor, he has been a faultless mentor and friend; his enthusiasm, guidance, support and faith in me provided the confidence and motivation to push myself to take on daunting challenges within my research. I am hugely thankful for everything Andy has done to help me, this will never be forgotten and I look forward to a long future of collaboration and friendship.

I owe great thanks to Prof. David Beard, my second supervisor, and Mr. Johnny Rees, both of whom provided guidance and constructive appraisal of my work throughout and were always available when I needed help. Their eye for detail and understanding of what makes good research were invaluable to me.

Without the extraordinary efforts of Kim Wheway, Bridget Watkins and Karolina Kliskey the logistics associated with completing this work would not have been possible. A massive thank you to Kim and Bridget who worked tirelessly to ensure we met our recruitment targets and offered experience, wisdom and support over cups of tea when I felt things were deviating from the plan; and to Karolina who spent many evenings teaching and supervising the extensive tissue processing required and then tolerating a lift home in my little pink car, I promise not to subject you to that ever again.

On the endless occasions when I asked 'How do I...?', 'Where can I find...?' or 'Please could you...?' there was always a smiling face there, happy to help. Thank you to Ulrike, Jo, Tracey, Barbara, Jenny, Sasha, Angela and to Afsie, my Director of Studies, I will always have a hug for you whenever I return.

My colleagues at NDORMS have become a group of many friends with whom I collaborated, discussed, debated, laughed and drank coffee. To Osnat, Jenni, Ben D, Simon, Cushla, Lottie, Raj, Chethan, Neil, Alex, Geraint, Salma, Raewyn, Phillipa, Matt, Hannah, Cameron, Steve, Tim, Andrew, Ben K, Nick, Paul and Luke, a huge thank you.

And finally, to the glue that holds my whole life together, my families in Sheffield, Oxford and Bristol: Mum, Dad, Nan, Granddad, Alex, Matt, Jade, Sophs, Mary, Bernard, Robbie, Sarah and Leonie. Without your love, encouragement and support I would not be where I am today. Thank You.

Abstract

Rotator cuff tendinopathy accounts for the majority of cases of shoulder pain, however, the aetiology and pathophysiology of the condition is poorly understood and treatment interventions for the condition have been introduced on an empirical basis, guided only by unproven theories of biological and structural changes in and around the affected tissue.

This thesis explores changes in the provision of surgical interventions for rotator cuff tendinopathy, showing a rapid, sustained increase over the last decade. Investigation into the use of ultrasound as a clinical and research tool led to the development of an independent learning method for surgeons using the modality for shoulder imaging and highlighted the technological limitations of contrast enhanced ultrasound in assessing the microvascularity of the supraspinatus tendon.

Development of a novel biopsy method for sampling the supraspinatus tendon permitted collection of tissue samples from several cohorts of individuals with rotator cuff tendinopathy. These studies, for the first time, described tissue changes across the whole spectrum of pathology suggesting the possibility of an early inflammatory phase of the condition followed by tissue senescence and reduced viability as pathology progressed. Paired samples taken before and after treatment identified reduced tissue activity in response to glucocorticoid therapy and a potential healing response from the supraspinatus tendon following surgical repair. Significant deterioration in tissue activity and viability was shown as age increased in a large cohort of individuals, highlighting the major impact of ageing as a factor in the onset and progression of rotator cuff tendinopathy.

The techniques introduced provide standardised, reproducible methods for further evaluation of rotator cuff tendinopathy and the development of novel therapeutic interventions.

Contents

1 Introduction **1**
- 1.1 Shoulder Pain . . . 1
- 1.2 The Rotator Cuff . . . 2
  - 1.2.1 Anatomy and Function . . . 2
  - 1.2.2 The Clinical Problem . . . 3
  - 1.2.3 Imaging . . . 5
  - 1.2.4 Theories of Pathophysiology . . . 5
  - 1.2.5 Tissue Research . . . 6
  - 1.2.6 Treatment . . . 8
- 1.3 Limitations of Existing Research and Implications for Clinical Practice . . . 9
- 1.4 Thesis Scope . . . 10

2 Temporal and Geographical Variation in Rates of Surgical Interventions for Rotator Cuff Tendinopathy **11**
- 2.1 Introduction . . . 11
- 2.2 Methods . . . 13
  - 2.2.1 Statistical methods . . . 14
- 2.3 Results . . . 15
- 2.4 Discussion . . . 20
- 2.5 Strengths and Limitations . . . 22
- 2.6 Significance . . . 23

3 Development of a Novel Learning Method for Orthopaedic Surgeons Performing Shoulder Ultrasound **24**
- 3.1 Introduction . . . 24
- 3.2 Methods . . . 31
- 3.3 Results . . . 35
- 3.4 Discussion . . . 40
- 3.5 Significance . . . 46

4 Contrast Enhanced Ultrasound of the Rotator Cuff 49
4.1 Introduction . . . 49
4.2 Methods . . . 55
4.3 Results . . . 59
4.4 Discussion . . . 62
4.5 Significance . . . 66

5 Development of an Ultrasound Guided Rotator Cuff Tendon Sampling Technique 67
5.1 Introduction . . . 67
5.2 Methodological Development . . . 71
5.3 Application of Biopsy Method . . . 95

6 Immunohistochemical Changes Associated with the Progression of Rotator Cuff Pathology 96
6.1 Introduction . . . 96
6.2 Method . . . 99
6.2.1 Participants and Tissue Sampling . . . 99
6.2.2 Tissue Processing and Staining . . . 102
6.2.3 Microscopy and Image Capture . . . 104
6.2.4 Image Analysis . . . 106
6.3 Results . . . 118
6.4 Discussion . . . 125
6.5 Limitations . . . 128
6.6 Significance . . . 131

7 Short Term Tissue Response to Current Treatments for Rotator Cuff Tendinopathy 133
7.1 Introduction . . . 133
7.2 Methods . . . 136
7.2.1 Tissue Processing, Imaging and Analysis . . . 139
7.3 Results . . . 140
7.4 Discussion . . . 143
7.5 Limitations . . . 148
7.6 Significance . . . 150

8 Age-Related Change in the Supraspinatus Tendon 152
8.1 Introduction . . . 152
8.2 Methods . . . 154
8.2.1 Participants and Tissue Sampling . . . 154
8.2.2 Tissue Processing, Imaging and Analysis . . . 156

8.3 Results . . . 157
8.4 Discussion . . . 159
8.5 Limitations . . . 166
8.6 Significance . . . 167

9 Discussion **168**
9.1 Introduction . . . 168
9.2 Main Findings . . . 170
9.3 Strengths and Limitations . . . 175
9.4 Thesis Scope . . . 178
9.5 Contribution to Existing Knowledge . . . 180
9.6 Implications for Future Research and Clinical Practice . . . 181
9.7 Conclusions . . . 184

References **186**

A OPCS-4 and ICD-10 codes **201**
A.1 Subacromial Decompression Codes . . . 202
A.2 Rotator Cuff Repair Codes . . . 203

B Histopathology Methods **205**
B.1 Tissue Processing . . . 205
B.2 Staining . . . 206
B.2.1 Haematoxilin and Eosin . . . 207
B.2.2 CD34 Antibody - Vascular Endothelium . . . 208
B.2.3 CD45 Antibody - Leucocyte Common Antigen . . . 209
B.2.4 MIB-1 (Ki-67) Antibody . . . 210
B.2.5 Active Caspase-3 Antibody . . . 211
B.2.6 Sirtuin-1 Antibody . . . 212
B.2.7 Envision Kit . . . 213
B.2.8 Finishing and Storage . . . 214

List of Figures

2.1 Rates of Rotator Cuff Repair Surgery between 2000–01 and 2009–10 . . . 16
2.2 Geographical Variation in Subacromial Decompression between 2003–4 and 2009–10 . . . 18
2.3 Geographical Variation in Rotator Cuff Repair between 2008–9 and 2009–10 . . . 19

3.1 Timing of Preoperative Ultrasound Scans in the Radiology Department . . . 44
3.2 Protocol for Ultrasound Training . . . 48

4.1 Pulse Inversion Ultrasound Principle . . . 53
4.2 CEUS Video Images . . . 56
4.3 CEUS Parametric Image . . . 57
4.4 Regions of Interest within CEUS Image . . . 58
4.5 Time-Intensity Curve, Raw Data . . . 61
4.6 Time-Intensity Curve, Smoothed Data . . . 61
4.7 Image Intensity During the Baseline and First Pass Time Periods 62

5.1 Core Biopsy Needle: Open and Closed Positions . . . 73
5.2 Core Biopsy Instruments . . . 75
5.3 Core Biopsy of Sheep Infraspinatus Tendon . . . 76
5.4 Light Micrographs of Subscapularis Tendon Biopsies . . . 79
5.5 Lid for Ultrasound Phantom Mould . . . 82
5.6 Ultrasound Phantom Model . . . 82
5.7 Ultrasound Images of Gelatine Phantom Model . . . 84
5.8 Diagram of Ink Staining on Inclusions . . . 85
5.9 Diagrams and Ultrasound Images of Longitudinal Plane of Supraspinatus Tendon and Path of Biopsy Needle . . . 90

6.1 Image Analysis: Masks of Total and Positively Stained Tissue Area . . . 109

6.2 Image Analysis: Mask of Nuclei within Slide Image 114
6.3 Nucleic Count Validation 115
6.4 Age Distribution within Groups 120
6.5 Symptom Duration within Groups 120
6.6 Light Micrographs of Tissue Staining 122
6.7 Cellularity 123
6.8 Vascularity (CD34 Expression) 123
6.9 Inflammation (CD45 Expression) 124
6.10 Proliferation (MIB-1 Expression) 124
6.11 Apoptosis (Active Caspase-3 Expression) 125

7.1 Diagram of Intraoperative Biopsy Plane for RCR 139
7.2 Pre and Post-Treatment Vascularity (CD34 Expression) 143
7.3 Pre and Post-Treatment Inflammation (CD45 Expression) . . 144
7.4 Pre and Post-Treatment Proliferation (MIB-1 Expression) . . 144
7.5 Pre and Past-Treatment Apoptosis (Active Caspase-3 Expression) 145
7.6 Pre and Post-Treatment Oxford Shoulder Scores 145

8.1 Light Micrograph of SIRT-1 Expression 159
8.2 Cellularity 160
8.3 Vascularity (CD34 Expression) 160
8.4 Proliferation (MIB-1 Expression) 161
8.5 Apoptosis (Active Caspase-3 Expression) 161
8.6 Ageing 162
8.7 Distribution of Pathology by Age Groups 165

List of Tables

3.1 Ultrasound Reporting of Rotator Cuff Integrity 37
3.2 Predictive Values for Ultrasound Identification of Full Thickness Tears 38
3.3 Ultrasound Sizing of Full Thickness Tears 39
3.4 Comparison of Predictive Values with Published Figures . . . 42

5.1 Accuracy of Phantom Biopsy Methods 86

6.1 Spectrum of Pathology Group Breakdown and Demographics . 119

7.1 Treatment Group Breakdown and Demographics 142

8.1 Study Groups (Age) 158

A.1 Codes to identify subacromial decompression between 2000–06 202
A.2 Codes to identify subacromial decompression between 2006–07 202
A.3 Codes to identify subacromial decompression between 2007–09 202
A.4 Codes to identify subacromial decompression between 2009–12 203
A.5 Codes to identify rotator cuff repair between 2000–06 203
A.6 Codes to identify rotator cuff repair between 2006–09 204
A.7 Codes to identify rotator cuff repair between 2009–12 204

Chapter 1

Introduction

1.1 Shoulder Pain

Shoulder complaints have an estimated prevalence of 16–26% in the UK population, with upto 1·5% of adults presenting to their general practitioner each year regarding a first episode of shoulder pain.[1–3] They account for 2·4% of all general practitioner consultations in the UK and are more common in patients over 50 years of age.[3] Problems in the shoulder cause a spectrum of pain and functional disability; patients may have difficulty performing essential activities of daily living and are often forced to take time off work.[2] The prognosis for patients presenting with shoulder pain is variable; while a quarter of patients will have resolution within a month, over 40% will continue to have pain after a year.[4]

The annual financial burden of shoulder pain management in the USA has been estimated to be US $3 billion and shoulder pain accounts for 4·5 million visits to physicians annually in the USA.[5,6]

The aetiology of shoulder pain is diverse and many disorders present with similar symptoms and signs. The main causes of non-traumatic shoulder pain include: glenohumeral and acromioclavicular joint degeneration, rotator cuff tendinopathy and referred pain from the cervical spine.[7] Pathology attributed to the rotator cuff is a major cause of shoulder pain; evidence of rotator cuff tendinopathy has been recorded in up to 85% of new presentations of shoulder pain in general practice.[8] Rotator cuff tendinopathy presents the most prevalent clinical challenge for GPs and orthopaedic surgeons when treating patients with shoulder pathology.

1.2 The Rotator Cuff

1.2.1 Anatomy and Function

The rotator cuff is a musculotendinous structure that acts to stabilise the glenohumeral joint and manipulate the humeral head within the glenoid fossa in order to facilitate the extensive, multidirectional range of motion associated with the shoulder.[9–11]

The rotator cuff comprises four muscles and their tendons: subscapularis, supraspinatus, infraspinatus and teres minor. The muscles originate from the broad surfaces of the scapula and taper into sheet-like tendons as they proceed laterally to insert into the tuberosities of the proximal humerus. The tendons of supraspinatus, infraspinatus and teres minor merge as they approach their common insertion into the greater tuberosity to form a continuous hood of tendon superiorly over the head of the humerus. The sub-

scapularis tendon lies anterior to the glenohumeral joint, discrete from the other tendons of the rotator cuff, inserting into the lesser tuberosity of the humerus. An aperture between the supraspinatus and the subscapularis tendons, known as the rotator interval, permits transmission of the tendon of the long head of biceps as it passes between the greater and lesser tuberosities, enters the glenohumeral joint and attaches to the superior pole of the glenoid fossa.[10,11]

Superior to the rotator cuff, the acromion process of the scapula and coraco-acromial ligament form an arch of bone and fibrous tissue. The region between this arch and the humeral head, the subacromial space, contains the subacromial bursa, which functions to facilitate unrestricted sliding movement of the rotator cuff tendons beneath the inferior surface of the subacromial arch.[12]

These structures form a precisely engineered unit of function, retaining the humeral head securely in the glenoid fossa while powerful, external muscles of the shoulder girdle such as the deltoid, pectoralis major and latissimus dorsi move the arm through their action on the humeral diaphysis.

1.2.2 The Clinical Problem

Disorders of the rotator cuff can present with an array of clinical findings; patients often describe pain over the anterolateral aspect of the shoulder on activity, particularly when elevating the arm above shoulder height, usually of insidious onset.[13] Pain at night, with an inability to lie on the affected shoulder typically follows and occasionally a history of trauma, often mini-

mal, may represent tearing within the tendon thats can lead to chronic pain and reduced strength and function.[14]

Examination findings may reveal atrophy of the rotator cuff muscles over the superior and posterior aspects of the scapula.[15] Passive range of motion generally remains unrestricted, although may be painful at the extremes; active range of motion may be limited due to pain or weakness. Further signs associated with rotator cuff tendinopathy include pain with specific manoeuvres such as the painful arc, Hawkin's and Jobe's 'impingement' tests.[16–18] The presence of a full thickness tear of the rotator cuff may manifest as weakness of shoulder movement in the plane of action of the affected tendon and impair compound movements of the shoulder such as placing the hand behind the head or reaching above shoulder height.

Structural failure of the rotator cuff almost exclusively begins in the supraspinatus tendon with partial thickness tearing of the tendon away from its insertion into the greater tuberosity, often extending to become a full thickness tear.[19,20] The initiation of a full thickness tear may develop from a small defect in the supraspinatus tendon and extend into the adjacent infraspinatus.

Currently, the assessment of rotator cuff tendinopathy in an outpatient setting is primarily clinical, with history and examination of the features described above, although several imaging modalities may be employed to evaluate the bony shoulder and the structural integrity of the tendons.

1.2.3 Imaging

The rotator cuff is a soft tissue structure consisting of muscle and tendon tissue. Imaging modalities such as ultrasound and magnetic resonance imaging (MRI) are most commonly employed in assessment of the rotator cuff, although plain x-rays may also be valuable in identifying calcium deposits within the tendons.[21] X-rays are commonly used in clinical practice to assess the bony structures of the shoulder girdle and evaluate the presence of conditions such as osteoarthritis. In some circumstances, a large defect in the rotator cuff tendons may be indicated by superior translation of the humeral head leading to contact with the acromion.[21] MRI and ultrasound have both been shown to have a high level of accuracy in evaluating the integrity of rotator cuff in terms of identification of full thickness rotator cuff tears.[22] These imaging modalities share comparable sensitivity and specificity for the detection of full thickness rotator cuff tears in the hands of suitably trained clinicians.[23,24] Both MRI and ultrasound offer the opportunity for subjective interpretation of the presence and severity of tendinopathy within the rotator cuff although there are not currently any quantifiable imaging biomarkers of rotator cuff pathology that can be used to determine degree of tendinopathy or prognosis.

1.2.4 Theories of Pathophysiology

The aetiology and progression of rotator cuff tendinopathy are poorly understood. Originally, a theory of 'extrinsic' aetiology was proposed suggesting that damage to the tendons was due to attrition from friction between the

tendon and the underside of the coraco-acromial arch.[25] Progressive change in the shape of the acromion was suggested to occur in response to this activity, with a bony spur forming at its antero-inferior margin.[20] This made physical contact more likely, particularly in overhead positions of the arm and led to a theory of both the subacromial bursa and rotator cuff tendons becoming inflamed and swollen as part of this process.[19]

Subsequent work suggested that 'intrinsic' factors may play a significant part in the onset and development of the pathology with theories proposed to explain the occurrence of the condition including overuse of the shoulder, muscle weakness in the rotator cuff and degenerative tendinopathy.[26–29]

1.2.5 Tissue Research

A substantial array of publications aiming to shed light onto the tissue characterisation of rotator cuff tendinopathy has arisen over recent decades.[30] Despite the diverse laboratory analyses undertaken, evaluating the extracellular matrix and cellular components of the tendon, little consensus has been reached in defining the progression of pathology within the tissue.

A major factor affecting the lack of conclusion from this body of work may be the heterogeneity of methodology applied in tissue selection and harvesting for these studies. Without a method for sampling the supraspinatus tendon safely in patients across the spectrum of rotator cuff pathology, researchers have been forced to use alternative sources of tissue for analysis and extrapolate conclusions from these surrogate samples.

A number of animal models have been trialled aiming to mimic rotator

cuff tendinopathy, although the study of artificially induced tendon pathology in the weight-bearing limb of a quadruped raises significant questions over the validity of translatable results from such work.[31–34]

Extensive investigation has been carried out using cadaveric tissue from humans. The phenotypic information available regarding the clinical condition of tissue donors in these studies is minimal, often providing only age, sex and macroscopic measures of tendon integrity against which to correlate results, thus limiting the conclusions that can be drawn using this sample population.[35–47]

Tissue obtained from patients with rotator cuff tendinopathy has been widely studied, however, the samples obtained have been harvested, almost exclusively, from the resected edge of torn supraspinatus tendons.[41–46,48–70] These samples are from tendons at the terminal stages of rotator cuff tendinopathy, when structural failure has already occurred, offering no insight into the early stages of pathology. In addition, the samples analysed may represent a region of granulomatous tissue that has changed significantly since detachment of the tendon from the bone, bearing little resemblance to the remainder of the supraspinatus tendon.

A further limitation in the existing literature results from the use of unvalidated tissue as a control against which the conclusions of many of the previously mentioned studies have been drawn.[42,48,60–62,68,70] The subscapularis tendon has been sampled as a control tissue in many studies due to the ease of biopsy of this structure during many surgical interventions. This tendon, however, is not subject to the same physiological environment as the supraspinatus tendon and its use as a control tissue, without validation

against samples of the supraspinatus, must be interpreted with reservation.

1.2.6 Treatment

A limited understanding of the pathophysiology of rotator cuff tendinopathy has led to an empirical approach to treatment development, with interventions trialled on the basis of proposed theories of aetiology of disease that remain unproven. Although no clear evidence has been published to support the efficacious application of any intervention, a wide array have been employed to treat rotator cuff tendinopathy including: glucocorticoids, non-steroidal anti-inflammatory drugs, physiotherapy, nerve blocks, biologic therapies, extracorporeal shock wave therapy, laser treatment, electrical stimulation, ice, ultrasound, acupuncture, acromioplasty and surgical repair of torn rotator cuff tendons.[71]

The interventions currently used in secondary care, however, are primarily limited to subacromial injection of glucocorticoids, physiotherapy, subacromial decompression and rotator cuff repair. The evidence to demonstrate the efficacy of these treatments or to explain their mode of action at a tissue level is extremely limited. A poor understanding of the condition may be contributing to this process as, without the ability to reliably identify individuals who may benefit from a particular procedure, a great deal of heterogeneity exists in experimental cohorts and may lead to misleading or inconclusive results following treatment. Development of an understanding of the pathophysiology of rotator cuff tendinopathy would not only allow clinicians to direct treatments to individuals more appropriately, but would

provide parameters that could be used to assess the efficacy of the treatments administered.

1.3 Limitations of Existing Research and Implications for Clinical Practice

Although a large body of research into rotator cuff tendinopathy exists, a conclusive explanation of why the condition occurs, how it develops and what interventions may be utilised to delay or reverse its progression has not been achieved.[30] The primary reasons for the failure of previous literature to draw consistent and valid conclusions are the methodological limitations of tissue sources used for analysis. In order to improve the understanding of rotator cuff tendinopathy, investigation of well phenotyped tissue representing the full spectrum of pathology must be undertaken.

The absence of a detailed insight into the biology of the rotator cuff tendons limits the potential for the development and evaluation of targeted treatments. Currently, a wide array of interventions are used in the treatment of the condition, without an understanding of their biological effects on the rotator cuff tendons or good quality evidence to support their efficacy.[71] Advancement in the field of treatment for rotator cuff tendinopathy is dependent upon improving our understanding of its pathophysiology.

Tissue analysis of well selected, consistently obtained samples from rotator cuff tendons across the whole spectrum of pathology and investigation of the tissue effects of treatment interventions would permit the development of

biomarkers of pathology. Ultimately, correlation of a tissue biomarker with a less invasive imaging biomarker would provide a tool for assessment of the rotator cuff that could be employed clinically, and in a research setting, to improve the accuracy of biological diagnosis, potentially provide information regarding prognosis and enhance the selection and evaluation of treatments employed.

1.4 Thesis Scope

This thesis investigates the current provision of surgical treatment for rotator cuff tendinopathy and explores methods for imaging and tissue analysis that can be used to improve the validity and translatability of research into its pathophysiology and treatment. A number of questions are investigated:

1. How prevalent is surgical treatment for rotator cuff tendinopathy and has this changed over the last decade?

2. What can ultrasound offer as an imaging modality in the development of tissue and imaging biomarkers of rotator cuff tendinopathy?

3. Can a minimally invasive biopsy method be developed to provide samples of the supraspinatus tendon in a safe, repeatable and topographically consistent manner for laboratory analysis?

4. What cellular tissue changes are seen in the supraspinatus tendon across the spectrum of rotator cuff tendinopathy, in response to current treatments and in association with advancing age?

Chapter 2

Temporal and Geographical Variation in Rates of Surgical Interventions for Rotator Cuff Tendinopathy

2.1 Introduction

Musculoskeletal pain is a major presenting complaint in general practice with a large proportion of cases attributable to pain in and around the shoulder.[1] Shoulder pain is most prevalent in patients over 50 years of age and accounts for 2·4% of primary care consultations in the UK.[3] Over two thirds of presenting cases of shoulder pain are due, at least in part, to rotator cuff tendinopathy.[8]

Clinical progression of rotator cuff tendinopathy often begins with char-

acteristic pain on activity when the structural integrity of the rotator cuff usually remains intact before progressing, in some cases, to a state of worsening pain, weakness and loss of function associated with tearing of the rotator cuff tendons away from the greater tuberosity.[13,14]

The principle treatments for this condition extend from non-steroidal anti-inflammatory drugs, through a trial of physiotherapy, subacromial injection of glucocorticoids to surgical interventions such as arthroscopic subacromial decompression (SAD) and rotator cuff repair (RCR).[7,72,73] Evidence to support the use of any of these interventions is of low quality and remains unclear as to the effectiveness of each treatment versus placebo or another treatment option.[71,74,75]

The financial burden of shoulder pain is significant; in the USA, an estimate of the annual impact of the condition on the economy is around US $3 billion.[5] Surgical interventions represent the most expensive treatment options available, although evidence to demonstrate their clinical efficacy is lacking.[71,74,75] The cost effectiveness of surgical intervention for rotator cuff tendinopathy was questioned by one group who showed no benefit of surgery with physiotherapy compared with physiotherapy alone; the addition of surgery to the treatment protocol significantly increased the overall cost of each treatment episode.[76]

Despite the lack of evidence in support of the clinical or financial benefits of rotator cuff surgery around 300,000 surgical repairs of the rotator cuff tendons are carried out each year in the USA.[5]

This study investigates temporal trends in the delivery of SAD and RCR surgery in England. We also explore geographical variation in provision of

SAD to determine if any changes in rates of surgery occur uniformly across the population.

2.2 Methods

Data were obtained from the Hospital Episode Statistics (HES) database, which holds information on patients admitted to NHS hospitals in England, either as day cases or ordinary admissions. Each record in the database relates to one 'finished consultant episode'. This is the period of time an individual spends under the care of one NHS consultant. Private procedures are excluded from HES as there is no requirement for private hospitals to provide routine data.

The information held in the HES database includes the age and sex of the patient, area of usual residence, reason for admission (diagnosis) to hospital, and procedure undertaken. Data for this analysis were derived from the database extract held at the South West Public Health Observatory (SWPHO). Further information on HES is available from the HES online website at http://www.hesonline.org.uk.

Anonymised records for patients undergoing the following elective operations between the 1st April 2000 and 31st March 2010 were extracted from the HES database:

1. subacromial decompression (SAD) only
2. rotator cuff repair (RCR) with SAD
3. RCR only

Episodes involving these procedures were identified using a combination of Office of Population Censuses and Surveys Classification of surgical operations and procedures version 4 (OPCS-4) codes in the procedure fields (that contain information about a patient's operations) and the World Health Organisation International Statistical Classification of Disease and Related Health Problems (ICD-10) codes from the diagnostic fields (that contain information about a patient's illness or condition) (see appendix A for the full list of OPCS-4 and ICD-10 codes used).[77,78]

2.2.1 Statistical methods

Stata® version 12·0 (Stata, College Station, Texas, USA) was used for all statistical analyses. To describe trends in rates of admission over time between 2002–3 to 2009–10 for each of the three procedures we used direct standardisation using the 2002 England age-sex population to calculate the age-sex standardised admission rates (SAR) and confidence intervals (CI). For the denominator, population counts by age, sex and year were obtained from the Office for National Statistics population estimates for England. The Association of Public Health Observatories (APHO) tool was used for calculating the standardised rates to conform to the APHO standard.

To explore geographical variation in the utilisation of these procedures we identified the Primary Care Trust (PCT) of residence of each patient. All PCT data are configured to the 2010 PCT boundaries so they are consistent over time. For the calculation of rates, the numerator is the number of procedures within each age, sex, PCT group and year of admission. For

the denominator, PCT population counts were obtained from the National Centre for Health Outcomes Development and configured to 2010 boundaries. Rates where the total number of events is <6 have been suppressed. The geographic information systems software MapInfo Professional® version 11 (Pitney Bowes Inc., Stamford, Connecticut, USA) was used to display maps of age-sex standardised procedure rates within each PCT.

2.3 Results

In the ten years between 1st April 2000 and 31st March 2010 a total of 101,254 patients received SAD in England (group 1). Males accounted for 49·5% (n=50,077) of procedures; females 50·5% (n=51,177). The median age of admission was 55 years (range 16–92 years) for males, and 55 years (range 11–92 years) for females. The number of procedures rose by 746·4%, from 2,523 patients in 2000–1 [SAR 5·2 per 100,000 (95% CI 5·0 to 5·4)] to 21,355 in 2009–10 [SAR 40·2 per 100,000 (95% CI 39·7 to 40·8)]. Trends in admission rates are shown in figure 2.1, where it can be seen that there has been a dramatic increase in SAD. The numbers of patients receiving SAD with RCR (group 2) remained low up until the year 2004–5 after which they increased substantially from a rate of 1·4 per 100,000 (95% CI 1·3 to 1·5)] up to 13·7 per 100,000 (95% CI 13·4 to 14·0) in 2009–10.

Operations for RCR only (group 3) peaked in 2008–9 at 2,468 operations [4·7 per 100,000 (95% CI 4·5 to 4·8)], then declined considerably in 2009–10 to 1,399 operations [2·6 per 100,000 (95% CI 2·5 to 2·7)]. To see if this trend continued, we obtained additional HES data for subsequent years which

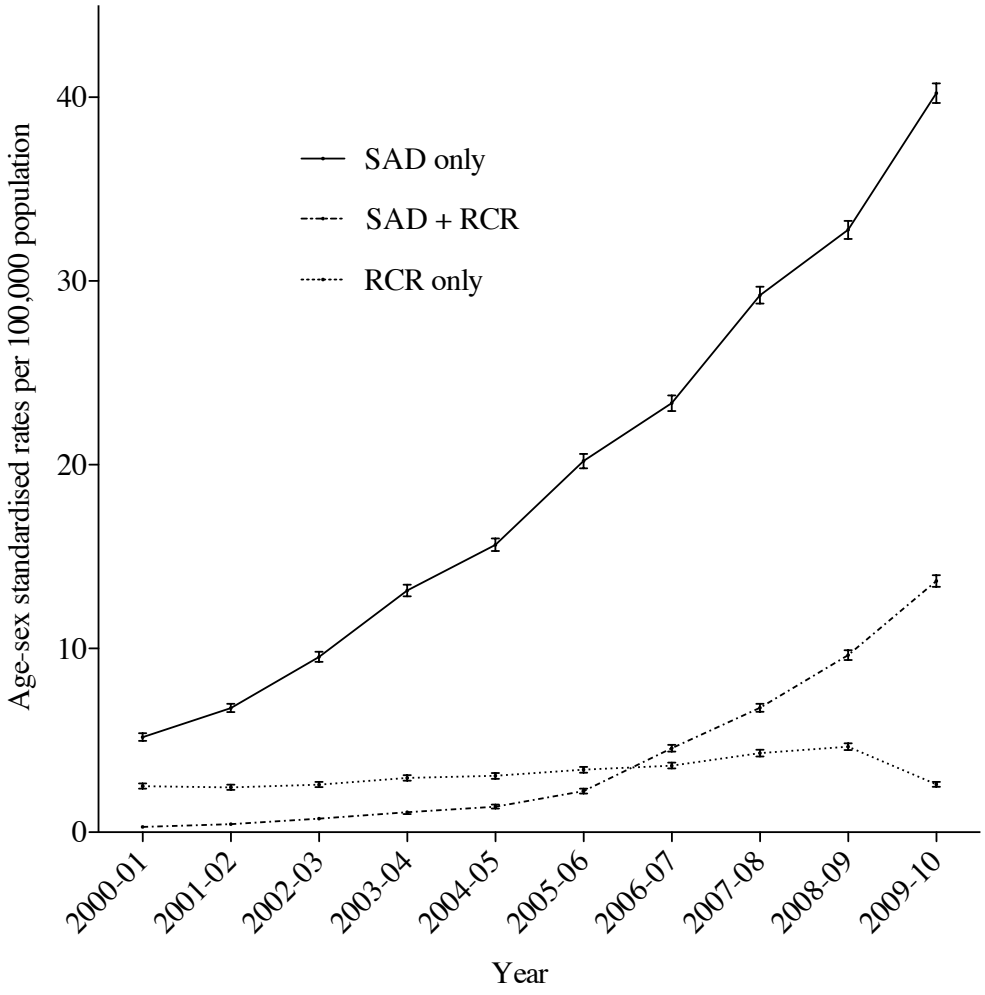

Figure 2.1: Age and gender standardised rates for rotator cuff surgery between 2000–01 and 2009–10.

showed that rates of RCR continued to fall in 2010–11 to 1,308 procedures [2·4 per 100,000 (95% CI 2·3 to 2·5)] and in 2011–12 to 1,110 procedures [2·0 per 100,000 (95% CI 1·9 to 2·1)].

Standardised rates of SAD only (group 1) varied geographically according to the PCT of residence (see figure 2.2). In 2002–03, only seven PCTs were performing a high number of these procedures (defined as an age-sex standardised rate of over 25 per 100,000 population). The top five PCTs with the highest rates of use of this procedure in 2002–03 were Warrington, Kingston, Nottingham City, Berkshire West and Telford and Wrekin. Increasing utilisation of this procedure spread geographically across the country from these PCT areas such that, by 2009–10, 83·6% (127/152) of PCTs in England were performing 25 or more procedures per 100,000 population.

Figure 2.3 displays rates of RCR only (group 3) by PCT of residence in the year 2008–9 when rates were at their highest, versus 2009–10 when rates declined. The locations of centres in the UKUFF trial have been displayed on the maps where it can be seen that UKUFF centres are spread across the country. The figures demonstrate substantial geographical variation in the utilisation of RCR surgery. Whilst the overall rate in England was 4·7 per 100,000 in year 2008–9, across PCT areas this ranged from no procedures (or data suppressed due to fewer than six events), up to rates as high as 17·7 per 100,000. The decline in rates of RCR occurred uniformly across all areas of the country in 2009–10. Rates appeared to decline in areas clustered around UKUFF sites, particularly sites with higher rates of surgery in 2008–9.

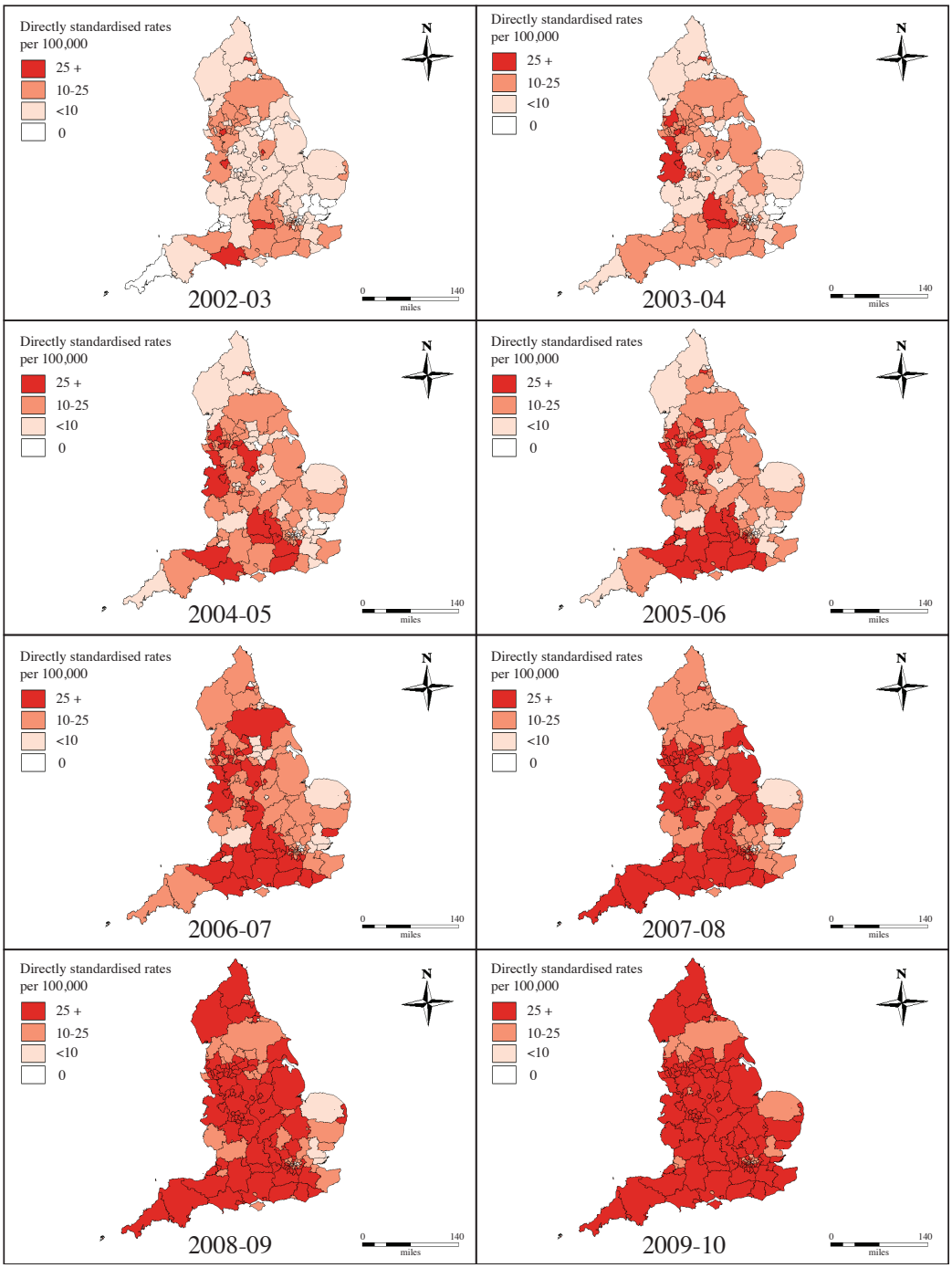

Figure 2.2: Geographical variation in SAD. Age and gender standardised rates of SAD only, by English PCT between 2002–3 and 2009–10.

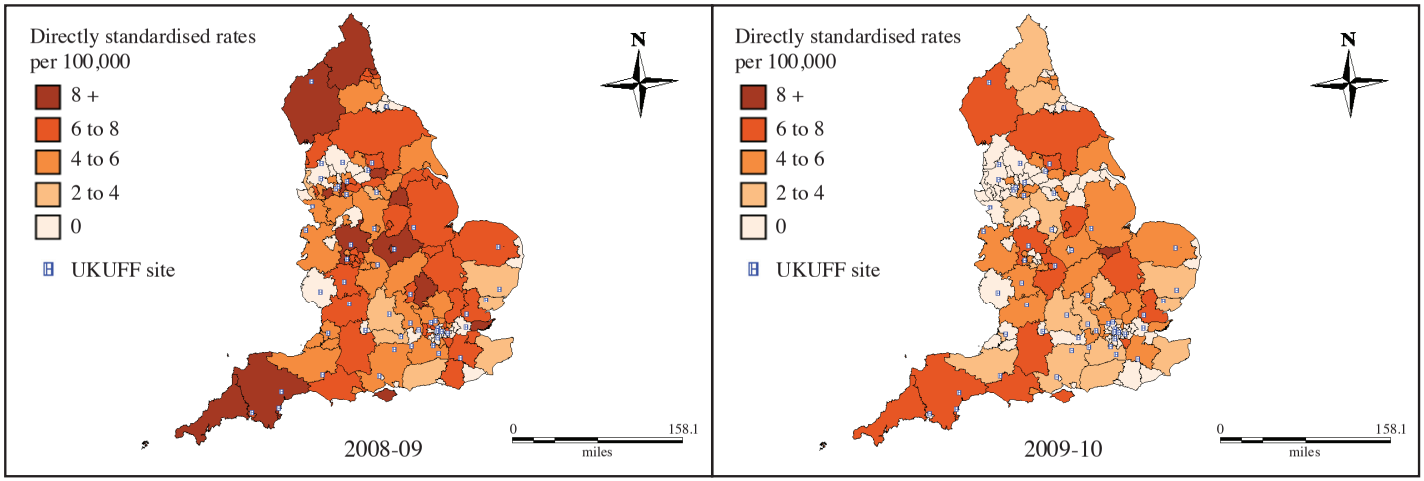

Figure 2.3: Geographical variation in RCR. Age and gender standardised rates of RCR only, by English PCT between 2008–9 and 2009–10 plus locations of UKUFF recruitment sites.

2.4 Discussion

This study has demonstrated a substantial increase in the use of SAD over the past decade for the treatment of patients with severe shoulder pain and functional restriction in England. Rates of use of this surgical procedure increased from just 5·5 per 100,000 in 2000–1 up to 40·2 per 100,000 in 2009-10, despite uncertainty regarding the effectiveness and cost effectiveness of such surgery. In 2002–3 only a few PCTs were performing high numbers of these procedures, over time increasing utilisation of this procedure spread geographically across the country from these epicentres.

Provision of RCR steadily increased over time and peaked in 2008–9 before falling away dramatically by 2009–10. The downturn in use of this procedure coincides with the start of the United Kingdom Rotator Cuff (UKUFF) Trial (ISRCTN 97804283). This is a multi-centre randomised controlled trial involving 58 centres and 90 surgeons from around the UK to measure the clinical and cost effectiveness of different types of surgery for RCR, comparing arthroscopic to open/mini-open repair. The trial completes recruitment in 2012 and will report in 2014. Assessing data collected in the follow-up questionnaire from the UKUFF surgeons, it is clear that attitudes to rotator cuff surgery have changed. This is perhaps one of the reasons we have seen a downturn in rates of surgery in 2009–10, suggesting that simply running a large trial changes practice even before results are published. Other reports from the USA have revealed significant variation in decision making and expectations of outcome amongst shoulder surgeons.[79]

Such increases in provision of SAD are reflected in other health care

systems and recent reports from the USA describe a 254% increase from 29·9 to 102·2 per 100,000 in New York State between 1996 and 2006 with only a 78% increase in orthopaedic surgery overall.[80] The New York State surgeons perform over five times as many decompressions as English surgeons. Analysis of data from the National Hospital Discharge survey in the USA between 1996 and 2006 revealed that RCR increased by 141%, particularly for arthroscopically assisted repair (600%) compared to open repair (34%).[81] Significant geographical variation is shown in this study. The introduction of less invasive arthroscopic techniques with lower risks probably accounts for some of the overall increase in the rate of surgery but does not explain the geographical variation. Patient and disease characteristics have not changed over time and there is a growing concern that these procedures are being overused.[74,82]

Observational studies of SAD show positive results in terms of pain reduction and functional outcome with high patient satisfaction rates.[73,83–85] However, equally good outcomes have been noted in studies following patients who had arthroscopic rotator cuff debridement or open RCR in the absence of SAD.[86] Furthermore, comparative studies of SAD versus non-operative treatment options, such as physiotherapy, have not shown any significant difference in outcome between the two treatment modalities.[71,74]

There are a growing number of studies that have tried to assess the effectiveness of SAD against a control.[76,86] In an important, recently reported, randomised controlled trial, SAD plus subacromial bursectomy was compared with bursectomy alone and reported no significant difference in clinical outcome between the two groups.[87] This finding suggests that removing acromial

spurs might not be necessary, thus challenging the principal rationale for the procedure.

It is known that the very process of undergoing surgery can generate a beneficial outcome. This has been shown in the knee where a placebo controlled trial of arthroscopic surgery for knee osteoarthritis found that, despite early benefit, one year results after arthroscopic lavage or debridement were no better than after an entirely placebo operative procedure.[88]

2.5 Strengths and Limitations

The strength of this study includes the use of a large, nationally representative dataset of all admissions for SAD and RCR within NHS hospitals across England. All PCT data were configured to the 2010 PCT boundaries so they are consistent over time, overcoming boundary changes. The main weakness is relying on routine hospital data collected for administrative rather than research purposes. A limitation of using HES data is that private operations are not included. Hence, the study is likely to have underestimated the overall numbers of procedures being undertaken. Further, rates are only adjusted by age and sex and the observed geographical variation in rates of surgery may be partly explained by adjusting for other geographical characteristics and confounding factors, although such information was not made available for this analysis. It is possible that, over the period covered by the analysis, the quality of recording of these surgical procedures improved thus exaggerating any increase in incidence. Concerns have also been raised over the completeness and accuracy of data collected for administrative rather than

research purposes and, importantly, it may contain incomplete or inaccurate diagnostic and operation coding.

2.6 Significance

In the context of the lack of evidence for the effectiveness of SAD and RCR surgery and the significant increase in number of these procedures being performed in England and elsewhere, there is an urgent need for well-designed clinical trials. There is some evidence to suggest that undertaking a large scale multi-centre trial of rotator cuff surgery has reversed the trend of increasing rates of surgery for RCR.

This work highlights the potential for rapid uptake and use of interventions with an unproven mode of action and efficacy as an empirical step in the treatment of health problems that are difficult to manage. The recent change in rate of RCR shows the uncertainty that exists within the orthopaedic community regarding management of rotator cuff tendinopathy. There is a desperate need for greater understanding of the pathophysiology of this condition in order to determine prognosis for individuals and to develop and evaluate novel therapeutic interventions. The potential impact of such research would be substantial, both in terms of efficacy of treatment for the rotator cuff tendinopathy and cost-effectiveness of healthcare provision.

Chapter 3

Development of a Novel Learning Method for Orthopaedic Surgeons Performing Shoulder Ultrasound

3.1 Introduction

The rotator cuff tendon complex forms a structural support to the encapsulation of the glenohumeral joint over the anterior, superior and posterior aspects.[9] Tension applied to this structure through contraction of the rotator cuff musculature, which arises from the scapula, stabilises the glenohumeral joint. This maintains a centre of rotation in the humeral head and pro-

vides the optimum biomechanical orientation of the joint about which the more powerful, externally located muscles of the shoulder girdle can act to manipulate the humerus with respect to the scapula.[89]

Tendinopathy within the rotator cuff tendons causes pain and ultimately leads to macroscopic structural changes to the tendon structure in the form of tears within the tendon and separation of the tendon from the humeral tuberosities.[14] In order to identify and monitor structural changes within the rotator cuff, a variety of imaging modalities have been employed in a clinical setting to provide information that may help to direct treatment of patients with rotator cuff tendinopathy.

Plain radiography and computed tomography (CT) use x-rays to generate images of radio-opaque structures in the body and offer good quality imaging of the bony anatomy of the shoulder.[21] The relative positions of the humerus and the acromion can be used to suggest a defect within the rotator cuff. The shape of the acromion and the degree to which it is 'hooked' have also been used to suggest the severity of rotator cuff tendinopathy and an indication for surgery.[19] Neither of these imaging methods, however, can be used to image the tendon tissue directly and rely upon interpretation of bony anatomy to infer the condition of the rotator cuff.

Radiographic and CT arthrography involve the injection of contrast medium (radio-opaque, radio-lucent or a mixture of both) in to the glenohumeral joint prior to plain radiography or CT imaging. Arthrography offers further definition of the contour of the underside of the rotator cuff tendons, compared with plain radiography or CT, and may demonstrate a full thickness tear through the tendons by displaying a leakage of contrast medium into the subacromial

bursa; this has been shown to be reliable in identifying full thickness tears of the rotator cuff.[90,91] These methods, however, have a limited role when imaging the rotator cuff due to the indirect manner in which they permit evaluation of the tendons, the invasive and irradiating nature of the procedure, the need for staff trained to administer the contrast injection and, with regard to CT particularly, the expense of the equipment and radiographer and radiologist required to undertake the imaging.

Ultrasound and magnetic resonance imaging (MRI) have become the leading modalities for assessing the rotator cuff as they provide a means of imaging the soft tissue structures within the body.[92,93] Using such techniques, the rotator cuff can be directly imaged and the structural status of the tendons evaluated. There are a number of differences between the two modalities that lead each to be suited to alternative settings. MRI is a static imaging modality and can be used to generate topographical slices of the whole shoulder joint in three dimensions providing an overview of all of the structures surrounding the joint including the rotator cuff; this provides the opportunity to investigate the joint as a whole and may indicate the presence of pathology in any of the tissues included. Magnetic resonance arthrography can be performed in a similar manner to radiographic and CT arthrography to enhance the definition of the surface contours within the glenohumeral joint.[94] This method of imaging is relatively limited in its application, however, due to the huge expense associated with the equipment and personnel required to generate the images and the time consuming nature of the study. In comparison, ultrasound provides a relatively cheap, dynamic imaging modality which, although not able to investigate the shoulder joint as a whole, can be

used to focus a high quality investigation into the structure of the rotator cuff. Ultrasound is widely available, non-invasive, safe and well tolerated by patients. The principles of its application are simple to learn and, with the availability of portable, high resolution ultrasound devices, imaging is not restricted to a location within a radiology department. Modern, high resolution ultrasound devices can provide detailed images of relatively superficial soft tissue structures in the body to a resolution of less than 0·5mm. When combined with the ability to perform a dynamic assessment where the shoulder and rotator cuff can be manipulated during the scanning process, ultrasound offers a potentially valuable tool for the assessment of the rotator cuff.[22]

The selection of an imaging modality for clinical or research based evaluation of the rotator cuff must take into account all of the features previously discussed with regard to accessibility, cost and invasive nature of each of these imaging options. When considered in this manner, ultrasound offers a safe, accessible, well-tolerated and affordable method for imaging the rotator cuff that has the potential to provide a versatile means of evaluating the structural integrity of the tendons and allow dynamic, real-time navigation of the tissue for consideration of interventions such as guided injections or tissue biopsy. Before committing to an imaging modality, however, it is necessary to ensure that the quality of investigation permitted by that modality is sufficiently high compared with the other options available and that the imaging methodology can be reliably learned and reproduced by clinicians and researchers wishing to utilise this tool.

Existing imaging of the rotator cuff has focussed on evaluation of the

structural integrity of the tendons and the ability of the imaging modality to reliably identify tears within the rotator cuff tendons. The accurate detection of a full thickness rotator cuff tear provides a quantitative outcome measure for the assessment of such imaging modalities and is of clinical relevance as the presence of a full thickness tear may be an indication for surgical repair.[95] This quantitative measure is used as the primary means of assessing and comparing the reliability of different imaging modalities and also the ability of a user to employ those imaging modalities to evaluate the rotator cuff tendons.[96] The gold standard for detection of a full thickness rotator cuff tear is direct visualisation of the tendons which, in most cases, is undertaken during surgical intervention of the shoulder when the tendons can be examined directly or using an arthroscope. This standard has been used to assess the predictive value of each of the previously discussed imaging modalities and, for ultrasound, where the performance and interpretation of the imaging is highly user dependent, to evaluate the ability of the radiologist, radiographer or surgeon undertaking the scans. The detection of partial thickness tears of the rotator cuff does not offer the same quantitative measure as the definition of what constitutes a partial thickness tear under direct visualisation has not been standardised and is subject to significant observer interpretation; as such, the lack of a consistent standard for comparison renders the evaluation of partial thickness tears of the rotator cuff unsuitable as an outcome measure for validation of the accuracy of imaging modalities.

Plain radiographic and CT arthrography have been shown to have very high sensitivity and specificity values for the detection of full thickness rotator cuff tears when compared to surgical findings.[91,97–99] These methods,

however, rely upon the silhouette of tissue that is assumed to be the rotator cuff tendon in order to infer the presence of a tear in the tendon structure. They also both require the invasive injection of contrast medium into the glenohumeral joint and the need for x-ray irradiation of the patient. Magnetic resonance imaging studies have also been shown to have very high predictive values for the detection of full thickness tears when compared to direct visualisation intraoperatively.[23] The predictive values for the detection of full thickness tears using ultrasound have shown greater variability within the published literature, a feature of this modality that is usually ascribed to the skill and experience of the user completing the scans. A systematic review with meta-analysis from 2011 that included the results from 62 studies comparing ultrasound investigation to surgical findings showed a pooled sensitivity of 0·96 (95% confidence interval (CI): 0·95 to 0·97) and specificity of 0·93 (95% CI: 0·91 to 0·95) for the detection of full thickness rotator cuff tears.[22] The review demonstrated variability of predictive values within the studies and accounted for some of this variation by reviewing the results by user profession. Although not statistically significant, the users with the highest predictive values were musculoskeletal radiologists followed by orthopaedic surgeons and then ultrasonographers, with general radiologists shown to have the lowest predictive values for the detection of rotator cuff tears from each of these professional groups.[22]

Direct comparison of the most commonly used methods for imaging the rotator cuff show no significant difference between the predictive values for ultrasound and MRI detection of full thickness rotator cuff tears.[23,24]

Ultrasound has been shown to be a versatile tool in the assessment of the

rotator cuff; it offers safe, accessible and affordable imaging of the tendons that can be performed in a clinic setting away from the radiology department and can permit dynamic assessment of the shoulder as well as providing a means of navigation for the injection of therapeutic agents in and around the shoulder and potentially for the guidance of a tissue biopsy needle.[100] The limitation of this imaging modality remains the question of the skill of the user performing the scans. In order to ensure that a user can perform scans in an accurate and reliable manner it is necessary that they undertake an adequate training period and maintain practice of their method in order to retain their skills. For non-radiologists wishing to undertake training in musculoskeletal ultrasound the American Institute of Ultrasound in Medicine, the Royal College of Radiologists (UK) and the European Federation of Societies for Ultrasound in Medicine and Biology have each published training guidelines.[101–103] These publications suggest that a clinician must perform a minimum of 150 to 300 scans under the supervision of a qualified musculoskeletal ultrasonographer or radiologist in order to develop proficiency in musculoskeletal ultrasound. Each of the guidelines encompass musculoskeletal ultrasound as a whole and do not offer a training solution for practitioners wishing to utilise ultrasound for a focused and anatomically limited purpose within their area of specialty and in a setting that does not require constant supervision from a trainer. These learning protocols rely upon the expertise of the trainer as a 'best practice standard' against which the trainee can be compared and ultimately deemed competent.

In order to employ ultrasound as a tool for clinical and research applications in the assessment, treatment and sampling of the rotator cuff tendons

it is essential that the proficiency of the investigators using this imaging modality can be evaluated and that the skills required to undertake such investigation can be acquired in a practical manner and an acceptable time frame.

This study aimed to investigate the accuracy of ultrasound assessment of rotator cuff integrity performed by orthopaedic surgeons without prior experience of ultrasound who were following a novel, independent learning protocol.

3.2 Methods

Four surgeons took part in the study: one consultant shoulder surgeon, one shoulder fellow, one orthopaedic registrar and one senior house officer (SHO) in orthopaedics, providing a spectrum of clinical experience. None of the surgeons had prior experience of performing shoulder ultrasound. Prior to participant recruitment each surgeon completed a formal two day training course in shoulder ultrasound instructed by a faculty of experienced musculoskeletal radiologists. The course included theory and practical classes with development and evaluation of technical skills and diagnosis using a variety of ultrasound machines and scanning of volunteers with normal shoulders and existing pathology.

Following approval from the local research ethics committee (Oxfordshire REC C, ref: 09/H0606/43), participants were prospectively recruited between June 2009 and December 2010 from patients scheduled to have 'arthroscopic subacromial decompression with or without rotator cuff repair'. Pa-

tients listed for this surgery presented with subacromial impingement pain elucidated through history and examination findings including 'painful arc', positive Hawkins' and Jobe's tests; they had all failed conservative therapy in the form of subacromial steroid injections and physiotherapy.[16–18] Each participant underwent ultrasound scans of their affected shoulder performed on the day of surgery. Where possible, study participants were scanned by all of the surgeons involved in the study. Each surgeon performed their scan independently, participants were not permitted to divulge any prior knowledge of their condition to the surgeons performing the scans and discussion between surgeons was not permitted until all ultrasound scans had been completed and reported. In order to maintain a high standard of patient care the consultant shoulder surgeon involved in the study had previously examined those participants who were on his operating list when they were seen in his outpatient clinic but the other three surgeons in the study performed their ultrasound scans without any prior knowledge of the participants and without performing a physical examination.

The first fifty scans performed by each surgeon were considered to represent their 'initial training period' and the second fifty scans performed by each surgeon were considered to represent their 'later training period'.

The ultrasound scans were carried out using a portable scanner (GE Healthcare Voluson i) with a 4·7 to 13MHz small parts linear array probe (SP10-16-RS, 34·5mm in length). The machine settings were optimised for shoulder ultrasound prior to the start of the study with help from an industry product and applications specialist. These settings were used by each of the surgeons in the study. A standardised shoulder ultrasound scanning

protocol was used to cover the key areas of potential rotator cuff pathology based on published techniques.[104,105] Patients were seated or slightly reclined for the scans. With the arm to be scanned in a neutral position (hand resting on ipsilateral thigh, palm upwards), the lesser tuberosity, subscapularis and bicipital groove were assessed in axial and sagittal planes. The arm was moved into external rotation to improve visualisation of the subscapularis tendon. The arm was then moved into a position of extension (hand placed on iliac crest) to draw the rotator cuff tendons out from beneath the acromion. The supraspinatus and infraspinatus tendons were assessed in longitudinal (oblique-coronal) and cross sectional (oblique-sagittal) planes. Finally, the posterior fibres of infraspinatus and teres minor were visualised with the hand resting on the contralateral shoulder. Defects within the tendons were identified as previously described by Teefey et al.[96] The surgeons saved ultrasound images to demonstrate the condition of each of the rotator cuff tendons and completed a report form that detailed the findings of the scan. Measurements of the width (anteroposterior measurement) of any full thickness tears identified were determined; those measuring up to 3cm were reported to be small to medium sized and those measuring greater than 3cm were reported to be large to massive. An operative record of arthroscopic findings was retained for each patient and the surgeons who had scanned the patient then received same day feedback after completion of the operating list. Tear size was measured intraoperatively in the subacromial space using a calibrated probe in the anterolateral portal and reported using the same measurements as for the ultrasound analysis. Using this same-day feedback method, the surgeons were able to recall the ultrasound scans they had per-

formed earlier in the day and derive maximum learning benefit from the surgical findings. For further reinforcement and when ultrasound reporting was incorrect, the saved images from both ultrasound and arthroscopy were reviewed to further reinforce and maximise the learning opportunity. A full record of surgeon-performed ultrasound scans, reports and operative record was retained for each participant. In addition, any existing preoperative ultrasound reports that had been completed by the local musculoskeletal radiology department were also collected for comparison.

The detection of a full thickness rotator cuff tear was used as the primary outcome measure for the study with classification of the anteroposterior size of the tear as small to medium (up to 3cm) or large to massive (greater than 3cm) considered as a secondary outcome measure. This size classification was chosen in keeping with the clinical practice in our centre as small to medium tears are considered to be repairable and large to massive tears considered to be of little value in repairing due to the widely published failure rates of attempted surgical repair in tears of this size.[106,107]

Results were tabulated to compare ultrasound findings with surgical findings for each of the surgeons. Predictive values (sensitivity, specificity, the positive predictive value, the negative predictive value, and accuracy) for the identification of full thickness tears of the rotator cuff were calculated from these data. Ninety-five percent confidence intervals were calculated for each of the proportions using a normal approximation method. Partial thickness tears and intact rotator cuffs were both considered to be intact. Chance corrected agreement between the results from each of the surgeons and the local musculoskeletal radiology department was determined by calculating kappa

values. The results from the surgeons who completed over one hundred scans were combined to demonstrate their performance during two time periods: (i) the initial training period, represented by the first fifty ultrasound scans performed by each surgeon and (ii) the later training period. The reported measurements of tear size as small-medium or large-massive from ultrasound and arthroscopy were cross tabulated to illustrate the proportion of imaging and surgical reports that yielded the same results. The proportion of matching reports was calculated as a percentage with confidence intervals as described above.

3.3 Results

Three hundred and three ultrasound scans were performed on 159 shoulders from 156 patients during the study period. Two of the surgeons, the consultant shoulder surgeon and the SHO, scanned 101 shoulders each, the shoulder fellow scanned 50 and the registrar scanned 51; as such, all four surgeons' scans contributed to the analysis of the 'initial training period' of the group but only the consultant and the SHO completed sufficient scans to define the 'later training period'. In 119 cases a preoperative radiology department ultrasound report was available for comparison. Each surgeon performed their ultrasound scans with similar frequency: the consultant shoulder surgeon and SHO scanned patients over the full duration of the study with the shoulder fellow involved for the first half of the study and the orthopaedic registrar for the second half.

Operative findings showed that 74 (47%) of the shoulders had an intact

rotator cuff, 32 (20%) had a partial thickness tear (as defined by any visible fraying of the rotator cuff tendons) and 53 (33%) had a full thickness tear. All 53 full thickness tears included a component in the supraspinatus tendon; thirty-six of these were up to 3cm in width involving the supraspinatus tendon with or without extension into the infraspinatus tendon, seventeen were greater than 3cm involving both the supraspinatus and infraspinatus tendons and four shoulders were found to have a concomitant full thickness tear of the subscapularis tendon.

Table 3.1 details the outcome of each surgeon's ultrasound scans matched with intraoperative findings.

Table 3.2 details the predictive values for these data allowing comparison of performance between individuals.

Sixty-three shoulders were scanned by both the consultant and the SHO. They agreed about the presence or absence of a full thickness rotator cuff tear in 86% of shoulders and showed a kappa value of 0·71 (standard error = 0·09) suggesting substantial agreement between the clinicians. The agreement between these clinicians and the radiology department was equally high with the SHO agreeing with radiology in 85% of 82 shoulders that were scanned by both the SHO and a radiologist (kappa value: 0·70, standard error: 0·08) and the consultant agreeing with radiology in 83% of 78 shoulders that were scanned by both the consultant and a radiologist (kappa value: 0·67, standard error: 0·08).

Table 3.3 shows ultrasound sizing of correctly identified full thickness rotator cuff tears from all four surgeons matched with intraoperative sizing for the two training periods. Ultrasound and intraoperative sizing of the full

Ultrasonographer	Ultrasound Findings	Operative Findings		
		Intact	PTT	FTT
Consultant Initial Training Period	Intact	20	6	0
	PTT	2	2	1
	FTT	2	2	15
Consultant Later Training Period	Intact	19	2	0
	PTT	2	4	3
	FTT	0	1	20
SHO Initial Training Period	Intact	21	1	0
	PTT	3	4	1
	FTT	2	2	16
SHO Later Training Period	Intact	17	3	0
	PTT	4	7	1
	FTT	0	1	18
Shoulder Fellow Initial Training Period	Intact	18	4	0
	PTT	4	7	2
	FTT	1	2	12
Registrar Initial Training Period	Intact	20	6	1
	PTT	2	3	2
	FTT	0	1	16
Radiology Department	Intact	47	14	0
	PTT	3	3	3
	FTT	6	6	37

Table 3.1: Ultrasound reporting of rotator cuff integrity matched with operative findings for each of the surgeons including separation of the initial training period (first fifty scans performed by each of the four surgeons) and later training period (second fifty scans performed by the two surgeons who completed a total of 101 scans each and results from the ultrasound reports of the musculoskeletal radiology department. Tendon integrity classified as 'Intact', 'Partial Thickness Tear' (PTT) or 'Full Thickness Tear' (FTT)

	Identification of Full Thickness Rotator Cuff Tears				
Ultrasonographer	Sensitivity	Specificity	Positive Predictive Value	Negative Predictive Value	Accuracy
Consultant Initial Training Period (n=50)	94% [82-100%]	88% [77-99%]	79% [61-97%]	97% [91-100%]	90% [82-98%]
Consultant Later Training Period (n=51)	87% [73-100%]	96% [90-100%]	95% [86-100%]	90% [79-100%]	92% [85-100%]
SHO Initial Training Period (n=50)	94% [83-100%]	88% [77-99%]	80% [62-98%]	97% [91-100%]	90% [82-98%]
SHO Later Training Period (n=51)	95% [85-100%]	97% [91-100%]	96% [91-100%]	97% [91-100%]	90% [82-98%]
Shoulder Fellow (n=50)	86% [67-100%]	92% [83-100%]	80% [60-100%]	94% [87-100%]	90% [82-98%]
Orthopaedic Registrar (n=51)	84% [68-100%]	97% [91-100%]	94% [83-100%]	91% [82-100%]	92% [85-100%]
	95% confidence intervals given in square brackets				

Table 3.2: Predictive values for ultrasound identification of full thickness rotator cuff tears for each of the surgeons including separation of the initial training period (first fifty scans performed by each of the four surgeons) and the later training period (second fifty scans performed by the two surgeons who completed a total of 101 scans each).

Training Period	Ultrasound Sizing of Tear	Operative Sizing of Tear	
		≤3cm	>3cm
Initial Training Period (n=31)	≤3cm	20	1
	>3cm	4	6
Later Training Period (n=38)	≤3cm	18	1
	>3cm	1	18
Radiology Department (n=42)	≤3cm	27	10
	>3cm	2	3

Table 3.3: Ultrasound sizing of correctly identified full thickness rotator cuff tears matched with intraoperative sizing for the initial training period (first fifty scans), the later training period (second fifty scans) for the two surgeons who completed 101 scans each and for the local musculoskeletal radiology department. Tears categorised as small to medium (≤3cm) or large to massive (>3cm).

thickness tears as small to medium or large to massive showed agreement of 84% (95% CI: 71–97%) for the initial training period of first fifty scans and agreement of 95% (95% CI: 88–100%) for the later training period of second fifty scans for the surgeons who completed over one hundred scans each.

Of the 303 ultrasound scans performed by the surgeons in the study there was the potential for 108 scans to identify a full thickness tear. Eleven scans failed to identify a full thickness tear; ten of these were reported as partial thickness tears and only one was reported as an intact rotator cuff. All of the missed tears were small to medium sized. Fourteen scans incorrectly identified a full thickness tear; nine of these were shown to have partial

thickness tears at arthroscopy.

3.4 Discussion

The use of shoulder ultrasound by orthopaedic surgeons as an adjunct to clinical history and examination can provide important information at point of access for the patient and allows the provision of a 'one stop' clinic, saving time, hospital visits, reducing demand on radiology departments and potentially offering a cost saving to the healthcare system. This study aimed to bridge the gap between the uninitiated orthopaedic surgeon and those with many years of ultrasound experience in an effort to establish some evidence for a suitable minimum training period for individuals wishing to follow this independent learning method.

Current training guidelines in the use of musculoskeletal ultrasound for clinicians who are not radiologists require the learning clinician to be supervised directly by a qualified musculoskeletal ultrasonographer or radiologist for at least 150 to 300 scans.[101–103] The need for a supervising radiologist or ultrasonographer to act as the 'gold standard' within the confines of the radiology department is rather limiting. The significant time investment required by the learning clinicians and supervising radiologists or ultrasonographers to complete this training renders these protocols unfeasible for non-radiologists. Our learning method utilises arthroscopy as a gold standard for assessment of rotator cuff integrity. Combining this gold standard with same day comparison of ultrasound and arthroscopic findings permits learning whereby surgeons can hone their ultrasound technique and image interpretation quickly

and accurately by using a definitive outcome measure against which they can judge their findings rather than the subjective opinion of another clinician. The same day image comparison allows for positive reinforcement of correct ultrasound findings and insight into the reasons for errors made.

The predictive values for ultrasound identification of a full thickness tear attained by the surgeons using our learning method from their initial training period of their first fifty scans show a high level of proficiency even at this stage. The values attained during the later training period of their second fifty scans are comparable to published figures for surgeons experienced in shoulder ultrasound and musculoskeletal radiologists.[24,108,109] These data are detailed for comparison in Table 3.4.

When compared to the predictive values for the identification of full thickness tears demonstrated by the local musculoskeletal radiology department (sensitivity 93%, specificity 85%, positive predictive value 76%, negative predictive value 96%, accuracy 87%) the results attained in the study show the surgeons demonstrated a similar level of ability to identify full thickness tears within the initial training period of their first fifty scans using this learning method. The ultrasound measurement of tear size demonstrated by the surgeons was also comparable to the results seen from the local musculoskeletal radiology department. When categorising the tears into clinically useful groups, as small to medium (up to 3cm) or large to massive (greater than 3cm) the agreement between preoperative ultrasound measurements and intraoperative sizing increased from 84% in the initial training period to 95% in the later training period. Due to the small sample size of number of tears identified, statistical analysis of the difference between these values was not

Cohort/ Publication	Identification of Full Thickness Rotator Cuff Tears					
	Sensitivity	Specificity	Positive Predictive Value	Negative Predictive Value	Accuracy	FTT Prevalence
Initial Training Period (n=100)	94% [86-100%]	88% [80-96%]	79% [67-92%]	97% [92-100%]	90% [84-96%]	33%
Later Training Period (n=102)	90% [82-99%]	97% [92-100%]	95% [88-100%]	94% [87-100%]	94% [90-99%]	41%
Ziegler[108] (n=282)	96% [92-99%]	94% [91-98%]	93% [88-97%]	97% [94-100%]	95% [93-98%]	44%
Al-Shawi[109] (n=143)	96% [92-100%]	95% [90-100%]	96% [92-100%]	95% [90-100%]	96% [93-99%]	55%
Teefey[24] (n=71)	98% [94-100%]	80% [64-96%]	90% [82-98%]	95% [86-100%]	92% [85-98%]	65%
Radiology Dept. (n=119)	93% [84-100%]	85% [77-93%]	76% [63-88%]	96% [91-100%]	87% [81-93%]	34%
95% confidence intervals given in square brackets						

Table 3.4: Predictive values and prevalence of full thickness rotator cuff tears (FTTs) within each cohort for ultrasound identification of FTTs for the initial training period (first fifty scans performed by each of the four surgeons) and the later training period (second fifty scans) performed by the two surgeons who completed 101 scans compared with values from published figures for experienced musculoskeletal radiologists and orthopaedic surgeons performing shoulder ultrasound and the local musculoskeletal radiology department.

valid. Results from the local musculoskeletal radiology department demonstrated agreement for the same measurements in 71% of cases, again equalled by the surgeons within the initial training period. It is important to note, however, that preoperative radiology ultrasound scans were not performed on the day of surgery. Figure 3.1 shows the distribution of preoperative timing of ultrasound scans performed in the radiology department; the data showed a range from 6 to 1237 days with a median of 209 days and an interquartile range of 140 to 349 days. The time delay between the radiology performed scans and the day of surgery may have allowed for tears to increase in size and, therefore, impact upon the level of agreement seen between the radiology reports and intraoperative findings. The data collected from the radiology ultrasound reports, however, suggest a tendency towards overcalling the presence of a full thickness tear of the rotator cuff rather than identifying the tendon as intact and the tendon subsequently shown to be torn at surgery, as demonstrated by the high degree of sensitivity compared to specificity calculated from the radiology ultrasound reports. This limitation does not detract from the high level of agreement seen between the surgeons' ultrasound measurements and intraoperative findings.

Eleven scans failed to identify a full thickness rotator cuff tear and fourteen scans mistakenly identified partially torn or intact tendons as containing a full thickness tear. These mistakes may reflect inexperience of the user, limitations of the imaging modality in terms of technological capability or even patient variables such as anatomical differences and body habitus. Nonetheless, the rate and type of mistakes made are comparable to those reported in recent published results of ultrasound reporting compared to surgical findings

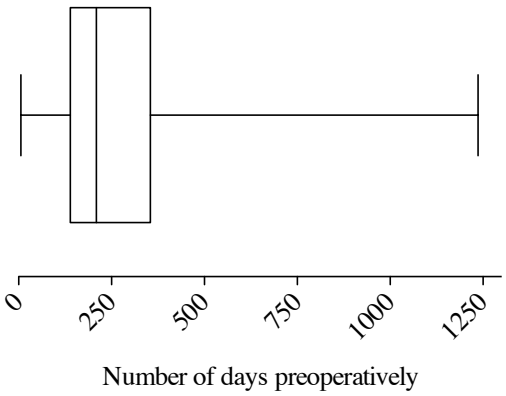

Figure 3.1: Box and whisker plot showing the range, median and interquartile range of timing of preoperative ultrasound scans performed in the musculoskeletal radiology department.

by experienced users of shoulder ultrasound.[24,108–111]

The learning protocol used in this study offers an independent method of learning for surgeons that may also be used for continued performance monitoring and self-assessment after completion of training in order to maintain a high standard of care. When using ultrasound in an outpatient setting, a surgeon can retain an image log and report findings as part of the medical record; predictive values can be reviewed in those patients who progress to surgery. In this way, surgeons have a method for self-directed training in the use of shoulder ultrasound with a gold standard for comparison and the potential for continuing assessment and revalidation.

With any clinical investigation that relies upon subjective evaluation and technical ability there are limitations that may impact upon its evaluation.

The study was limited by the nature of our patient group; arthroscopic diagnosis was the chosen outcome measure for comparison and, as such, the patients included in the study had already failed conservative therapy and may have had a higher incidence of structural rotator cuff defects than a cross section of patients seen in shoulder clinic. This may represent an example of spectrum bias as the prevalence of a condition within a study population may differ from the target population and affect the apparent predictive values obtained by a diagnostic test used in that population. Table 3.4 details the prevalence of full thickness tears in this study population and that of other recent publications showing this study to have a comparable or lower prevalence of tears than the other papers. This finding could lead to this study having a falsely lower sensitivity for the detection of full thickness tears compared to the other publications.

In order to eliminate any bias presented by the operating list on the day of surgery, all patients recruited to the study were booked for 'arthroscopic subacromial decompression +/- rotator cuff repair'. During the patients' clinic attendance, at least two months prior to surgery, the specialist shoulder surgeon in the study had previously performed a physical examination on the patients he scanned and, in some cases, would have seen a prior radiology report. These issues may have led to bias in his ultrasound reporting although a substantial time had passed between prior clinical assessment and the day of ultrasound scanning in most cases and we did not see a difference in performance between the specialist and the remainder of the group who did not examine the patients or have any prior knowledge of their history.

The study demonstrates that orthopaedic surgeons with varying levels of

clinical experience can become competent in shoulder ultrasound in a relatively short period of time by following an independent learning programme. Importantly, this method of learning offers the opportunity for shoulder surgeons to use their every day surgical practice to audit and improve their ultrasound assessment of the rotator cuff. Combined with the growing affordability and quality of portable ultrasound machines on the market, this learning method facilitates independent training and ongoing validation for surgeon performed ultrasound.

3.5 Significance

The application of the learning method described offers the opportunity for clinicians and clinical researchers to develop proficiency in ultrasound assessment of the rotator cuff over a short period of time. This can be done without the need for constant supervision from a radiologist or ultrasonographer tutor and with the ability to learn from and validate their performance against a gold standard of diagnosis within a short time of having undertaken their ultrasound investigation. Compared to the current training practice within radiology, where a trainee is guided solely by their trainer without an opportunity for timely validation of their investigation against a gold standard, this learning protocol represents a substantial step forwards in the methodology employed for training in this imaging modality. In this study we have focussed on using this method to train orthopaedic surgeons to evaluate the rotator cuff but a similar model could be applied to many aspects of radiological teaching and could be used to improve upon the quality and speed

with which imaging skills can be acquired by clinicians of all disciplines.

The observational study of the learning curve associated with this method for training in shoulder ultrasound has been used to suggest a pragmatic and sensible learning programme for surgeons, which is summarised in figure 3.2. This model has been adopted by the British Elbow and Shoulder Society in their development and publication of guidelines for shoulder surgeons wishing to undertake ultrasound assessment of the rotator cuff within their clinical practice.[112]

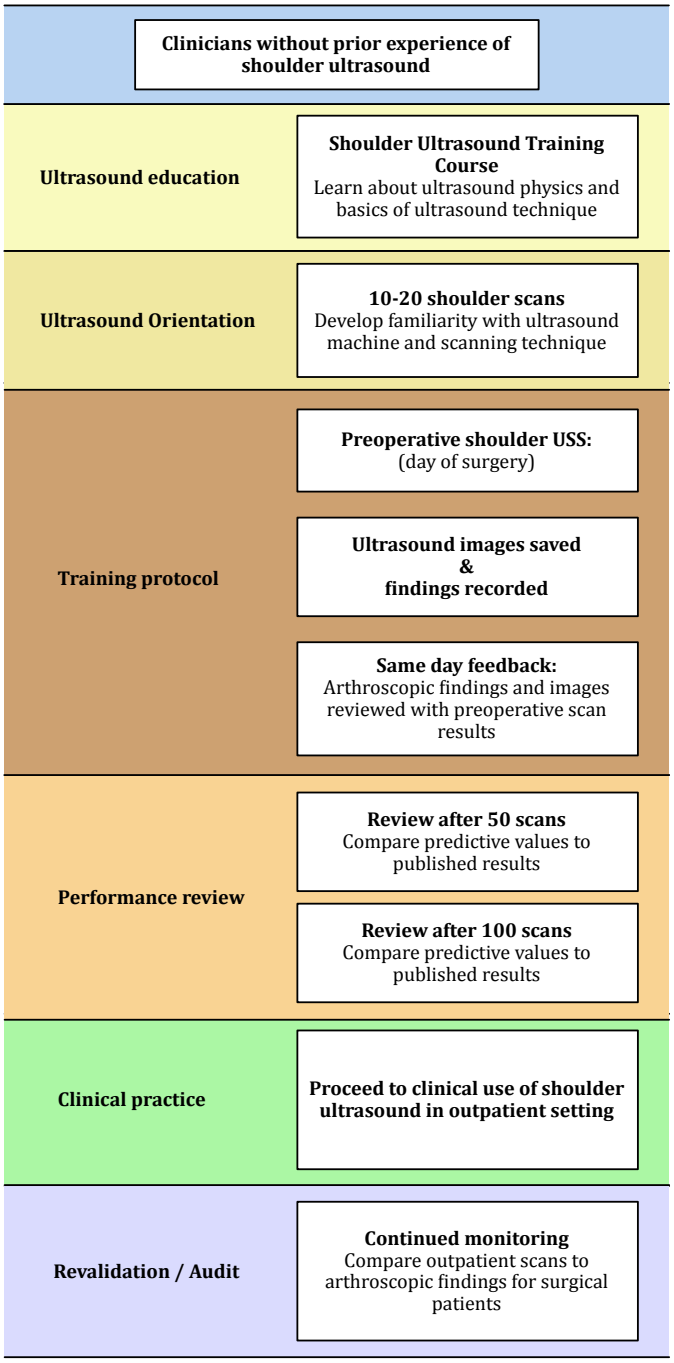

Figure 3.2: Suggested protocol for orthopaedic surgeons without prior ultrasound experience training in ultrasound evaluation of the rotator cuff.

Chapter 4

Contrast Enhanced Ultrasound of the Rotator Cuff

4.1 Introduction

In a clinical setting, when a patient presents with shoulder pain that may be attributed to rotator cuff tendinopathy, the most reliable assessment of tendon condition that can be elicited using current imaging modalities is the presence or absence of a full thickness rotator cuff tear; even the accurate detection and measurement of a partial thickness tear is variable.[22,24,110] These structural measures of tendon condition represent the late stages in a progressive spectrum of tendinopathy, which culminate in the physical failure of the tendon.[14] Although the presence of a full thickness tear may suggest that the tendon is failing both physically and biologically, the detection of such a defect does not give any direct information regarding the quality of the tendon tissue with regard to the degree of viability and, in particular, heal-

ing potential within the tissue. In addition, the absence of a full thickness tear does not indicate that the tendon is 'healthy' and currently employed imaging modalities offer only subjective, unvalidated assessment of the tissue state of the intact rotator cuff. The development of an imaging biomarker to indicate the biological condition of the tendon tissue under investigation and the prospect for successful healing of the tendon tissue under investigation would offer a useful tool in the clinical management of patients with rotator cuff tendinopathy.

Previous tissue analysis studies have evaluated tendon tissue from the torn edge of supraspinatus tendons with full thickness tears that are undergoing surgical repair.[30,60] Many of these studies suggests changes in vascularity of the rotator cuff tendon tissue at different stages of tendinopathy. Changes in the degree of vascularity within the tendon tissue have also been demonstrated by in vivo measurements of tissue metabolism and oxygen consumption.[113] Measurement of tissue vascularity offers a potential target for imaging studies of diseased tissue.

The supraspinatus muscle and tendon have been shown to receive vascular supply from the suprascapular artery and the acromial branch of the thoracoacromial artery respectively.[37] Within the supraspinatus tendon, however, the vascular bed has been shown to comprise a sparse capillary network with relatively avascular regions seen towards the distal insertion of the tendon and, in particular, on the articular side of the tendon.[114,115] Quantification of the vascular volume present within the tendon tissue would require the application of an imaging modality with a very high degree of sensitivity and resolution due to relatively avascular and micro-anatomical nature of the

vessel bed within the supraspinatus tendon. Doppler ultrasound has been used to assess vascularity within tendinopathic patellar tendons, although the very low amount of vascular tissue present within the supraspinatus tendon renders this method unsuitable for evaluation of intratendinous vascularity in the rotator cuff.[116] Contrast enhanced ultrasound (CEUS) offers a more sensitive and higher resolution detection of microvascularity than Doppler modalities.[117] Doppler ultrasound relies upon the movement of blood within the vasculature; relative movement of the probe and the patient prevent this modality from detecting microvascular flow and the flow rate in the capillary bed is also very slow relative to larger vessels, limiting the ability of Doppler ultrasound to detect blood flow in areas of limited vascularity. In comparison, CEUS relies only upon the acoustic characteristics of the contrast medium used and is capable of detecting and quantifying much lower volumes of blood within a tissue and without the need for rapid flow to permit detection.[118]

CEUS uses an intravenous gas microbubble agent to provide a quantifiable measure of blood volume and flow within a tissue.[118–120] The microbubbles are comparable in size and behaviour to human red blood cells; detection of their presence and concentration provides the opportunity to accurately evaluate the vascularity of a tissue.[121,122] For any imaging contrast agent, the substance used must behave differently to body tissues in response to the imaging modality being used; for x-ray imaging air and barium are used as contrast agents as they are relatively radio-lucent and radio-opaque respectively when compared to body tissues.[123] Ultrasound contrast agents consist of gas-filled microbubbles suspended in solution that are injected intravenously into the systemic circulation. The microbubbles are compressible

by sound waves due to their gas core, unlike body tissues which are relatively incompressible by sound; this property of gas-filled microbubbles provides a variable response to ultrasonic sound that can be manipulated using modern ultrasound machines to isolate reflected sound from microbubbles within an ultrasound signal and remove the background tissue from the image.[124,125] This imaging method is achieved by emitting alternating inverted or variable strength pulses of sound from the ultrasound transducer. Body tissues reflect these sound waves in a linear manner, i.e. if the waveform of an emitted pulse of sound is inverted, the waveform of the reflected sound from the body tissues will also be inverted; the same linear response is seen if the emitted pulse is doubled in amplitude then the reflected sound from the body tissues also doubles in amplitude. Using this principle, emitting two consecutive pulses of sound from the transducer, the second waveform being the inverse, or mirror image, of the first, the two reflected pulses of sound from the body tissues should also be the inverse of each other. When the ultrasound machine adds together these two reflected sound waves, the result should be zero signal from the body tissues. Conversely, the microbubble contrast agents, due to their compressible nature, do not reflect sound in a linear manner and when two reflected pulses of sound from a microbubble are combined, they result in a measurable signal output rather than zero as should be the case for the body tissues. This principle is illustrated in figure 4.1. Although there will inevitably be a degree of noise and scatter artefact within the reflected sound, combination of the whole ultrasound signal results in an image that is made up, almost exclusively, of signal returned from the contrast agent with subtraction of the body tissues from the image.

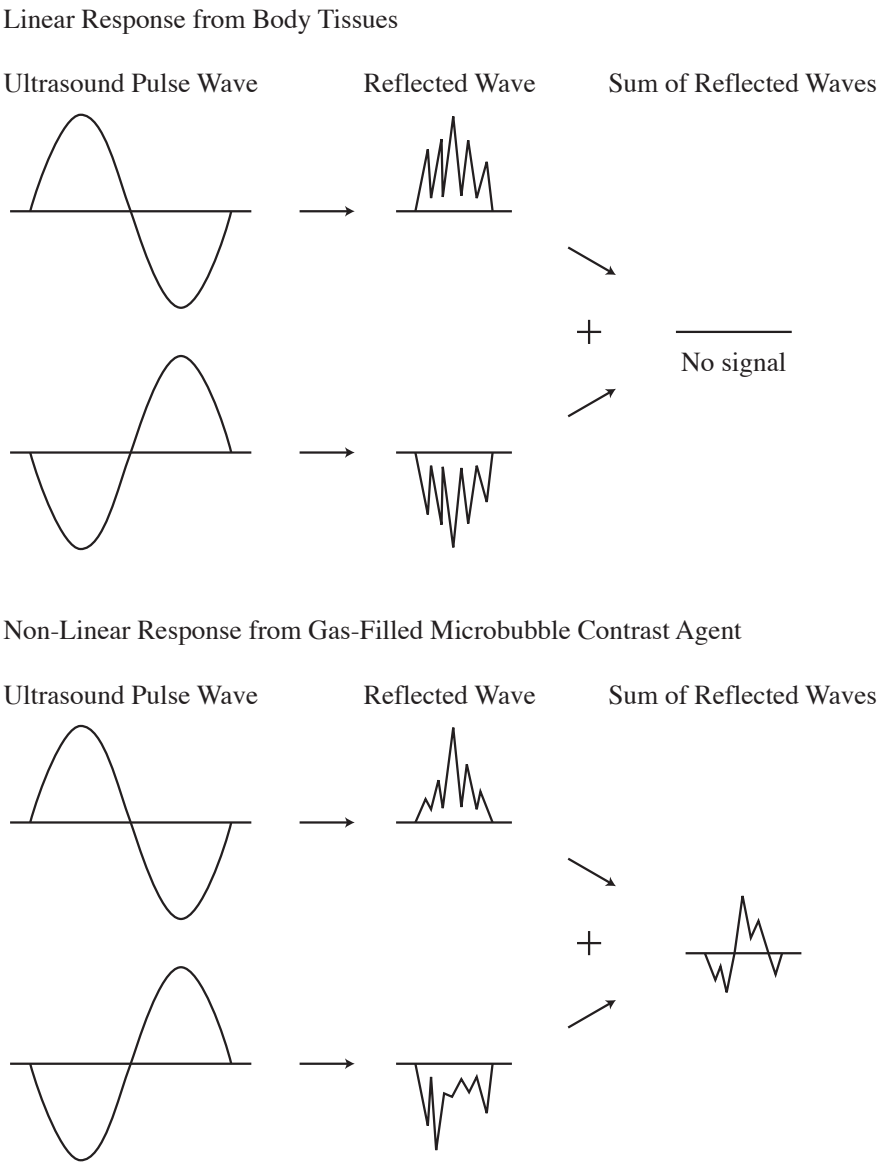

Figure 4.1: A diagrammatic representation of the principle of pulse inversion ultrasound demonstrating how the linear response to sound from body tissues results in zero signal when the reflections from two inverted pulse waves are combined whereas the non-linear response to sound from the microbubble contrast agent results in a detectable signal when the two reflections are combined.

CEUS technology has been used to examine a variety of body tissues and function including monitoring malignancy, cardiac muscle perfusion, skin free flap perfusion, vesico-ureteric reflux, deep venous flow and inflammatory arthritis.[126–134] Several studies have evaluated microvascular blood flow within and surrounding the rotator cuff tendons in normal, torn and repaired rotator cuff tendons.[135–139] Each of these studies has demonstrated good uptake and detection of the contrast agent in the tissues surrounding the rotator cuff although, in each case, the intratendinous regions of the image have shown limited vascularity. A reliably positioned arterial vessel has been identified within the peribursal region of the rotator cuff in each of the studies that can serve as a positive control for the presence and wash-in and wash-out phases of the contrast agent.

The main ultrasound contrast agent in use currently is SonoVue® (BR-1, sulphur hexafluoride, Bracco International BV, Amsterdam, Netherlands).[140] SonoVue® is a second generation ultrasound contrast agent consisting of sulphur hexafluoride gas bubbles surrounded by a phospholipid coating. Sulphur hexafluoride is less soluble than air resulting in a longer half life from this agent compared to the first generation agents, which used air filled microbubbles.[141]

The aim of this study was to evaluate the feasibility of employing CEUS to quantify blood volume within the supraspinatus tendon that could subsequently be correlated with tissue analysis to develop an imaging biomarker of tendon vascularity.

4.2 Methods

Approval for the study was granted by the local research ethics committee (Oxfordshire REC B, ref: 09/H0605/111 and 09/H0605/72). Participants were recruited in secondary care from patients with shoulder pathology; participants were excluded if they had a full thickness tear of the rotator cuff detected on ultrasound or any of the listed contraindications for administration of SonoVue® contrast.

In an effort to overcome the limitations inherent in imaging a tissue with such limited vascularity, the most advanced CEUS technology available was employed in the study. The second generation ultrasound contrast agent SonoVue® (BR-1, sulphur hexafluoride, Bracco International BV, Amsterdam, Netherlands) was used in conjunction with a GE Healthcare Logiq E9®) ultrasound machine. The CEUS studies were undertaken using a 9L-D linear array ultrasound probe (2 to 8MHz) emitting a contrast specific pulse mode at 4·5MHz and a low power giving a mechanical index of 0.13 to maximise the backscatter from the SonoVue® microbubbles as described in the technical paperwork for the contrast agent.[142] The participants were seated in a slightly reclined position for the investigation with the shoulder to be investigated extended and internally rotated to draw the supraspinatus tendon out from beneath the acromion and the probe placed onto the anterolateral aspect of the shoulder to provide a longitudinal view of the anterior portion of the supraspinatus tendon as performed in previous CEUS investigations of the rotator cuff.[135–139] A 4·8ml bolus of SonoVue® contrast (sulphur hexafluoride microbubbles 8μL/45μg per mL) was injected intravenously into

the contralateral arm over 5 seconds followed by a 10mL flush of normal saline. Video loop recording of the ultrasound images was commenced as the contrast was injected and recorded for two minutes.

The video loops were downloaded from the ultrasound machine and analysed offline using Qontrast® software (Bracco S.p.A., Milan, Italy). Figure 4.2 shows the images generated from the ultrasound machine: one low resolution b-mode ultrasound video image that was used to ensure consistent positioning of the ultrasound probe and a second video image showing the real time capture of contrast intensity within the image.

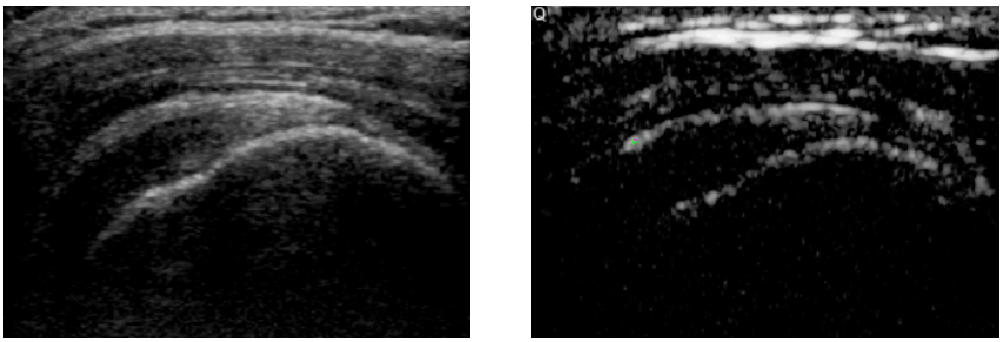

(a) B-Mode Ultrasound Image. (b) CEUS Image

Figure 4.2: Video images generated by the ultrasound machine during a contrast enhanced ultrasound study.

Figure 4.3 shows a parametric image of cumulative CEUS image intensity within the tissue over the whole video loop generated by the Qontrast® image analysis software. The image shows a topographical representation of the cumulative amount of contrast signal recorded over the entire video loop for all areas of the image; this allows the investigator to visualise areas of high

or low contrast signal within the image that would not be as easily identified if a single frame from the video footage was used.



(a)

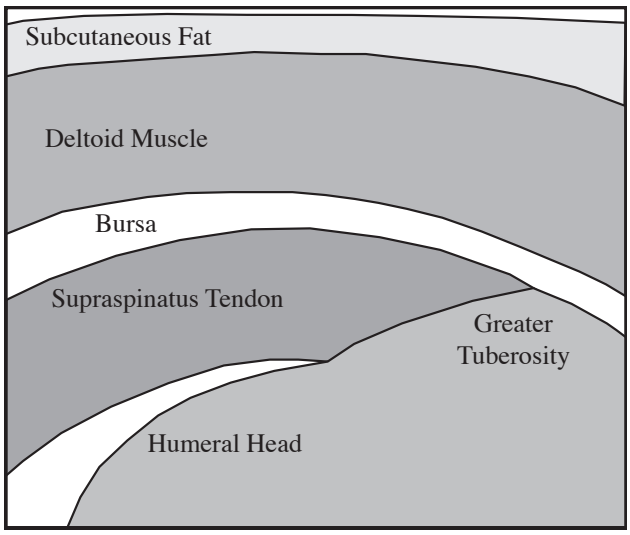

(b)

Figure 4.3: (a) Parametric image of cumulative contrast signal detection generated by the Qontrast® image analysis software from the CEUS video loops. (b) Topographical map of the structures displayed in the parametric image.

Three regions of interest (ROIs) were selected within the image for analysis and:

- peribursal arterial control ROI
- distal 1cm of the supraspinatus tendon
- distal 2cm of the supraspinatus tendon.

The location of these ROIs is shown in figure 4.4

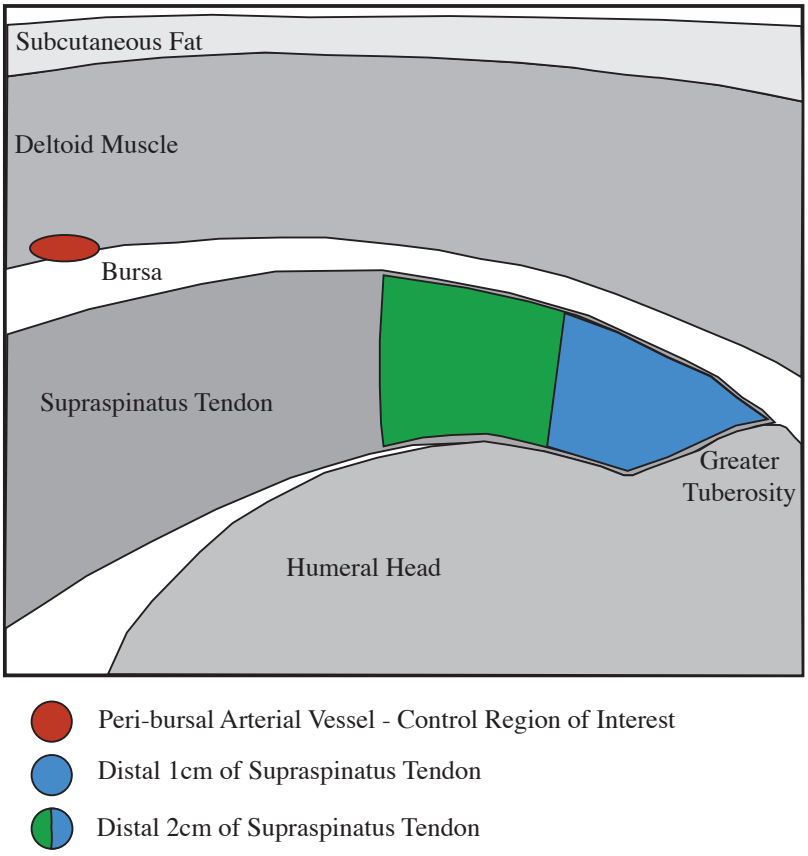

Figure 4.4: A topographical diagram showing the regions of interest defined for analysis within the CEUS image.

The image analysis software was used to generate time-intensity curves for each of these ROIs. These graphs could then be used to evaluate the amount of contrast enhancement seen from a ROI as a measure of blood volume within that area.

CEUS investigation of a region of vascularity within a tissue will generate a time-intensity curve showing a 'baseline' period between the time of contrast injection and arrival of contrast at the tissue under investigation, this period lasts for around 30 seconds. The curve then displays a peak in image intensity as contrast is detected within the ROI which rises and falls over around 30 to 45 seconds, this is the 'first pass' of contrast through the tissue. A second, smaller peak can be seen following the first as the contrast makes a 'second pass' through the tissue. The short half life of the contrast agent results in image intensity returning to baseline between two to three minutes. Calculating the area under the 'first pass' curve can be used to indicate a blood volume within the tissue under investigation.[118]

4.3 Results

Fifteen participants were recruited to the study. Each underwent CEUS evaluation of the supraspinatus tendon in the shoulder for which they were receiving treatment. There were no adverse events associated with the administration of the intravenous contrast agent and clear CEUS videos were collected from each individual and the videos analysed offline to produce time-intensity curves for each CEUS study.

All peribursal arterial control ROIs demonstrated good uptake of contrast

with the expected pattern for the time-intensity curve demonstrated clearly in each investigation. The intratendinous ROIs, however, did not show any clear increase in image intensity when compared to the first pass time period seen in the control ROI. Figure 4.5 shows a typical example of the raw data time-intensity curves generated from each study. Figure 4.6 shows the same data that has been smoothed using a simple moving average to better illustrate the first and second pass peaks seen in the control ROI.

The time-intensity curves demonstrated a high degree of variability in the image intensity seen in each ROI, even within the baseline period where no contrast was present within the tissue under investigation. The lack of any clear upward deflection of image intensity within the intratendinous regions suggested that the CEUS method used may not be sensitive enough to detect the minimal levels of blood, and hence contrast, within the tendon tissue. Figure 4.7 shows the average image intensity recorded across all fifteen CEUS studies for the baseline period and the first pass period for each ROI. The time periods were defined for each study using the arterial control ROI as a reference; the baseline period extended from the injection of contrast (time = zero seconds) to first upward deflection of the control curve and the first pass period extended from that time point until the end of the downward curve following the peak of the first pass. A highly significant ($p < 0.0001$) increase in image intensity from the baseline period to the first pass period was seen for the arterial control ROIs although the image intensity for the two time periods showed no significant difference for the distal 1cm supraspinatus ROI ($p = 0.74$) and the distal 2cm supraspinatus ROI ($p = 0.99$).

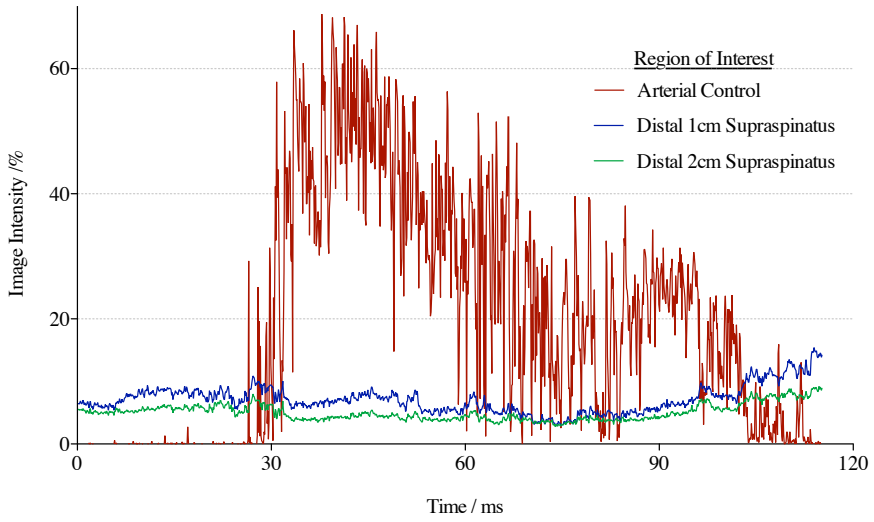

Figure 4.5: An example of the time-intensity curves generated from the CEUS studies of the supraspinatus tendon and surrounding peribursal arterial regions of interest.

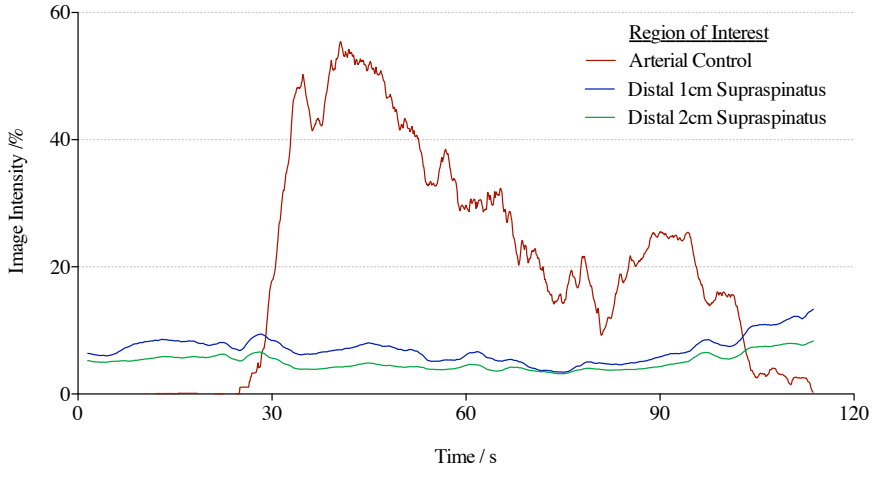

Figure 4.6: A smoothed time-intensity curve generated using a simple moving average from the data displayed in figure 4.5.

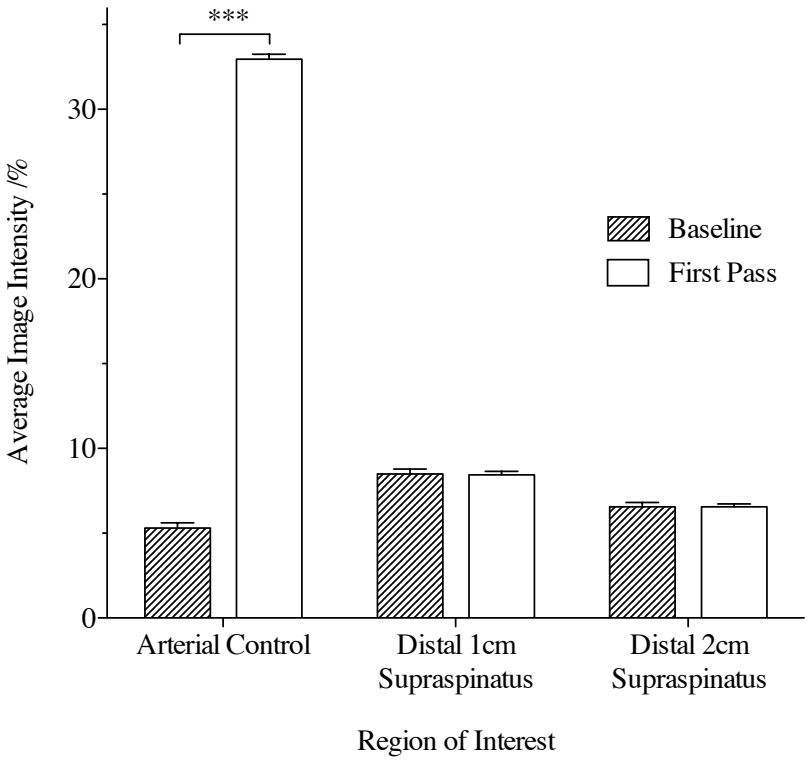

Figure 4.7: Image intensity during the baseline and first pass time periods for the arterial control ROI and the two intratendinous ROIs. (*** denotes $p < 0.0001$), unpaired t-test.

4.4 Discussion

Previous study of human cadaveric rotator cuff has demonstrated a microvascular capillary bed within the supraspinatus tendon.[114,115] The pattern of vascularity was shown to be sparse, particularly on the articular side of the tendon, and the tissue as a whole was demonstrated to be relatively avascular in comparison to other body tissues such as muscle and skin. The volume and flow of blood through the supraspinatus tendons of the participants studied

in our cohort was insufficient to be quantified using the ultrasound technology and contrast agent employed. These technologies were deemed to be the most sensitive and advanced means available for microvascular quantification at the time the work was completed.

CEUS is a growing area within radiology and is being driven by the use of CEUS to define the extent of tumour tissue in organs such as the liver, monitor growth and regression of tumours and, ultimately, to use targeted microbubble technology to deliver therapeutic compounds directly to the target cells.[143–145] The applications for CEUS are extremely broad as, the opportunity to monitor vascular characteristics and changes within a tissue, can be used to infer stage, progression and recovery of tissue pathology. Where Doppler ultrasound modalities have become commonplace for evaluating large and medium sized blood vessel flow, CEUS can offer similar investigation of microvascular flow as well as blood volume due to the fact that CEUS relies upon the presence of microbubble contrast rather than fluid flow in order to detect the presence of blood.[118]

Existing work using CEUS to evaluate the microvascularity of the rotator cuff has demonstrated extremely low levels of detectable microbubble contrast in ROIs selected within the substance of the supraspinatus tendon.[135–139] Each of these investigations, as with this study, has shown good uptake of contrast from the tissues surrounding the rotator cuff tendons demonstrating the correct application of the CEUS method and the principle that this modality can be used to evaluate microvascularity in musculoskeletal tissues with sufficient vascular architecture. Although several of these studies have claimed to show recordable and variable rates of contrast

uptake in the supraspinatus tendon, the level of noise and movement artefact generated from this imaging modality raises questions about the validity of such measurements when the overall values of contrast uptake being recorded are so small. Definition of the ROIs within the image analysis stage of the CEUS process is vital in ensuring accurate results; movement artefact can easily result in an area of the image demonstrating intratendinous tissue at one time point but bursal tissue, for example, at another. This artefact is accounted for to some degree by the movement correction algorithms present in the image analysis software used although, in our experience, the variability of positioning of a ROI throughout a video loop may have significant bearing on the outcome of the investigation. This limitation would be of much less significance when imaging a highly vascular tissue such as the liver or myocardium, as the inherent measurement error in the method would be much lower relative to the absolute measurement of contrast within the tissue. When imaging a tissue with such minimal vascularity as rotator cuff tendon, however, the low sensitivity of this modality to record intratendinous contrast raises issues about the suitability of CEUS for this application.

The sensitivity with which any imaging modality can detect its intended target tissue or contrast medium will vary across a range of conditions determined by the type and setup of the equipment being used and the tissue being imaged. Utilising any imaging method at the limits of investigative capacity may result in unreliable data being collected. In such circumstances an alternative imaging modality, more suited to the conditions being imposed, must be considered.

In this study we employed the latest CEUS technology available to max-

imise the sensitivity of the investigation to quantify blood flow and volume within the supraspinatus tendons of a group of patients with shoulder pathology. The participants varied in age from 38 to 73 and were being treated for conditions including rotator cuff tendinopathy, oseotarthritis and glenohumeral instability. Despite this wide range of ages and pathology present within our cohort, none of the CEUS investigations detected a significant presence of contrast within the intratendinous ROIs studied. While we were unable to reproduce the intratendinous results reported in previous studies of CEUS assessment of the rotator cuff, it is unlikely that our cohort was sufficiently different from those studied previously to explain this outcome.[135–139] In support of the method used in this study, the degree of variability seen from the results of time-intensity curve analysis in this work, although difficult to compare, was shown to be much lower than for the previous studies with much tighter confidence intervals defined within the image analysis data.

This work aimed to use CEUS to quantify blood volume within the supraspinatus tendon with sufficient accuracy and reliability that it could be compared with direct tissue analysis to develop a biomarker of rotator cuff tendon vascularity. The study employed the latest ultrasound hardware, optimised to match the characteristics of the most widely used microbubble contrast agent, and rigorous attention to consistency of method between participants. The CEUS investigations showed excellent results for the arterial control ROI studied, confirming the success of the method used, however, the sensitivity of this imaging modality was insufficient to detect the presence of contrast, and hence blood flow and volume, within the supraspinatus tendon.

4.5 Significance

Understanding and treating rotator cuff tendinopathy effectively will require detailed insight into the tissue changes associated with the onset and progression of the condition. In a clinical setting, a reliable and minimally invasive means of imaging and evaluating the biological condition of the rotator cuff tendons will be vital in defining pathology and directing treatment. This study aimed to investigate the suitability of CEUS as an imaging modality that could be used to develop such a tool. The outcome of the investigation, however, suggested that the combination of the avascularity of the tendon tissue and limited sensitivity of the CEUS resulted in this imaging method to be unsuitable for this indication.

Further work must be done to identify alternative, or new, imaging modalities that may be more suited to this task.

Chapter 5

Development of an Ultrasound Guided Rotator Cuff Tendon Sampling Technique

5.1 Introduction

Investigation into the onset, progression and treatment of any pathological or degenerative condition will, almost certainly, require direct analysis of the diseased tissue during the research process. For many conditions, including rotator cuff tendinopathy, cell culture or animal models may be utilised in order to understand the behaviour of the tissues involved and mimic the disease state. Ultimately, analysis of the human tissue in question obtained from various stages of the pathological process as well as before and after treatment offers the most useful and valid source of information in understanding the biological processes involved in the onset and progression of the

condition, the effects of current therapies and the direction for development of novel therapeutic interventions.

Existing research aiming to characterise the tissue characteristics associated with rotator cuff tendinopathy has been limited due to difficulty in acquiring samples of tendon tissue across the whole spectrum of the condition. A variety of sources for pathological and control tissue have been employed in the past. Cadaveric sampling of the supraspinatus tendon has yielded a number of studies with good access to tissue from both intact and torn tendons.[35–47] These studies, however, lack accurate phenotyping of the individual from whom the tissue was obtained, limiting the classification of the tendon samples to 'torn' or 'intact'.

Tissue obtained from the torn edge of the supraspinatus tendon during surgical repair has proved to be a source of samples for many studies.[41–46,48–70] The tissue resected from these samples represents tendon at the terminal stages of clinical progression of rotator cuff tendinopathy when its physical structure has already failed. In addition, the resected edge of these chronic tears may simply demonstrate granulomatous healing, or a failed healing response of tendon tissue that has lost its natural mechanical environment though being detached from its insertion for a period of time. These tissue studies offer very little insight into the tissue changes associated with the onset and early progression of the condition that may lead to structural failure.

A number of studies have sampled supraspinatus tendon at the time of repair of partial thickness tendon tears.[65,146–148] While it is not routine practice for all orthopaedic surgeons, a recognised intervention for partial thick-

ness rotator cuff tears is to complete the tear surgically, resect the edge and reattach the debrided edge to the greater tuberosity. The resected edge of these tendons offers tissue at a slightly earlier stage of failure than from full thickness tears, although still represents tissue that has failed structurally.

Sampling of intact, tendinopathic supraspinatus tendon has been limited to very few studies. Tillander et al. took large, 4x4mm biopsies from the mid portion of the supraspinatus tendon during subacromial decompression surgery.[149] The location of these biopsies does not represent the site of failure in the supraspinatus tendon and such large biopsies are not ethically feasible to take in future studies. Tuoheti et al. obtained tissue from the insertion region of the supraspinatus tendon.[150] The study only yielded five tissue samples, limiting the conclusive value of the work and used another unsustainable sampling method as it was carried out during open subacromial decompression surgery, an operation very rarely performed now due to the widespread use of arthroscopic techniques. Benson et al. also took samples from intact supraspinatus tendon but only as part of a bursal tissue sample that resected a small area from the superior surface of the tendon.[48,151]

Control tissue used for comparison has also been limited with the majority of studies that use a control tissue choosing a sample from the subscapularis tendon, a tissue discrete in anatomy, function and pathology to that of the supraspinatus tendon.[42,48,60–62,68,70] Sampling of control tissue from supraspinatus tendon has only been undertaken using large biopsies that are no longer ethically justifiable.[149]

As a direct result of the difficulty in accessing well phenotyped tissue samples from the spectrum of rotator cuff tendinopathy, there are a lack of tissue

studies investigating the early stages of the condition. This is the stage of disease when patients present with symptomatic shoulders but have intact or only partially torn tendons. In addition to this, there are no published investigations into the biological effects of treatments for rotator cuff tendinopathy by means of tissue analysis before and after a treatment intervention.

A minimally invasive method of tissue sampling that could be carried out in a clinic or theatre setting would offer the opportunity to study the tissue characteristics of rotator cuff tendinopathy across the full spectrum of disease and also permit serial analysis of tissue in a single individual pre- and post-treatment. This may lead to a greater understanding of the aetiology and progression of rotator cuff tendinopathy and provide a method for evaluating the biological effects of treatment interventions currently in use and novel treatments in development.

Ultrasound-guided biopsy of body tissues is a long established technique that has been used to successfully improve diagnostic accuracy of malignancy in many organs of the body including breast, prostate and liver.[152] The technique is quick, relatively easy to learn and can be performed safely using local anaesthetic in a clinic setting. Although there is no previous record of ultrasound guided biopsy of the rotator cuff tendons, such samples have been obtained from human patella and Achilles tendons.[153–157]

The aim of this study was to develop an accurate and reliable method for sampling rotator cuff tendon tissue in a clinic and theatre setting pre- and post-treatment.

5.2 Methodological Development

In order to define an accurate, reproducible, safe and well-tolerated biopsy method for sampling the rotator cuff tendons a number of factors had to be considered including those related to: sampling device used, technical aspects of the biopsy process and participant related factors. A number of logical steps were taken to address each of these areas to ensure that each variable in the sampling process was optimised.

Biopsy Needle Selection

Tissue biopsy can be performed using a variety of methods split simply into open or closed (percutaneous) methods. Open methods require incision and dissection through the superficial tissues to access the target tissue, as performed during surgical interventions; these were not suitable for our indication as they result in an unacceptable level of participant morbidity to be considered in an outpatient setting or during surgery, if open incisions would not normally be performed. The most commonly used percutaneous methods are core needle biopsy and fine needle aspiration. The use of a core biopsy needle to take tissue samples has been shown to offer more reliable and informative diagnoses than fine needle aspiration.[158] Tissue samples taken as a fine needle aspirate can only offer cytological analysis and cannot demonstrate the structural qualities of tissue seen in histological analysis of a core needle biopsy. A core needle biopsy also yields a larger quantity of tissue than fine needle aspiration, providing the opportunity to analyse a wider array of tissue characteristics including cytological, histological, biochemical

and mechanical features. Core biopsy with ultrasound guidance was considered to be the most appropriate method as it could offer a minimally invasive method that has been well described for the sampling of many other body tissues.[152,159–164]

The tissue sampling tools considered were all core biopsy, Tru-Cut® style instruments; the instruments have a sharp-tipped central trocar with a notch positioned behind the tip, from which the sample is ultimately retrieved, the trocar is surrounded by a cannula with a sharpened cutting surface on the leading edge. The central trocar passes through the tissue to be sampled and an area of tissue settles into the notch of the trocar (see figure 5.1a), the cannula then advances over the central trocar and the sharpened leading edge cuts the tissue sample to leave a core of tissue sitting in the notch of the trocar closed within the needle (see figure 5.1b). The whole needle can then be removed from the tissue, the cannula retracted and the core of tissue retrieved. In some of the instruments tested the entire process was manually performed requiring the user to advance the trocar followed by the cannula blade. A number were semi-automatic, requiring manual advancement of the central trocar followed by a spring loaded firing of the cannula blade initiated by the user pressing a trigger. Some of the instruments were full automatic and had a spring loaded central trocar that was advanced first followed almost immediately by the spring loaded cannula blade; this process was initiated by a single press of the trigger by the user.

A variety of core biopsy instruments were considered and evaluated for attributes including mode of action, ease of use, quality and consistency of tissue sample and cost.



(a) Open core biopsy needle (b) Closed core biopsy needle

Figure 5.1: Core biopsy needle shown in open and closed positions.

Following comparison of cost for the biopsy needle options, assuming a requirement of 20 to 100 units, the cost difference between the various brands and types of instrument was not significant. Fully disposable units were slightly cheaper if only 20 units were purchased and units with a reusable mechanism and disposable needles were slightly cheaper if 100 units were purchased. This limited variation in price allowed the choice of biopsy unit to be made purely on the merits of function.

Initial testing was performed by sampling infraspinatus tendon from cadaveric sheep shoulders under direct vision. The sheep shoulder has been used as a surgical model for rotator cuff repair surgery due to the accessibility of the tendon and similar morphology of the infraspinatus tendon of the sheep to the supraspinatus tendon of the human.[165,166] The sheep shoulders were sourced from the local abattoir and selected from animals that had been slaughtered in the previous 48 hours. The biopsy instruments were evaluated on the basis of ease of use and quality of biopsy sample. Instruments were rejected for a number of reasons including: difficult operating mechanism, failure or inconsistency of mechanical function, poor quality of manufacture,

inadequately sharp trocar tip leading to difficulty in advancement through the tendon tissue and insufficient cannula spring strength and edge sharpness leading to crushing of the sample or failure of the leading edge to cut through the tendon tissue. Most tissues sampled using these instruments are of soft consistency such as liver, breast and prostate, hence, the majority of biopsy instruments have been design with only these requirements in mind. Sampling a more fibrous tissue such as tendon required the use of the more powerful instruments with highly sharpened tip and cannula blades.

Two needles were selected following the sheep tendon sampling: the BARD Magnum^{TM} biopsy instrument, a fully automatic unit (figure 5.2a) and the Temno Evolution^{TM} biopsy instrument, a semi-automatic unit (figure 5.2b). Both instruments consistently delivered clean cores of tendon tissue without the need for any manipulation of the needle following firing of the spring to separate the needle from the surrounding tissue (see figure 5.3). Samples retained normal tissue structure without being crushed by the cutting blade of the instrument.

Previous studies using core biopsy needles to sample soft tissue used needles of 14-16 gauge (G), this size of needle was shown to yield samples of sufficient quality and consistency to permit histological analysis.[152,154,167] A 14G needle was selected for this study as it gave a slightly larger sample size than the 16G needle, providing the potential for a greater quantity of tissue analyses; the internal diameter of the cannula of a 14G is 1·6mm.

Following approval from the local research ethics committee (Oxfordshire REC C, ref:09/H0606/11), the two needles were used to sample human rotator cuff tendon intraoperatively in order to determine adequacy of tissue



(a) BARD Magnum ^{TM} biopsy instrument



(b) Temno Evolution^{TM} biopsy instrument

Figure 5.2: Core biopsy instruments selected from sheep infraspinatus tendon biopsy testing.



Figure 5.3: Sample of sheep infraspinatus tendon resected with 14G core biopsy needle.

sampling. Previous rotator cuff tissue studies have used subscapularis tendon tissue as a control tissue for tendinopathic supraspinatus tissue.[42,48,60] These samples are taken from the cut edge of the subscapularis tendon that is detached during an anterior approach to the shoulder for interventions such as glenohumeral arthroplasty and open anterior stabilisation of the glenohumeral joint. Prior to the normal full thickness sample being excised from the edge of the subscapularis, the biopsy instruments were used to take a core of tissue under direct vision from the area of tendon to be excised. The remaining tendon edge was then excised with a scalpel in the usual fashion after a core biopsy had been taken with each instrument. This yielded three samples for comparison: a core of tissue from each of the biopsy instruments and a larger sample resected using a scalpel and forceps.

Biopsies were take during ten surgical cases. The BARD Magnum^{TM} biopsy instrument was easy to use and performed reliably with each biopsy

attempt, delivering a sharply dissected core of tissue on the first pass of the needle in each of the ten cases. The Temno Evolution^{TM} biopsy instrument did not offer the same level of consistency: in three of the ten cases a second pass of the needle was required to secure a biopsy sample as the first pas failed to yield any tissue despite passing though the desired area of tissue under direct vision. Once retrieved, however, the biopsy quality was similar to that of the BARD Magnum^{TM} at a macroscopic level. The semi automatic action of the Temno Evolution^{TM} allowed precise positioning of the trocar tip before firing the cutting needle, however, the manual advancement of the trocar through the relatively tough tendon tissue required significant manual pressure and, in some cases, rotation and manipulation of the trocar to progress through the tendon. The difficulty in passing the trocar tip through the tendon manually, despite the potential benefit of accurate tip placement, was deemed to be a technique that would be poorly tolerated by a conscious patient, even with adequate local anaesthetic in place. The final consideration in terms of practicality with regard to each instrument was that the Temno Evolution^{TM} is a fully disposable device, allowing sampling from consecutive theatre cases, whereas the BARD Magnum^{TM} required sterilisation of the spring base unit between theatre cases.

Review of the practical use of these devices to take core biopsies of rotator cuff tendon showed the BARD Magnum^{TM} biopsy instrument to be the most reliable and easily used device. The instrument was of vastly superior build quality compared to any of the other instruments tested, the needles were sharp and passed cleanly and accurately through the tissue and the spring mechanism was extremely powerful which, when combined with the fully

automated action of the instrument, facilitated the clean passage of the trocar and cutting cannula through the tissue and resulted in high quality core biopsies taken on the first pass of the needle using this device. The BARD Magnum^{TM} was selected as the device for further testing. The core biopsies taken with this device from human subscapularis tendon were compared with the larger resection samples taken at the same time to assess microscopic integrity of the biopsy; the larger resection samples were used as the existing quality standard for rotator cuff tendon biopsy.

The tissue samples were placed directly into 10% buffered formalin and processed for histological analysis as detailed in appendix B. During sectioning of the paraffin-embedded tissue the core biopsy samples were found to section reliably and cleanly. Compared to the larger tissue samples the core biopsies demonstrated less tearing of the paraffin-embedded samples and no incidences of pull out of the sample from the paraffin block which had been an issue in the past with the larger resection tendon samples.

Slides produced from each tissue sample were stained with Haematoxilin and Eosin as detailed in appendix B. The slides were imaged using a Zeiss Imager M1 light microscope at 200x magnification to evaluated the quality of the sections generated from each of the three samples. The microscopic quality of the tissue sections produced from the core biopsies was shown to be equal to that of the larger resection samples. Figure 5.4 shows microscopy images taken from the two types of tendon biopsy.

The outcome of this stage in the biopsy method development process has shown the validity of a core biopsy device as a tool capable of obtaining a tissue sample that can be processed and analysed histologically. The BARD

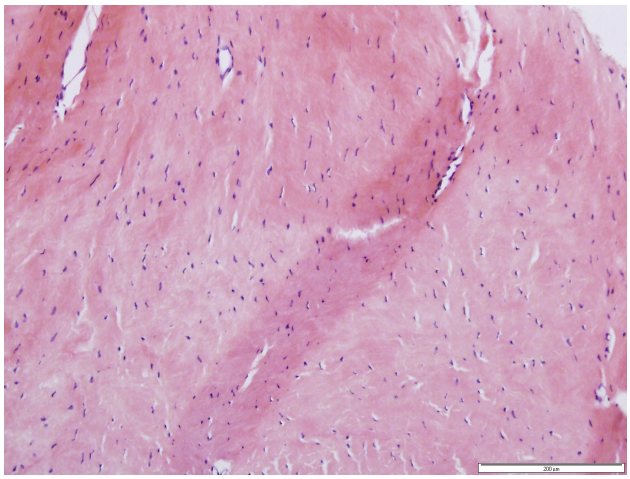

(a) Core biopsy

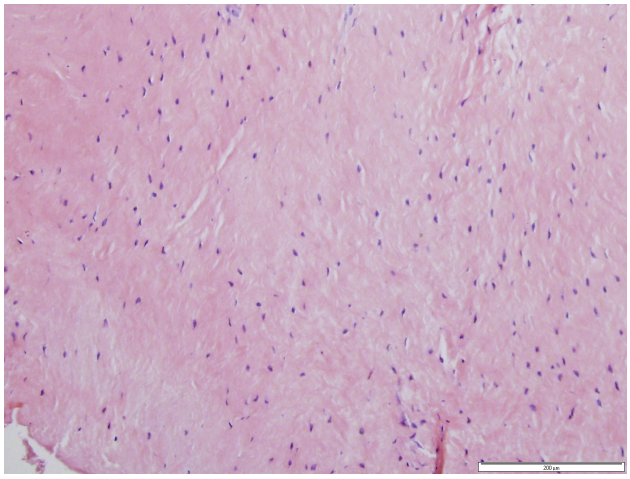

(b) Standard resection biopsy

Figure 5.4: Light micrographs. Human subscapularis tendon samples from one individual, stained with haematoxilin and eosin (Magnification 200x).

Magnum^{TM} biopsy instrument was shown to be a reliable device for sampling human rotator cuff tendon tissue and microscopic evaluation of the core biopsies and the standard resection samples showed comparable quality outcomes.

Ultrasound Guidance of Core Biopsy Needle

The next stage in development of the biopsy method was to define and evaluate the method of imaging guidance used to direct the biopsy device when used percutaneously to sample the rotator cuff tendons rather than under direct vision during an open surgical procedure.

Ultrasound is widely used for the guidance of tissue sampling instruments.[152] During this stage of the methodological development of the biopsy technique it was necessary to develop proficiency in using ultrasound to guide the biopsy needle and assess the precision with which samples could be taken. Training in ultrasound guided biopsy can be undertaken using a phantom model made from materials that mimic the acoustic properties of body tissues resulting in a similar appearance to this tissues when imaged using b-mode ultrasound. Commonly described ultrasound phantom materials include agar and gelatine.[168–174] These materials are cheap, safe, accessible and easily manipulated by including materials such as flour or naturally occur dietary fibre compounds within the mixture to add acoustic density and texture to the ultrasound appearance of the final gel.[171,174] Inclusions in the gel models such as olives, pasta or carrot pieces have been described as targets for ultrasound guided biopsy training.[169]

Phantom models were made using gelatine and psyllium husk fibre with

olives and tinned ham used as inclusions for biopsy. Empirical testing of different concentrations of each mixture resulted in the following ratios: 1L of water to 80g of gelatine powder and 40g of psyllium husk fibre. All of the ingredients were sourced from a local supermarket and an online health product retailer at minimal expense. The models were made in a square, flat-bottomed pyrex dish (approximately 1·5L capacity) lined with aluminium foil to facilitate removal of the model from the dish once set. Boiling water (1·25L) was poured into a large pyrex jug and gelatine powder added to the jug (100g), the mixture was stirred vigorously for around 2 minutes, until the gelatine was completely dissolved. The psyllium husk fibre (50g) was then added to the mixture and stirred thoroughly to ensure even distribution of the fibre. The mixture was then poured into the foil lined dish.

Inclusions were suspended in the mixture at the level of the centre of the model rather than sunk to the bottom of the dish or floating on the surface. This was achieved by fashioning a cardboard lid for the pyrex dish through which long haberdashery pins were passed. The inclusions were impaled onto the pins at the desired level and then the lid placed onto the dish, suspending the inclusions in the mixture (see figure 5.5).

The mixture was allowed to set in a domestic refrigerator overnight. Once set, the pins were removed from the lid, leaving the inclusions now suspended in the gel, the lid removed and the gel model extracted from the dish mould using the aluminium foil which was then peeled off the surface of the model (see figure 5.6).

The models were then used to visualise the inclusions using ultrasound although, due to the opacity of the gel created by the psyllium husk fibre,



Figure 5.5: Cardboard lid for ultrasound phantom mould with haberdashery pins to suspend pieces of olive as inclusions for biopsy.



Figure 5.6: Ultrasound phantom model made using gelatine and psyllium husk fibre.

the inclusions were not visible to the naked eye. Ultrasound scans were performed using a GE Healthcare Logiq E9® ultrasound machine with a linear transducer (ML6-15-D, frequency range 4-13MHz).

The inclusions were then sampled using the BARD Magnum™ biopsy instrument under ultrasound guidance. Initial practice began with large inclusions such as pitted olives before progression to 3mm thick slices of ham. Figure 5.7 shows the b-mode ultrasound appearance of the ham inclusion seated in the gelatine model (figure 5.7a) and visualisation of the biopsy needle once it has passed through the ham slice to take a core biopsy(figure 5.7b). The images show variation in reflectivity of the gelatine in the model as the psyllium husk fibre gravitates towards to bottom of the mixture when the gelatine is setting; as the model has been inverted to perform the biopsies, this appears as darker areas above the workbench reflection and the inclusion model where less fibre is present within the gelatine. This feature did not detract from the value of the phantom model and simply added a layer of variation within the ultrasound image as is seen in the body.

In order to validate the spatial accuracy of the ultrasound guided biopsy method a series of models were created with 3mm thick slices of ham as inclusions. Each slice was stained on the 3mm edge with permanent black ink. The ink was painted onto a single edge of the ham slice to cover the 5mm closest to one corner (see figure 5.8). This provided and area of 3mm in the vertical plane by 5mm in the horizontal plane that was stained with ink as a target for ultrasound guided biopsy. The ink was not detectable by ultrasound but would indicate a successful biopsy of that region of the ham inclusion once a biopsy was taken. Topographical diagrams were made of

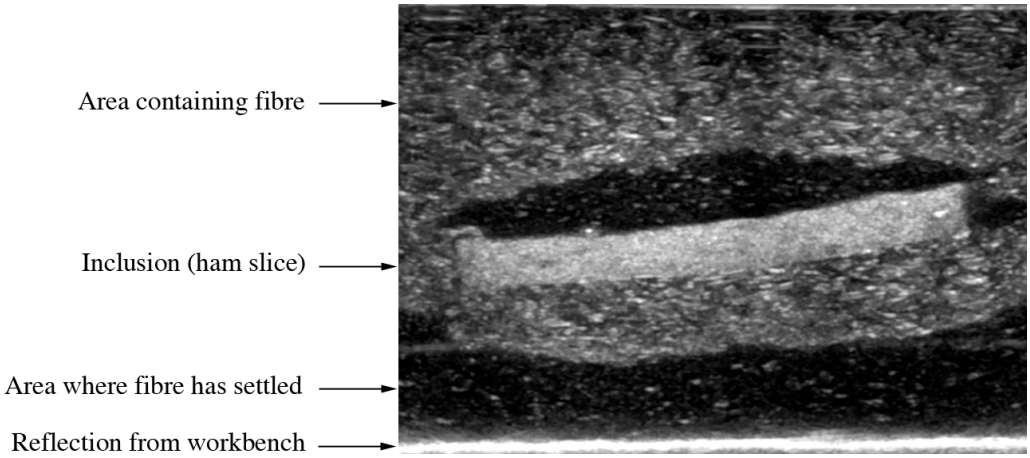

(a) Gelatine phantom with inclusion



(b) Ultrasound guided biopsy

Figure 5.7: Ultrasound images showing the gelatine phantom model with a slice of ham as an inclusion for guided biopsy training

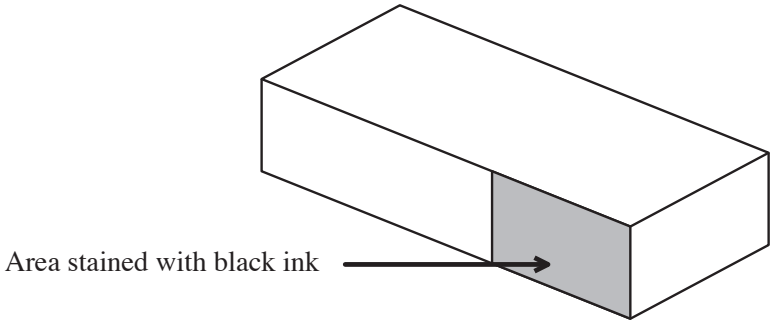

Figure 5.8: Diagram showing the location of ink staining used to identify the desired biopsy region on the ham slice inclusions

the positioning and ink staining of each inclusion ham slice prior to making the gelatine model. Reference was made to the digram when navigating the opaque gelatine model with ultrasound to identify the ink stained edge of the ham slice inclusion and the ultrasound probe was used to guide the core biopsy needle to retrieve a biopsy from the ink stained region.

Using this method it was possible to identify whether or not a core biopsy had been successfully sampled from the desired corner of the inclusion as the sample would be stained on one edge by black ink. In this manner, the technical proficiency of the user and the accuracy of the imaging modality could be tested for spatial accuracy.

Forty ham slice inclusions were embedded in gelatine models and stained with ink as described above before undergoing ultrasound guided core needle biopsy. Twenty inclusions were sampled using a needle guide that attached to the transducer, this held the needle in a single plane and was used in conjunction with the ultrasound machine software, which projected a dotted line on the screen to illustrate the expected path of the biopsy needle. Twenty

Biopsy Technique	Successful	Unsuccessful
Guided (n=20)	19	1
Freehand (n=20)	20	0

Table 5.1: Accuracy of guided and freehand biopsy methods when sampling ink stained inclusion samples. Successful biopsies showed ink staining on the sample and unsuccessful samples did not show signs of ink staining.

inclusions were sampled freehand, viewing passage of the needle in the longitudinal plane of the ultrasound transducer. Table 5.1 shows the results of each biopsy method.

Both methods were successful in retrieving biopsies from an extremely small area of interest. The degree of accuracy shown by each method was not sufficiently different to distinguish between them, however, the needle guide method was found to be cumbersome and more difficult to use as small adjustments in angle could not be made to the biopsy needle once the surface of the gelatine phantom model was breached. When taking a sample from a rotator cuff tendon this technical restriction may result in the need for an extension of the skin incision to be made in order to facilitate a successful biopsy.

The gelatine phantoms permitted the user to practice the technical aspects of the ultrasound guided biopsy method using a cheap, reproducible and easily manufactured training model. The inclusions could be shaped and orientated in various ways in order to develop skills in ultrasound navigation and guided biopsy technique. The free hand ultrasound guided core biopsy method was shown to be accurate in retrieving samples from a small region

of an inclusion item that could only be identified from the shape of the item in question; this technique represented many of the challenges that would be faced when taking a biopsy from a specific region of the rotator cuff.

Human Rotator Cuff Tendon Sampling

The final stage of development was to utilise the equipment and methods previously shown to be successful in obtaining core biopsies from tendon tissue and from gelatine phantom models under ultrasound guidance, to sample a clinically relevant area from human rotator cuff tendons. This technique would require accurate placement of the biopsy needle and would need to be reproducible in both a clinic and operating theatre setting. Ethical approval to undertake sampling of human rotator cuff tenon using this method was granted by the local research ethics committee (Oxfordshire REC B, ref:09/H0605/111).

Chapter 3 describes the training and validation of proficiency of the user to perform ultrasound assessment of the rotator cuff. In order to demonstrate a high level of capability in ultrasound examination of this complex anatomical region the user must have a detailed understanding of the shoulder anatomy underlying the skin and be capable of navigating around those structures using the ultrasound probe. This skill was mimicked during the gelatine phantom biopsy training by providing the user with a topographical diagram of the underlying inclusion samples for biopsy. The user was required to correctly navigate the structures suspended within the phantom model in order to take a biopsy sample from a predetermined area of interest. The same principle would now be used to identify a clinical relevant area of

interest within the rotator cuff tendon complex and utilise the techniques developed to obtain core tissue biopsies from this area.

Rotator cuff tendinopathy shows a spectrum of clinical progression from shoulder pain on activity, through shoulder paint at rest and particularly at night, to a stage where loss of function may develop and the tendon fails leading to a full thickness tear.[14] Tears of the rotator cuff begin most frequently in the supraspinatus tendon; the tears most commonly occur at the bony insertion of the tendon onto the greater tuberosity of the humerus and begin in the main substance of the bony insertion of the supraspinatus tendon, usually sparing the anterior edge, or cable, of the supraspinatus tendon which borders the rotator interval and bicipital groove anteriorly.[39,175,176] It is this region of the supraspinatus tendon, from 5 to 10mm posterior to anterior edge of the tendon, which would be of greatest interest in the investigation of rotator cuff tendinopathy. The bony insertion of the supraspinatus tendon is very clear on ultrasound, as is the anterior edge of the supraspinatus tendon, which represents the lateral boundary of the rotator interval and lies laterally to the bicipital groove. These landmarks offer clear points of reference in two orthogonal planes that can be used to orientate a linear ultrasound probe in a longitudinal plane of the supraspinatus tendon at a point in the mid-substance of the tendon 5 to 10mm posterior to the rotator interval. Using this orientation on ultrasound imaging of the supraspinatus tendon it would be possible to sample the tendon from a know location close the bony insertion and at a site known to represent the most likely area of ultimate structural failure within the tendon. Figure 5.9 shows a diagrammatic representation of the desired ultrasound image achieved with correct

orientation of the shoulder and ultrasound probe and the projected path of a biopsy needle for sampling of the tendon.

The ultrasound plane described was achieved using the same patient positioning as described for evaluation of the supraspinatus tendon in chapter 3. Patients were slightly reclined for the scans, permitting same position to be used for biopsies taken in a clinic setting or in the operating theatre where patients were routinely placed in a 'beach chair' position for rotator cuff surgery.[177] The shoulder was placed into a position of extension to draw the rotator cuff tendons out from beneath the acromion. The supraspinatus tendon could then be orientated in a cross sectional (oblique-sagittal) plane and ultimately visualised in a longitudinal (oblique-coronal) plane for the biopsy needle to be guided.

In order to define the entry point for the biopsy needle and the correct plane required to avoid unnecessary trauma to the skin and deltoid by repeat passes of the biopsy needle or damage to the cartilage surfaces of the glenohumeral joint, the first ultrasound guided biopsies were undertaken in the operating theatre under sterile surgical conditions with sterile covers used to isolate the ultrasound probe and allow it to be used within the operative field. This permitted the biopsies to be taken without the need for prior local anaesthetic injection as the participants were anaesthetised and also permitted simultaneous guidance of the biopsy needle with ultrasound from outside the body and with an arthroscope from within the subacromial bursa and glenohumeral joint. Before passage of the biopsy needle a 40mm green, 21G hypodermic needle was used to determine the entry point and angle for insertion of the larger biopsy needle under ultrasound guidance,

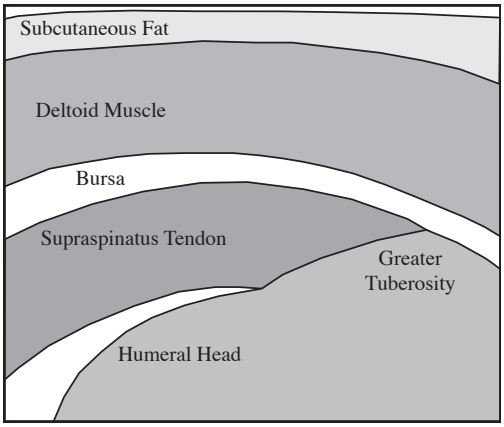

(a) Diagram of ultrasound plane



(b) Ultrasound image of plane

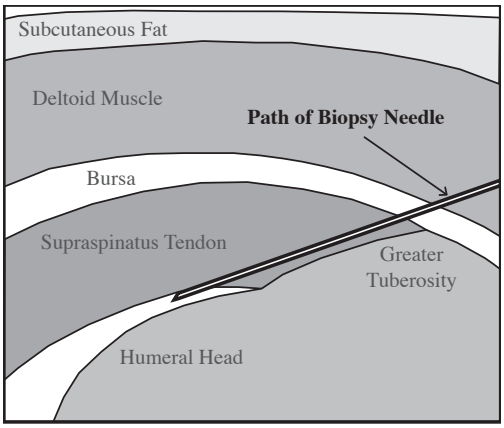

(c) Diagram of path of biopsy needle

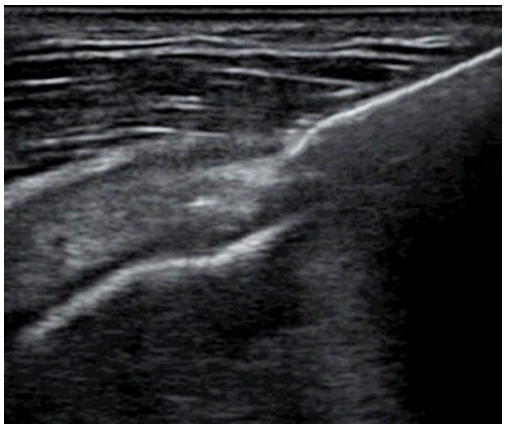

(d) Ultrasound image of biopsy needle

Figure 5.9: Diagrams and ultrasound images showing the longitudinal imaging plane of the supraspinatus tendon to be used for core needle biopsy and the path of the biopsy needle

this permitted the correct entry point to be defined without causing significant trauma to the skin or deltoid should the first pass need to be revised. Once defined, the entry point was incised with an 11-blade scalpel to create a vertically aligned 2mm incision through the skin only. Following priming of the spring mechanism in the device, the 14G needle mounted in the BARD Magnum^{TM} biopsy instrument was passed through the skin incision at the angle defined previously by passage of the hypodermic needle and pushed manually through the deltoid muscle until the tip of the needle could be seen to rest against the bursal surface of the supraspinatus tendon on the ultrasound image. Adjustment of the vertical angle of the biopsy needle could now be made prior to firing in order to ensure that the advancing trocar tip would not contact any bony or cartilaginous part of the greater tuberosity or glenohumeral joint and would pass throughout the supraspinatus tendon at the desired angle and shown in figure 5.9. Depression of the firing button on the BARD Magnum^{TM} biopsy instrument then caused the sequential advancement of the trocar followed by the cutting cannula blade to take a core biopsy of the tendon. For the first few biopsies taken the finishing position of the biopsy needle was visualised with the arthroscope prior to the needle begin removed from the shoulder. This allowed confirmation of the accurate passage of the biopsy needle into the tendon and that the needle had not come into contact with any other structures in the shoulder. This was the case for all of the needles viewed with the arthroscope and confirmed the suitability of the plane and angle chosen for the biopsy needle. The biopsy needle was then removed and cannula sheath retracted to reveal the tendon biopsy which was immediately placed into a sample pot containing the

desired storage medium in order to prevent the sample from drying out or becoming contaminated in the open air.

Following successful biopsy of the supraspinatus tendon in the operating theatre, the technique was performed in a clinic setting. The method was completed under sterile conditions using the same positioning and ultrasound method as had been utilised in the operating theatre. A sterile field was created using a $1m^2$ aperture drape placed onto the skin of the shoulder that had been prepped with chlorhexidine. A sterile trolley was also set up to provide a working space and a sterile cover was placed onto the ultrasound probe. The procedure was performed in two sittings, the first for administration of local anaesthetic and the second for biopsy of the tendon.

The local anaesthetic administration was carried out with the patient positioned as described for the biopsy method above. The entry point for the biopsy was determined using a blue 23G needle to minimise discomfort for the participant. Once the needle was positioned correctly with the bevel adjacent to the supraspinatus tendon, 8 to 10ml of 1% lidocaine was infiltrated into the subacromial bursa, along the track of the needle and into the subcutaneous tissue and skin around the entry point. The entry point was then dressed with a sterile occlusive dressing and the participant was asked to wait for 30 to 40 minutes prior to the biopsy begin taken in order for the field effect of the local anaesthetic to be at an optimal level.

After the waiting period the participant was positioned in the same manner as they had been for the local anaesthetic administration and the ultrasound guided core biopsy was taken in the same manner as has been described for those taken in the operating theatre. Following completion of the biopsy,

any bleeding from the skin edges of the entry point was stopped with direct pressure and the incision was dressed with an occlusive dressing which the participant kept in place for a minimum of three days to limit the risk of infection.

Participant Experience

The development of this ultrasound guided biopsy method for sampling supraspinatus tendon was undertaken in a logical manner to ensure that as many potential variables within the method could be controlled prior to carrying out the method with research participants. In this manner, the experience of the biopsy technique for the individuals recruited to the study did not vary significantly over time as the method had been clearly defined.

In the initial stages of local anaesthetic biopsy the waiting time was only 10 to 20 minutes which resulted in a number of participants having some mild discomfort during the firing of the biopsy instrument. The sensation was described as receiving 'thump on the shoulder' which subsided very quickly. In order to improve the participant experience the local anaesthetic waiting time was extended to 30-40 minutes which resulted in participants feeling little or no discomfort from the biopsy being taken.

The powerful spring mechanism of the BARD Magnum^{TM} biopsy instrument is vital to the technical reliability of the device, however, when the device is 'fired' the instrument produces a sudden noise akin to the sound of a stapler, although slightly louder. The noise produced by the biopsy device, very close to the ear of the participant undergoing a biopsy was of more concern to the participants than any physical discomfort few to the sudden

nature of the sound. Demonstration of the sound made by the biopsy instrument prior to taking the tissue sampled gave the participants an expectation of what would happen and resulted in the process being well tolerated.

During the development of the biopsy method there were no adverse events caused by the biopsy process and participants described a feeling similar to that after having a 'flu vaccination for a few days following the biopsy. On follow up review over the telephone and in clinic a number of weeks post-biopsy participants expressed satisfaction with the biopsy technique and those involved in the serial biopsy cohort detailed in chapter 7 were happy to have a second biopsy taken at their follow up visit.

The supraspinatus tendons of participants who underwent biopsy in the operating theatre could be examined in detail via arthroscope and, unless the arthroscope was being used simultaneously to monitor passage of the biopsy needle, it was not usually possible to identify the site of biopsy within the tendon immediately after the needle had been removed and the arthroscope inserted. Several individuals involved in the study who had biopsies around the time of a glucocorticoid injection for rotator cuff tendinopathy ultimately failed to improve sufficiently with the course of conservative treatment given and underwent surgical intervention. These arthroscopic procedures occurred at around three months post-biopsy and, on detailed examination of the supraspinatus tendon, it was not possible to identify a biopsy site within the tendon and none of these individuals had a significant partial thickness or full thickness tear of the rotator cuff tendons.

5.3 Application of Biopsy Method

The stages of development detailed above describe the logical, stepwise process by which this biopsy technique has been conceived, refined and validated. It has been shown to be a safe, well tolerated method that can provide accurate and reliable sampling of a clinically relevant area of the human supraspinatus tendon in a clinic and operating theatre setting.

This ultrasound guided rotator cuff sampling technique has now provided a means by which tissue research into the onset, progress and response to treatment for rotator cuff tendinopathy can take a significant step forwards. The technique offers the opportunity to sample tendon tissue from all stages of the pathological process, including tissue from 'normal', asymptomatic individuals and to take tissue samples before and after a treatment intervention to investigate the tissue response the the intervention administered. Such tissue research may facilitate the a greater understanding of rotator cuff tendinopathy and offer a means of evaluating existing and novel therapies to treat the condition.

Chapter 6

Immunohistochemical Changes Associated with the Progression of Rotator Cuff Pathology

6.1 Introduction

Rotator cuff tendinopathy represents the major cause of shoulder pain in the adult population and is the third commonest musculoskeletal presentation seen in primary care.[1,8] Despite its prevalence, the aetiology and progression of rotator cuff tendinopathy at a tissue level are poorly understood.

Clinically, patients may present at the early stages of disease with shoulder pain of idiopathic onset, typical examination findings and structurally normal rotator cuff tendons on MRI or ultrasound imaging.[13,14,95] The con-

dition may progress to partial and, ultimately, full thickness tearing of the tendon; this usually begins on the articular side of the supraspinatus tendon and can lead to the detachment of the tendon from its entheseal insertion into the greater tuberosity of the humerus. Progressive enlargement of a tear may extend through the full width of this tendon, into the infraspinatus and eventually the teres minor tendon and can lead to worsening pain and loss of function from the shoulder.[14]

The treatments for rotator cuff pathology are diverse in terms of the modalities employed, and there is very little good quality evidence to support the application of any current interventions used.[71] Patients with rotator cuff tendinopathy may pass through stages of conservative treatments such as glucocorticoid injections into the subacromial bursa and physiotherapy before progressing to surgical intervention should these treatments fail to resolve their symptoms; surgical intervention usually includes arthroscopic subacromial decompression and may include arthroscopic or open rotator cuff repair in the presence of a full thickness tear.[13,14] These stages of treatment, from injection of glucocorticoid, through subacromial decompression to rotator cuff repair represent progression through the clinical stages of rotator cuff tendinopathy, from macroscopically intact rotator cuff tendons to those with a full thickness tear, which represent the end stage of the tendinopathic condition.

There are many studies published with the aim of characterising tissue changes associated with rotator cuff tendinopathy, as discussed in the introduction to chapter 5.[30] However, each of these works demonstrate limitations in the type of tissue samples being studied, the accuracy with which the phe-

notype of the tissue donors is defined and the sampling methods used.

In order to represent the entire spectrum of rotator cuff tendinopathy a number of well phenotyped cohorts must be defined. The use of tear size as a measure of disease stage is unhelpful for the majority of individuals with rotator cuff tendinopathy, as full thickness tears of the tendon represent the terminal end of the spectrum of pathology. Without an understanding of the tissue changes associated with the onset and early progression of tendinopathy or means by which to assess this using current imaging, a clinical definition of stage of disease is required. The stepwise manner in which patients with rotator cuff tendinopathy progress through conservative to surgical interventions, combined with the presence or absence of a full thickness rotator cuff tear can be used to define a number of disease stages from normal, healthy individuals to those with full thickness rotator cuff tears.

The aim of this study was to utilise the sampling method described in chapter 5 to obtain well phenotyped and topographically defined supraspinatus tendon biopsies to identify histological and immunohistochemical biomarkers of rotator cuff tendinopathy across the whole spectrum of pathology, from normal controls to tendon that has structurally failed.

6.2 Method

6.2.1 Participants and Tissue Sampling

Ethical approval for the study was granted by the local research ethics committee (Oxfordshire REC B, ref: 09/H0605/111 and Oxfordshire REC C, refs: 10/H0606/60 and 09/H0606/11). Participants were recruited from patients under the care of the shoulder team at a specialist orthopaedic hospital. Each participant underwent tissue biopsy of the rotator cuff and collection of demographic and clinical data.

Samples of supraspinatus tendon were collected using an ultrasound guided core biopsy technique as described in chapter 5 using a 14 gauge (G) BARD Magnum™ biopsy instrument and a GE Healthcare Logiq E9® ultrasound machine with a linear transducer (ML6-15-D, frequency range 4-13MHz). The supraspinatus tendon was sampled from a consistent location, in a longitudinal plane, 5 to 10mm posterior to the anterior edge of the tendon as close to the footprint insertion of the tendon into the greater tuberosity as was possible (see chapter 5, figure 5.9d). Biopsies were taken in a clinic setting under local anaesthetic from participants undergoing conservative treatment and in the operating theatre from participants undergoing surgical interventions. In each setting participants were positioned in the same manner and the biopsies were taken using the same method.

Participants were recruited into four discrete groups in order to represent the full spectrum of rotator cuff tendinopathy:

1. Control group: Individuals with no history of rotator cuff tendinopathy.

2. Glucocorticoid Injection (GCI) group: Patients with rotator cuff tendinopathy without a full thickness thickness tear, undergoing an injection of glucocorticoid into the subacromial bursa.

3. Subacromial decompression (SAD) group: individuals with rotator cuff tendinopathy without a full thickness tear, who had failed conservative therapy and were undergoing arthroscopic subacromial decompression surgery.

4. Full thickness rotator cuff tear (FTT) group: individuals with rotator cuff tendinopathy and a full thickness rotator cuff tear.

The control group were recruited from young patients, under 35 years of age, who were undergoing anterior stabilisation surgery for traumatic shoulder dislocation. They had no history of rotator cuff tendinopathy and no evidence of structural damage to the rotator cuff on preoperative imaging or on arthroscopic assessment at the time of surgery. All participants had sustained anterior shoulder dislocation in the past and were undergoing surgery on an elective basis without dislocation in the previous two months, with shoulders in a quiescent state. All participants had type 1 shoulder instability without history or signs of connective tissue disorders or joint laxity.[178]

The disease groups were recruited from patients being treated for rotator cuff tendinopathy. All participants had subacromial impingement pain elucidated through history and examination findings including 'painful arc', positive Hawkins' and Jobe's tests.[16–18] The participants underwent an ultrasound scan of their affected shoulder during initial assessment and were categorised using a combination of the treatment modality they were due to

receive and the structural integrity of their rotator cuff tendons.

The GCI group were patients who were being treated for rotator cuff tendinopathy. They were all aged 35 years and over, did not have evidence of a full thickness rotator cuff tear on ultrasound, may or may not have had physiotherapy treatment and were due to receive an injection of glucocorticoid into the subacromial bursa. Individuals may have had previous injections of glucocorticoid into the bursa, although an injection within six weeks of the biopsy was an exclusion criterion. All biopsies were taken immediately prior to the injection of glucocorticoid to ensure that the tissue sampled was not affected by the glucocorticoid to be administered.

The SAD group shared the same characteristics as the GCI group although had unresolved symptoms despite conservative therapy of glucocorticoid injections with or without physiotherapy and were due to undergo subacromial decompression surgery. In this group the tendon biopsies were taken in the operating theatre prior to commencing the operation.

The FTT group were patients aged 35 years and over, with a full thickness tear of the rotator cuff who were due to undergo surgical repair. In this group, the area of interest for tissue sampling (5 to 10mm posterior to the anterior edge of the supraspinatus tendon) was encompassed by the boundaries of the full thickness tear and had retracted proximally. In these cases, the tissue biopsy was taken from the same location as for the intact tendons, although the sample was taken once the tendon repair was complete and the tendon integrity restored. This avoided sampling the edge of the tendon that was resected as part of the surgical repair, as has been done in previous studies; this provided a sample of the tendon tissue that would be required to 'heal'

back onto the greater tuberosity in order for the surgical repair to remain intact.

Participants were excluded from the GCI, SAD and FTT groups if they had a history of significant trauma to the affected shoulder, previous or current shoulder problems other than rotator cuff tendinopathy, previous shoulder surgery, a history of systemic steroid use, local glucocorticoid injections in the last six weeks, history of tobacco smoking or a significant systemic medical condition such as diabetes or rheumatological condition.

In addition to the tissue samples, demographic data regarding age, sex, occupation, hand dominance and activity level were recorded along with clinical data and stored securely, under password protection, in a database generated using FileMaker® Pro Advanced v11 (Filemaker Inc., Santa Clara, California, USA). All of the tissue samples and slides generated from the samples were labelled and catalogued using a Pro-Curo sample database (Pro-Curo Software Ltd., Horsham, UK) in accordance with the requirements of the Human Tissue Act 2004.[179]

6.2.2 Tissue Processing and Staining

The core biopsy samples obtained using the 14G BARD Magnum™ biopsy instrument were of consistently high quality; they were similar to a piece of long-grain white rice in both size and appearance. Once taken, the biopsy samples were immediately placed into a solution of 10% buffered formalin and embedded in paraffin as detailed in appendix B.

Each sample was allocated a randomly generated number and logged into

the FileMaker® database. The allocation of random numbers to the tissue samples allowed all further processing and tissue analysis to be undertaken in a blinded manner to eliminate the potential for bias at any stage of the processing, staining, microscopy or image analysis pathway.

The core biopsy samples were sectioned longitudinally to produce 3μm sections; these were mounted on glass slides as detailed in appendix B.

Histological and immunohistochemical staining of the slides was undertaken to evaluate a number of tissue characteristics. The characteristics investigated were selected as they had previously been shown to be altered in tissue from torn rotator cuff tendons.[48,60] The immunological assays used had all been successfully employed to stain tendon tissue for histological analysis and included markers of cellularity, vascularity, inflammation, cellular proliferation and apoptosis. The following stains and immunohistochemical assays were carried out; the methods used are detailed in appendix B:

- Haematoxilin and Eosin (H&E). The stain was used to assess the quality of the biopsy sample taken and clearly identify the nuclei within the tissue in order to permit a nucleic count as a marker of cellularity.
- CD34, vascular endothelial antigen. This marker was used to identify vascular tissue within the samples.[180]
- CD45, leucocyte common antigen. This marker was used to identify white cells within the tissue samples as a measure of inflammatory cell infiltration.[181–183]
- MIB-1 (anti-Ki-67 antibody). This marker was used to identify cellular proliferation.[184,185]

- Active Caspase-3 (AC-3). This marker was used to identify cells undergoing apoptosis.[186]

Slides were stained in batches of a single stain or immunohistochemical assay in order to minimise variability between sections. Each batch included a positive tissue control slide to confirm successful tissue staining. The control slides for each stain were taken from a single block of control tissue and collected as adjacent 3μm sections.

6.2.3 Microscopy and Image Capture

Microscopy and image capture of all sections was performed using the same method for all stains to ensure consistency of image generation. Microscopy was undertaken using a Zeiss Axio Imager M1 light microscope with an AxioCam HRc 13-megapixel digital camera (Carl Zeiss MicroImaging GmbH, Göttingen, Germany).

Light microscopy was conducted in brightfield mode, at a constant brightness level, using 100x optical magnification of the sections. This level of magnification allowed imaging of a significant proportion of the tissue sample with a single field of view. This facilitated assessment of a larger area of tissue per section than was possible in previous studies that randomly selected a number of high powered fields of view (400x magnification) to represent the whole sample.[48,60]

Digital images were captured from the AxioCam HRc camera mounted on the Zeiss Axio Imager M1 microscope using AxioVision Imaging System Software version 4·8 (Carl Zeiss MicroImaging GmbH, Göttingen, Germany).

Automatic white balance settings were used and images were taken at a resolution of 4164 x 3120 pixels. Images were saved as 24-bit RGB colour tagged image file format (TIFF) without compression; the TIFF files saved were around 40 megabytes in size.

The high resolution of the AxioCam digital camera (4164 x 3120 pixels) resulted in a single pixel of a 100x magnification image to cover a region of 0·34μm x 0·34μm, which represented an area of tissue 0·1156μm^2. A selection of ten of the smallest nuclei were identified in the tissue using high powered, 400x magnification, fields of view; the average area covered by each of these nuclei was 2·9μm^2. This meant that even the smallest nuclei within the tissue were represented by at least 25 pixels within the digital image, confirming that a magnification level of 100x and digital camera resolution of 4164 x 3120 pixels offered sufficient detail to identify and evaluate the relevant tissue structures.

A TIFF image from each slide was saved with the unique sample number of the slide as the filename, thus permitting accurate tracking of the sample whilst preventing the researcher from identifying the source of the tissue sample without referring to the key database. The images were saved into collections organised by the type of tissue stain used and stored digitally.

The H&E sections were imaged first and sheets of thumbnail images were produced showing the orientation of each of the sections. The thumbnail reference sheets were used to guide the microscopy of the remaining slides and provide consistency in the area of the tissue sample imaged.

6.2.4 Image Analysis

The images stored from each of the slides were analysed in a quantitative manner to compare the proportion of positively stained tissue between samples for each immunohistochemical marker assay and, in the case of the H&E stained slides, to calculate the cellularity of the tissue by measuring nucleic count by area.

Analysis of the digital images required two major processing steps: firstly, to isolate the area of tendon tissue present within the digital image and secondly, to calculate the proportion of the tissue that was positively stained or the nucleic count within the area of tissue. Each directory of images was analysed as a discrete group.

Calculation of Total Tissue Area

The first step was completed using Adobe® Photoshop® CS3 Software (Adobe Systems Incorporated, San Jose, California, USA). The aim of this step was to identify area from the image that did not show tissue (the background white light) and replace this area with pure white pixels which could then be excluded from future calculations.

The first stage was to 'clean' the images. Each image was opened and areas of dirt, damage or significant artefact on the image were removed using the 'eraser' tool.

A single image was then opened and the 'Select → Colour Range' command was used to define a range of colours that accurately represented the tissue within the image, without selecting the background. The colour range

was saved and the following steps were recorded as a 'new action' within the 'Actions' window:

- 'Select → Colour Range': the saved colour range was used to select the tissue area within the image.
- 'Layer → New → Layer via Copy': a new layer was created from the selection.
- The original 'Background' layer was deleted.
- 'File → Save As': the file was saved as a TIFF file without layers and without compression.
- The file was closed.

The 'File → Automate → Batch' command was then used to run the above actions on every digital image within a directory, saving time and ensuring consistency within image processing. The result of the process was a new directory containing TIFF files within which the non-tissue area of the images had been replaced with pure white pixels.

Area quantification and counting within the images was carried out using Fiji image analysis software (ImageJA version 1·45k).[187] Edited images from the previous step were used. To calculate the area of tissue within the image, the pure white background identified from the previous step had to be excluded. This was achieved using the following steps with the Fiji software:

- Image opened in Fiji.
- 'Analyse → Set Scale': the scale was set to 1 pixel width = 0·34μm.

- 'Image → Type → 8-bit': used to convert the image to a grayscale image.
- 'Image → Adjust → Threshold': brightness threshold was set as 0–244 (this excluded all pure white pixels, which have a brightness value of 255, the maximum value). The 'Apply' button was clicked.
- 'Analyse → Analyse Particles': this function was set to include particles of size 0–infinity and circularity 0–1. The 'summarise' box was checked and 'OK' clicked. The results of the calculations were displayed in units of μm^2 within the results box.
- The file was closed.

Figure 6.1b shows the image result of masking the total tissue area within the image. The steps to achieve this were recorded as a macro using the 'Plugins → Macros → Record' command. The macro was then used to automate the calculation of tissue area from all images in a directory using the 'Process → Batch → Macro' command. Once the process was complete, the results window included the area values for each image along with the filename. These data were saved as a spreadsheet using Microsoft® Excel® software (Microsoft Corporation, Redmond, Washington, USA), then imported into the FileMaker® database.

Identification and Quantification of Positively Stained Tissue

The next step for the immunohistochemical assays was to calculate the area of tissue within each image that was positively stained. This required the

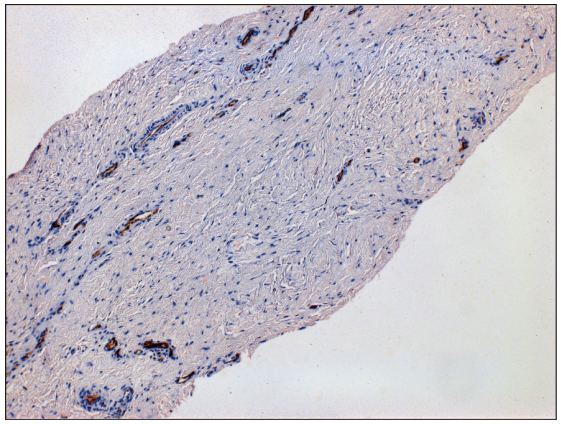

(a) Original Image



(b) Mask of total tissue area



(c) Mask of positively stained tissue

Figure 6.1: Image analysis: masks of the total tissue area and positively stained tissue within a slide image of tissue stained with a CD34 immunohistochemical marker (magnification 100x).

imaging software to be able to distinguish between the background tissue and the positively stained tissue, which was undertaken using a colour threshold tool. Colour thresholding permitted the selection of pixels within an image that fell within a predefined range of colours across the digital spectrum. Using a RGB colour profile, each pixel is made from a proportion of red, green and blues hues. By engineering the positively stained tissue to be of a sufficiently different colour to the background, negatively stained tissue, the two regions could be clearly distinguished using the Fiji software.

The Dako REAL^{TM} EnVision^{TM} Kit (Dako UK Ltd., Ely, United Kingdom) used to detect the target antibodies applied to the tissue (e.g. CD34, CD45, MIB-1, AC-3) stained the section brown in the areas of interest. The background tissue was counterstained with Mayer's haematoxilin, which was 'blued' in 2% sodium hydrogen carbonate (see Appendix B). To ensure the background tissues were blue, rather than the original pink-red of the haematoxilin stain, the slides were immersed in the sodium hydrogen carbonate solution for 20 seconds, rather than the usual 3 to 5 seconds. This process removed the red hue component from the background tissue colour making the differentiation between positively and negatively stained tissue clearer on the digital images.

The colour thresholding process was carried out using the following steps in the Fiji imaging software:

- Image opened in Fiji.
- 'Analyse → Set Scale': the scale was set to 1 pixel width = 0·34μm.
- 'Image → Adjust → Colour Threshold': RGB colour space was selected

and the sliders used to 'pass' all red and green hues (pass 0–255) and reject all blue hues (pass 0–0). This selected only the positively stained (brown) tissue and exclude the background (pure white) and negatively stained (blue) tissue.

- 'Analyse → Analyse Particles': this function was set to include particles of size 0–infinity and circularity 0–1. The 'summarise' box was checked and 'OK' clicked. The results of the calculations were displayed in units of μm^2 within the results box.

- The file was closed.

Figure 6.1c shows the image result of masking the positively stained tissue within the image. As was done for the total tissue area calculation, these steps were recorded as a macro using the 'Plugins → Macros → Record' command. The macro was then used to automate the calculation of tissue area from all images in a directory using the 'Process → Batch → Macro' command. Once the process was complete, the results window included the area values for each image along with the filename. These data were then saved as an Excel® spreadsheet, then imported to the FileMaker® database.

Nucleic Counting

The H&E slides were used to determine the cellularity of each section by performing a nucleic count. Using 100x magnification, each section included up to 1500–2000 nuclei in a single image, making manual counting unfeasible. An automated method for counting nuclei on this scale permitted the evaluation of a much larger area of tissue than would be possible manually,

saved a great deal of time and was consistently reproducible. In order to validate the computerised counting method, a comparison was made against a standard manual counting method.

Ten images of the H&E slides at 100x magnification were selected to represent a wide range of cellularity within the sample from near acellular to the most cellular. From each of these images a region equivalent to the area of tissue covered by a 400x magnification field of view was selected. A set of ten images labelled A–J were printed using a high resolution colour laser jet printer. Eight observers were given their own set of images and asked to count the number of discrete, darkly stained purple nuclei within each image, marking the sheet as they wished. Counting was performed individually, without conference between observers. After two weeks, in order to minimise any recollection of the first count, the same eight observers were presented with a second copy of the same images and asked to count the nuclei once again in the same manner. The two human counts could then be assessed for inter- and intra-observer agreement to establish consistency of the human count and could also be compared with the computerised counting method.

The computerised method was undertaken using Fiji image analysis software. The same ten images that had been presented to the researchers for counting were analysed using the image analysis software in the following manner:

- Image opened in Fiji.
- 'Analyse → Set Scale': the scale was set to 1 pixel width = 0·34μm.
- 'Image → Adjust → Colour Threshold': HSB colour space was selected

and the sliders used to accept hues of 129–236, thereby selecting only purple hues and all saturation levels, 0–255, were accepted. The brightness threshold was then set using the 'Max Entropy' algorithm built into the colour threshold plug-in.

- 'Analyse → Analyse Particles': this function was set to include particles sized from $6\mu m^2$ to infinity and with a circularity 0–1. The 'summarise' box was checked and 'OK' clicked. The results of the calculations were displayed as a count of discrete areas (nuclei) within the image.

- The file was closed.

The 'Max Entropy' algorithm used in this process could not be incorporated into a macro. As a result this step of the image analysis was completed individually for each image. The size range of particles counted was given a lower level of $6\mu m^2$ to ensure that very small spots of dirt or artefact within the images were not counted as nuclei.

Figure 6.2 shows the image result of masking the nuclei within the image.

The results from the two human counts plus the computer count were imported into GraphPad Prism® software (GraphPad Software Inc., La Jolla, California, USA). Figure 6.3 shows the results for each of the ten images from the two human counts and the computer count.

Agreement between observers was evaluated by calculating intra-class correlation (ICC) coefficients for each count. The ICC coefficients were calculated as 0·9982 for human count 1 and 0·9936 for human count 2, demonstrating very high agreement between observers. Intra-observer agreement was calculated by comparing the first count with the second count for each

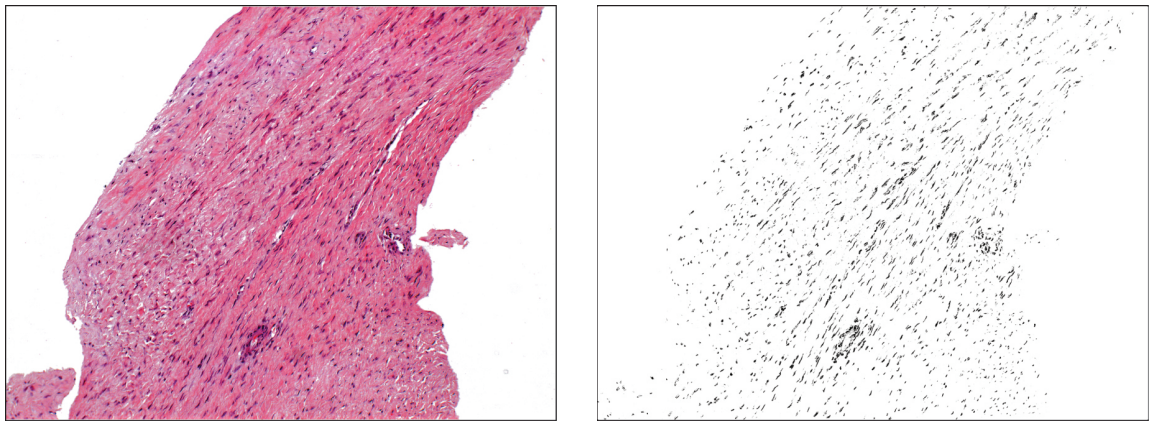

(a) Original Image (b) Mask of nuclei

Figure 6.2: Image analysis: mask of the nuclei within a slide image of tissue stained with haematoxilin and eosin (magnification 100x).

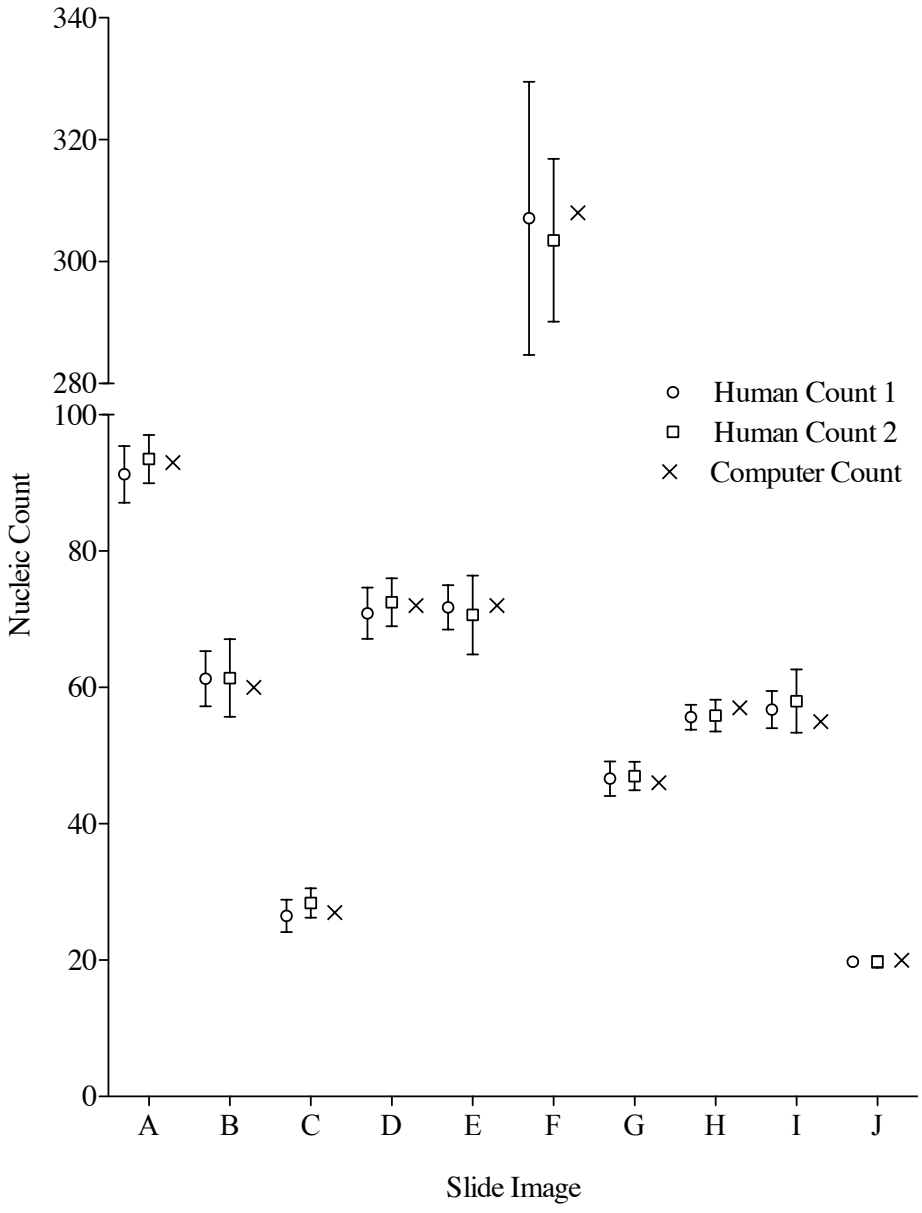

Figure 6.3: Nucleic counts for ten validation images (A–J). The human counts are displayed as the mean plus 95% confidence intervals for the group of researchers.

observer. The ICC coefficients for the observers ranged was 0·9977–0·9998, showing very high agreement from repeated nucleic counts by each observer.

The human counts for each image were compared against the computer count using a one sample t-test. There was no significant difference between any of the computer counts and the first or second human counts.

These data demonstrate the human counting method to be reliable between observers and repeatable by a single observer at different time points. The computerised counting method was shown to give statistically similar results to both human counts for each image.

The computerised nucleic counting method described above was used to analyse all of the H&E slides in the study. This permitted evaluation of the whole image, rather than a small area and produced consistent, reproducible results. The nucleic counts from each full sized H&E images were saved as an Excel® spreadsheet, then imported to the FileMaker® database.

Data Analysis

The FileMaker® database combined all of the data collected from the study including demographic information, clinical state and phenotyping of participants, details of the processing batch and paraffin blocks for each slide and the results from all aspects of the image analysis. Undertaking the data collection in this way allowed for every processing and analysis step to be completed in a blinded manner. The database also facilitated the efficient and accurate manipulation of data that could be easily exported to other software programs for statistical analysis.

Image analysis of each slide generated a 'total tissue area' value that was

recorded in the database. In addition, analysis of the immunohistochemical assays generated a 'positively stained tissue area' value and the H&E stain generated a 'nucleic count' for each slide in their respective groups. For the immunohistochemical assays, the positively stained and total tissue areas were used to calculate a proportion of tissue that was positively stained. For the H&E stain the nucleic count and total tissue are were used to calculate a measure of cellularity as nuclei per millimetre squared of tissue.

In order to account for any batch variation between this and future work, the results from the immunohistochemical assays were standardised against the control group (individuals under 35 years of age without any history of rotator cuff tendinopathy). The mean proportion of positively stained tissue in the control group was scaled to a value of '1·0' and all other results standardised to this scale. In this manner, the results from this study can be compared to future work, allowing for slight variations in equipment and methodology, provided future studies include a similar control group against which to standardise the results.

The results from each stain were exported from the FileMaker® database into an Excel® spreadsheet and analysed using GraphPad Prism® software. The data were separated into the four groups representing the stages of tendinopathy: control, GCI, SAD and FTT. The mean values for each stain from the latter three, tendinopathic, groups were individually compared to the control group using an unpaired t-test. The results were graphed using the GraphPad Prism® software.

6.3 Results

Eighty one participants were recruited to the study. Ten did not undergo core needle biopsy due to a number of reasons: five of the surgical patients were found to have concomitant or alternative diagnoses at surgery so were excluded, four biopsies were not undertaken due to logistical timing difficulties in clinic and theatre and one participant had an adverse reaction to the injection of local anaesthetic.

The remaining seventy one participants underwent core needle biopsy. One of these biopsies was found to be of insufficient quality to undergo evaluation, the participant from whom this biopsies had been obtained was excluded from the study.

The group breakdown and demographic details of the seventy participants from whom successful biopsies were sampled are detailed in table 6.1.

Figure 6.4 shows the age distribution within each group. The tendinopathic groups (GCI, SAD and FTT) were all significantly older than the control group and the FTT group was significantly older than the GCI and SAD groups.

Figure 6.5 shows the distribution of symptom duration within each group. There was no significant difference in symptom duration between any of the groups.

Figure 6.6 shows images from adjacent 3μm sections of a single biopsy sample that have been stained to define markers of cellularity, vascularity, inflammation, cell proliferation and cell apoptosis. Imaging the slides at 100x rather than a higher magnification permitted evaluation of a larger area of

Group	Number of Participants	Mean Age /years	♂ : ♀	Dominant Arm	Previous GCI	Mean Symptom Duration /months
Control	16	23·4 [18–29]	14 : 2	5/16	0/16	n/a
GCI	15	50·7 [35–64]	4 : 11	9/15	8/15	18·5 [6–48]
SAD	26	51·7 [36–69]	18 : 8	16/26	26/26	20·4 [9–60]
FTT	13	58·1 [35–63]	8 : 5	10/13	13/13	18·5 [12–24]
ranges given in square brackets						

Table 6.1: Breakdown and demographics of the groups to which the seventy successful biopsy participants in the study were recruited

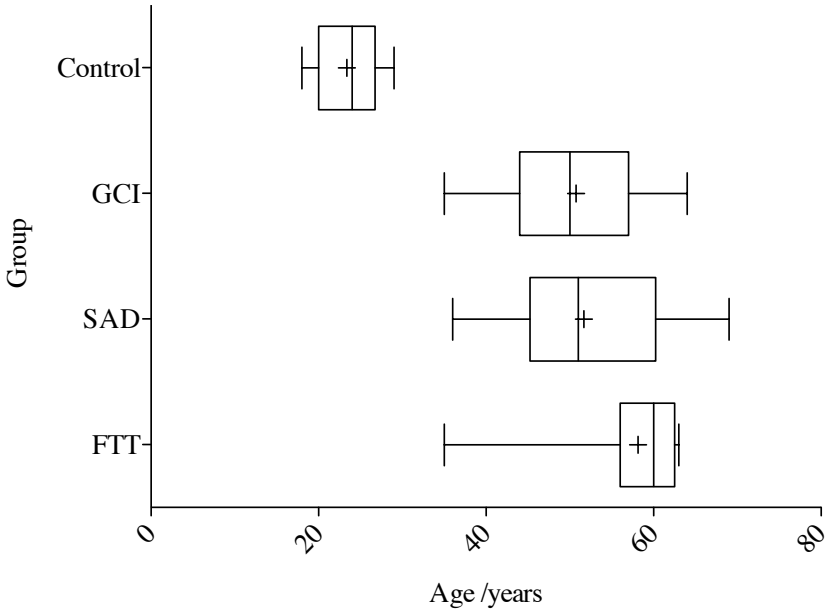

Figure 6.4: Box and whisker plots of age distribution within the study groups ('+' denotes mean age of group).

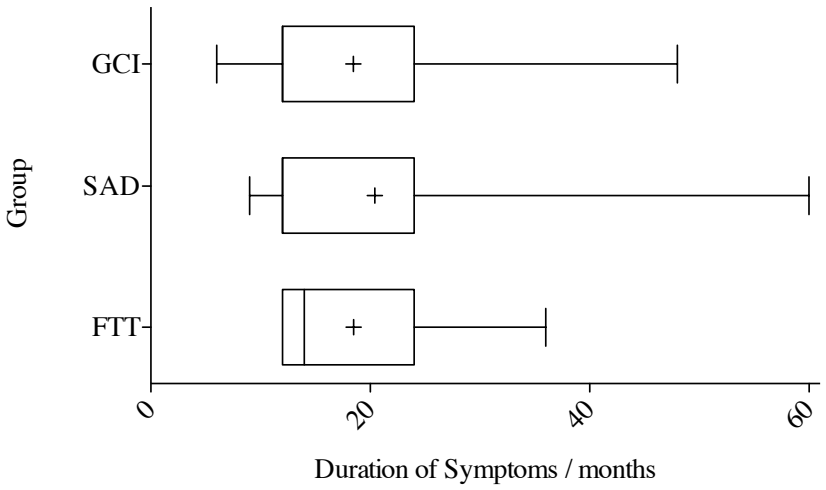

Figure 6.5: Box and whisker plots of symptom duration within the study groups ('+' denotes mean symptom duration of the group).

tissue, more representative of the whole sample and was particularly useful for the assays in which only tiny areas of the tissue were positively stained, such as the markers of proliferation and apoptosis where staining was limited to a few cells per section.

The data for cellularity, as measured by nucleic count, and expression of immunohistochemical markers for each group are displayed graphically in figures 6.7, 6.8, 6.9, 6.10 and 6.11.

The results do not show a significant change in cellularity across the spectrum of pathology although a rise in cellularity that nears significance is seen in the GCI group when compared to the control and a declining trend is also seen in the later tendinopathic stages (see figure 6.7).

Vascularity shows a declining trend after the early stage of pathology (GCI group), reaching significance, compared to the control group by the terminal end of the spectrum (see figure 6.8).

Tissue samples from the early stage of pathology (GCI group) show a significant increase in inflammatory cell infiltration compared to the control group; this does not persist in the two later stages of tendinopathy (see figure 6.9).

Proliferative activity within the tissue follows a similar patter to vascularity; a significant decline in proliferative activity is seen in the two later pathological groups (see figure 6.10).

Apoptotis (programmed cell death) shows a significantly elevated level in the GCI group compared to the control group which is not seen in the final two study groups, a similar pattern to that seen for inflammation in the tissue (see figure 6.11).

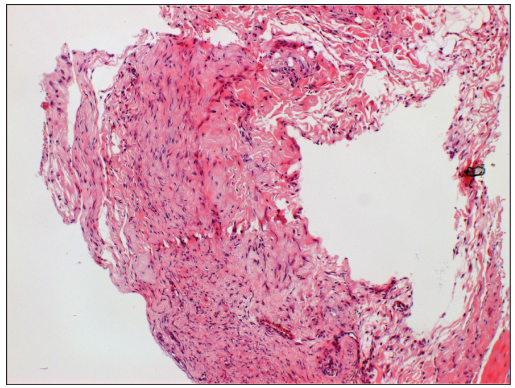

(a) H&E: Cellularity

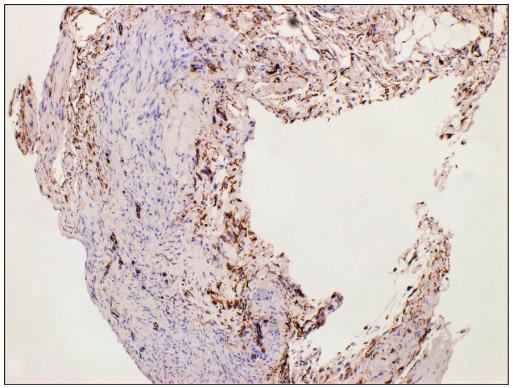

(b) CD34: Vascularity

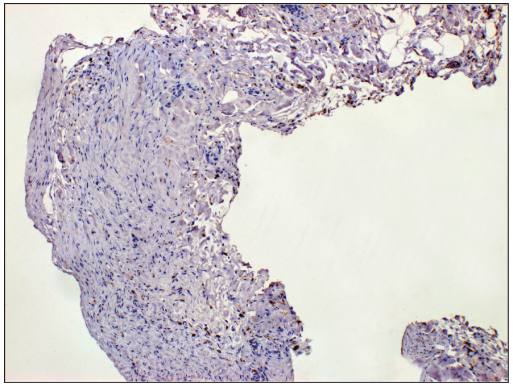

(c) CD45: Inflammation

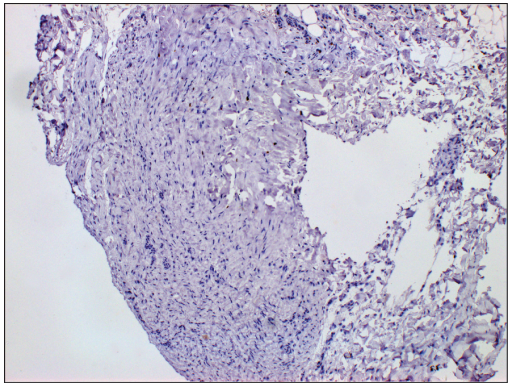

(d) MIB-1: Proliferation

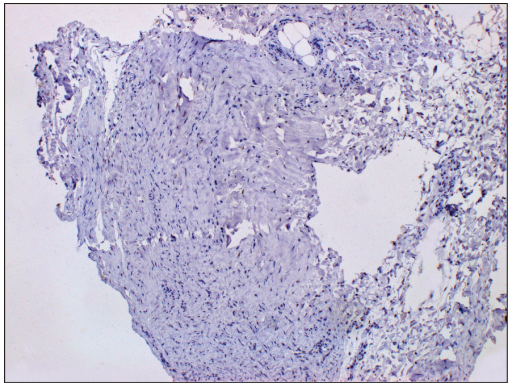

(e) Active Caspase-3: Apoptosis

Figure 6.6: Light micrographs showing adjacent 3μm sections from a single biopsy sample stained to identify markers of basic tissue characteristics (magnification 100x).

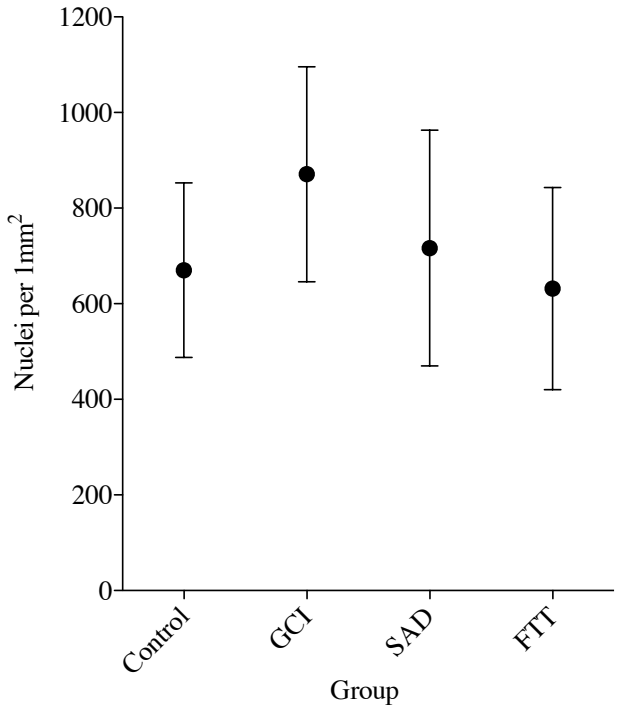

Figure 6.7: Cellularity, as measured by nucleic count, of tissue samples from each of the study groups.

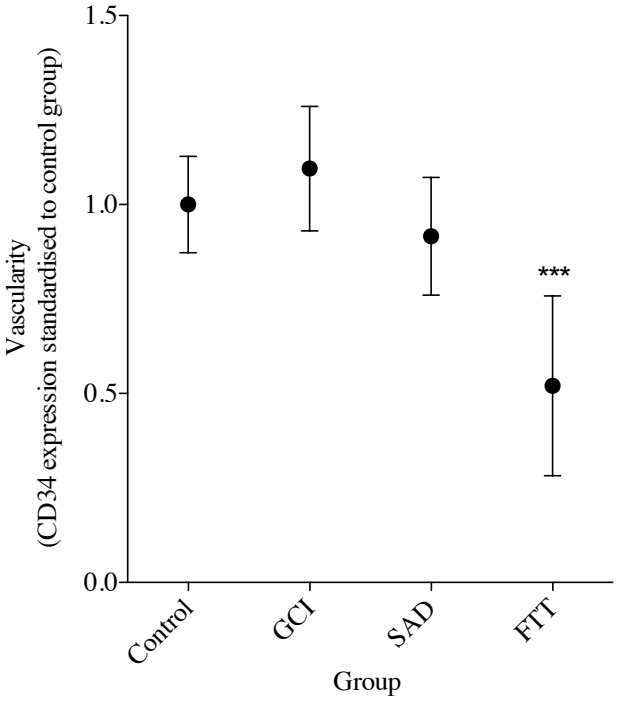

Figure 6.8: Vascularity, as measured by CD34 expression, of tissue samples from each of the study groups (*** denotes p<0·001 for unpaired t-test of mean versus control group mean).

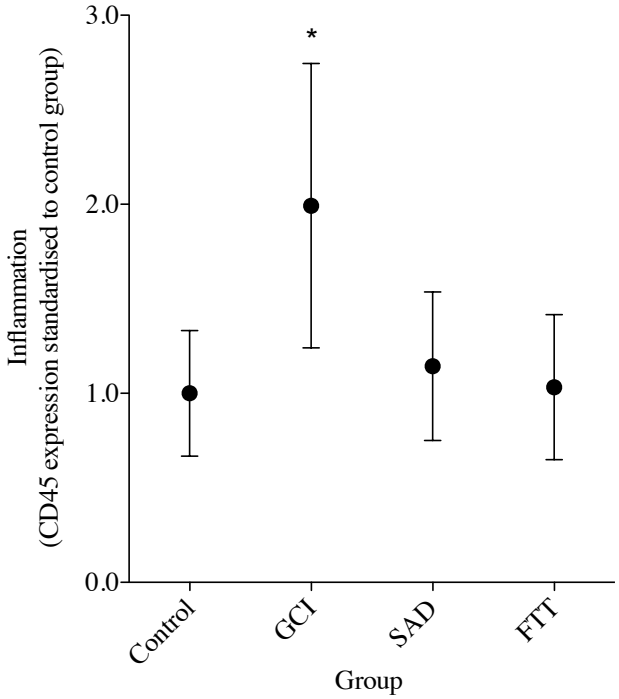

Figure 6.9: Inflammation, as measured by CD45 expression, of tissue samples from each of the study groups (* denotes p<0·05 for unpaired t-test of mean versus control group mean).

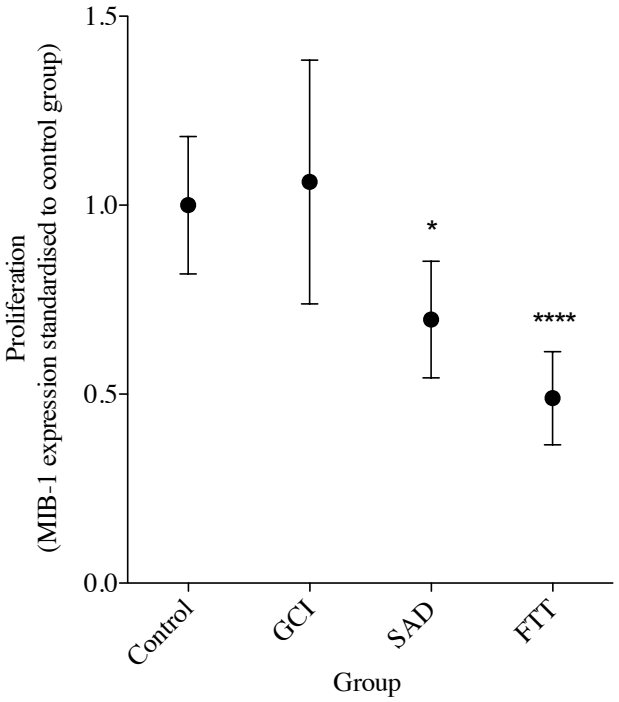

Figure 6.10: Proliferation, as measured by MIB-1 expression, of tissue samples from each of the study groups (* denotes p<0·05, **** denotes p<0·0001 for unpaired t-test of mean versus control group mean).

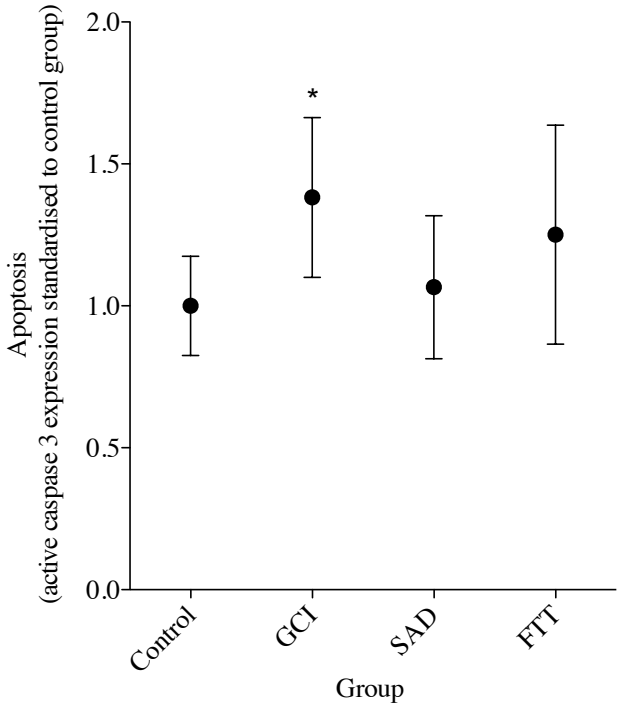

Figure 6.11: Apoptosis, as measured by active caspase-3 expression, of tissue samples from each of the study groups (* denotes $p<0{\cdot}05$ for unpaired t-test of mean versus control group mean).

6.4 Discussion

The principle findings from the results were that the supraspinatus tendon showed a decline in viability as it progressed through the spectrum of tendinopathy but that, in the early stages, there may be a reactive phase within the tendon characterised by an increase in inflammatory cell infiltration and cell turnover. This series of results is the first to describe a well phenotyped set of tissue samples, obtained in a topographically consistent manner from the primary area of failure within the supraspinatus tendon.

Comparison of this study to previous studies is difficult due to the heterogeneity of the participants and tissue samples investigated previously. Overall, the general description of reduced viability and failing tissue towards the end of the tendinopathic spectrum shown in this work mirrors the gross

findings shown in the existing literature.[45,60,151]

Cellularity was not shown to change significantly against the control group in this study although the GCI group showed an elevated nucleic count that approached significance. In the later stages of tendinopathy a declining trend in cellularity was noted, although not significant. Previous studies comparing tissue from full thickness tears of different size have shown a gradual decline in cellularity as tear size increases and degeneration increases.[60,67,147] Variation in cellularity of tendinopathic tissue, both increased and decreased, compared to control has also been described in the literature although the use of alternative tissue controls in previous studies makes comparison with this work invalid.[57,60,62]

Tendon vascularity was shown to trend towards a small increase from the control group to the GCI group, in a similar manner to cellularity of the tissue, with significant decline in vascularity in the later stages of the condition. Some existing studies have suggested an increase in vascularity in torn tendon compared to control, although the control tissue in these studies has been from the subscapularis tendon or from cadaveric tissue of undefined clinical status.[51,57] A decline in vascularity has also been shown previously from work looking at progression of tear size.[60] A very similar pattern of expression was seen with regard to proliferative activity in the tissue as a significant decline in the later stages of tendinopathy, a feature that has been previously described in tears of increasing size.[60]

Inflammatory cell infiltration was shown to be significantly higher in the GCI group than the control group. This is a group in whom no previous tissue work has been published, due to a lack of access to samples from this cohort.

Inflammation in tendinopathic conditions is of unproven significance, despite being a target for anti-inflammatory pharmacological agents.[67,147,188,189] No variation in inflammatory cell infiltration was seen at the other stages of tendinopathy.

Similarly to inflammatory cell infiltration, apoptotic activity in the tissue showed a significantly elevated level in the GCI group compared with the control group, although no significant change was seen at other stages of disease. It may be reasonable to consider these two features to be associated or even causative of one another. An increase in inflammatory cell infiltration within the tissue may lead to an increase in cell turnover and an elevation in the level of cellular apoptosis; the immune cells themselves may undergo apoptosis or cause native cells to sacrifice themselves in this way. Indeed, the reverse may also be true in that elevated levels of apoptosis within tendinopathic tissue may cause recruitment of immune cells to that location, thereby accounting for the elevated number of CD45 positive cells seen within these samples. The results for apoptosis within the tissue remain unclear in terms of a pattern across the spectrum of pathology, although most previous studies of apoptosis within tendinopathic rotator cuff tendons suggest an increased level of apoptosis compared to control.[48,59,67,69,146]

Overall, the pattern of change in tissue characteristics across the spectrum of disease remains unclear, although a certain degenerative, senescent and poorly viable condition appears to become more prevalent as the stage of tendinopathy progresses. this work has also suggested the possibility of a more active phase of pathology in the early stages of the condition that may be associated with increased programmed cell death and inflammation.

6.5 Limitations

This study has incorporated a number of novel features within the methods of sampling, processing and image analysis of the tissue samples studied and, as such, presents an array of limitations that must be taken into consideration.

As with all previous tissue work into rotator cuff tendinopathy, accurate phenotyping of participants prior to tissue sampling is vital in ensuring the validity of the results apportioned to a cohort of tissue samples. Defining disease stage using the presence or absence of a full thickness rotator cuff tear limits the analysis to comparison of the end stage of tendinopathy to all prior stages. In this study we have defined the earlier stages of pathology clinically by the treatment modalities being administered to the participants. In the NHS in the UK, patients progress through a strict and predictable course of treatment modalities as their condition progresses, or fails to respond to treatment. While this may seem a rather crude manner in which to segregate clinical groups, it is consistent in defining the treatment stage of the participant and, in the absence of a reliable biomarker of tendinopathic stage, serves to define progression for these cohorts. Future tissue or imaging biomarkers may help to define these groups more accurately.

Strict exclusion criteria were used in order to optimise the homogeneity of the study groups by excluding participants with shoulder-related, constitutional or environmental factors that may have a confounding effect on the results. While major systemic disease and exposure to systemic or recent local steroid preparations served as an exclusion criterion there were other factors that may have had an influence that could not be considered: previous

use of other pharmacological agents such as non-steroidal anti-inflammatory drugs was not included in the study dataset and detailed analysis of the physical activity levels of the participants was not possible due to the varied and non-validated nature of the responses to those questions when asked. Future work should aim to address these potential confounders by collating a more extensive dataset with documentation of validated measures where possible.

Age is of major significance with regard to the rotator cuff: young people do not present with rotator cuff tendinopathy, the most common presenting age being in the sixth decade of life, and young people do not suffer chronic rotator cuff tears, a finding that increases in prevalence with age.[3,36,208] It is not possible to identify which of the tissue characteristics studied here are affected by age, although the FTT group were shown to be significantly older than the previous two tendinopathic groups. Chapter 8 describes a study that attempts to address some of the tissue features that may be affected by age. In addition, the control group were made up of young healthy individuals and did not represent age-matched controls. This group was selected as a baseline tissue against which the other groups could be compared and also provided a logistically feasible source of control tissue for the study. Future work would benefit from cohorts of age-matched controls.

The core needle biopsy samples are extremely small and represent only a tiny region of the supraspinatus tendon. While this method is reproducible and consistently delivers samples from a known region of the tendon, it is not possible to infer what changes may be occurring within the tendon tissue millimetres from the biopsy site. It is not ethically justifiable, however, to resect large regions of tissue from an intact tendon. In future it would be

desirable to use this method to correlate tissue characteristics to an imaging biomarker that could then be used to investigate wider regions of the tendon tissue.

There were no adverse events associated with the tendon biopsy. Some participants described the biopsy as 'being punched in the arm' although the sensation was transient. A slightly sore deltoid, akin to the discomfort following a vaccination was described by some participants in the 2–3 days after the biopsy. One participant had an adverse reaction to the infiltration of local anaesthetic given although did not proceed to biopsy following this event.

The tissue processing of such small tendon samples represented a major challenge in terms of manipulation and quality of the sections that were generated. Some of the tissue sections showed damaged or folded regions that had to be excluded from the image analysis during the 'cleaning' stage of the image processing. The experience gained by the process of working with such small samples will help to improve the quality of tissue processing in future studies.

The histological and immunohistochemical investigation undertaken in this study has focussed primarily on cellular presence and activity, with little consideration for the extracellular components of the tissue. Rotator cuff tendon tissue predominantly consists of extracellular matrix proteins as a structural scaffold within which the tenocytes are distributed. The tissue is relatively acellular compared to many other body tissues and it is these extracellular components that form the functional structure of the tissue. Due to the constraints of time and expense, this study was limited to evaluation

of the features described, although future work could focus on the changes in extracellular matrix of the supraspinatus tendon as pathology progresses.

The image analysis process developed for this study offered a consistent and reproducible means of quantifying tissue characteristics by measuring the proportion of positively stained tissue within the microscopy images. The removal of all subjectivity from histological analysis of tissue samples may, however, limit the potential value of such analysis that can come from the interpretation of such images by an experienced histopathologist. Future quantitive tissue work may benefit from combining histological analysis with other avenues of tissue evaluation such as micro-RNA, proteomics, biochemical and mechanical evaluation.

6.6 Significance

In order to effectively treat the pain and loss of function associated with rotator cuff tendinopathy, a clear understanding of the underlying pathophysiology of the condition is required. Identification and mapping of tissue characteristics involved in the onset and progression of tendinopathic changes in the supraspinatus tendon, in particular, may give new insight into the reasons for pain and structural failure and aid in the development of future treatments.

A huge array of tissue work has been published regarding the pathological changes seen in the rotator cuff, although, as yet, no clear pattern of progression has been defined to describe the full spectrum of the condition.[30] This lack of clarity from such a body of work has been driven by limitations

in the methodology of previous studies, most noticeably as a result of the type, site and phenotypic description of the tissue samples being studied. The majority of these studies focussed on the terminal end of the tendinopathy spectrum, simply because this clinical time point offered a means of access to the torn edge of the supraspinatus tendon during rotator cuff repair; these tissues were then compared against control tissues of unproven validity.[41–46,48–65,65–69,146–148]

This study has demonstrated the potential for using a minimally invasive sampling technique to deliver consistent, accurately sourced samples of rotator cuff tendon tissue which, in combination with accurate phenotypic data, can be used to more thoroughly describe the full spectrum of rotator cuff tendinopathy. For the first time, this study has compared topographically matched control and diseased samples of supraspinatus tendon from the primary site of pathology in well phenotyped individuals. The study has shed some light onto the early stages of the process and suggested the possibility of a reactive phase from the tendon before a gradual decline in viability and progression to senescence within the tendon tissue.

Adopting this methodology will offer greater significance and validity to tissue work into rotator cuff tendinopathy by providing a consistent and reproducible method that will permit direct comparison between future studies.

Chapter 7

Short Term Tissue Response to Current Treatments for Rotator Cuff Tendinopathy

7.1 Introduction

As the major cause of shoulder pain presenting to healthcare providers, rotator cuff tendinopathy represents a significant target for the development of effective treatments in musculoskeletal medicine.[1] The clinical and macroscopic spectrum of pathology commonly begins with characteristic shoulder pain on activity in the absence of a gross change in tendon structure and can progress to a stage characterised by pain, loss of function and structural failure of the rotator cuff tendons, starting with the supraspinatus.[13,14] The myriad interventions employed in the treatment of each stage extend from simple analgesic measures, through physiotherapy and locally injected

glucocorticoids to surgical interventions such as subacromial decompression and surgical repair of the torn rotator cuff; there is very little good quality evidence to support the efficacy of any of these therapies.[71] A limited understanding of the progressive pathophysiology of rotator cuff tendinopathy has hampered the development of novel therapies for the condition and permitted adoption of treatments that have unproven worth and may even be harmful to the tendons in the longer term.

Evaluation of current and past therapies for rotator cuff tendinopathy has been limited by factors including heterogeneity of sample populations, poor quality or inappropriate outcome measures and a lack of robust methodology within the literature.[71,190–193] Failure to understand the condition at a tissue level has forced surrogate markers of pathology to be used as a means of classifying stage of progression, resulting in a great deal of individual variation within experimental cohorts. This heterogeneity has a significant impact upon the relative power of the studies and limits the value of the outcome measures used.

A lack of access to tissue samples in clinical trials limits the choice of outcome measures most commonly to those recording symptom relief, physician rated measures of function and imaging assessments of tendon repair integrity, none of which provide a detailed insight into the effects of the therapies used on the biological condition of the tendon at the root of the condition.[71,190–193]

Despite the array of treatment modalities employed for rotator cuff tendinopathy, subacromial bursal injection of glucocorticoid (GCI), physiotherapy, arthroscopic subacromial decompression (SAD) and rotator cuff repair (RCR)

are the most commonly used in secondary care.[13,14] The first three of these interventions (GCI, physiotherapy and SAD), are the mainstay of treatment for patients without a full thickness tear of the rotator cuff and, although also employed in the management of full thickness tears, this group of individuals may also be treated with surgical repair (RCR). There are no studies evaluating the in-vivo response of the rotator cuff tendons at a microscopic or biological level to any of these treatments. The most comprehensive analysis of tissue outcome employed has been the evaluation of tendon integrity following RCR with ultrasound or magnetic resonance imaging.[194–196]

In consideration of the logistical and repeatable nature of the methodology required to evaluate these treatment modalities, GCI, SAD and RCR offer the most control over variables in treatment administration. Little consensus exists with regard to what regimen should constitute a physiotherapy treatment for rotator cuff tendinopathy in terms of type of exercise, duration of treatment and tailoring of theory to a particular individual.[190,197] As such, the lack of clarity with regard to physiotherapy interventions renders assessment of the tissue response to a single, arbitrarily chosen regimen limited. On the contrary, GCI, SAD and RCR represent interventions that are controlled by the administering clinician, can be standardised to be delivered in a reproducible manner and differ minimally from one clinical centre to the next in terms of technique. Investigation into the effects of these treatments on the rotator cuff would offer a significant step forward in evaluating the efficacy of these modalities and may offer insight into the development of novel therapies.

The aim of this study was to investigate the short term tissue response

of the supraspinatus tendon to GCI, SAD and RCR as current interventions for rotator cuff tendinopathy by evaluating a number of tissue characteristics before and after treatment.

7.2 Methods

Ethical approval for the study was granted by the local research ethics committee (Oxfordshire REC B, ref: 09/H0605/111). Participants were recruited from patients under the care of the shoulder team at a specialist orthopaedic hospital.

The participants were undergoing treatment for rotator cuff tendinopathy; each had subacromial impingement pain elucidated through history and examination findings including 'painful arc', positive Hawkins' and Jobe's tests.[16–18] Participants underwent an ultrasound scan of their affected shoulder during initial assessment and the structural integrity of their rotator cuff tendons was recorded. They were each due to receive one of three interventions: GCI, SAD or RCR. The study was purely observational and recruitment was undertaken after a clinical decision to proceed with a specific treatment intervention had taken place.

Participants were excluded if they had a history of significant trauma to the affected shoulder, previous or current shoulder problems other than rotator cuff tendinopathy, previous shoulder surgery, a history of systemic steroid use, local glucocorticoid injections in the last six weeks, history of tobacco smoking or a significant systemic medical condition such as diabetes or rheumatological condition.

Individuals were recruited to the study in the following groups:

1. Glucocorticoid Injection (GCI) group: Patients with rotator cuff tendinopathy without a full thickness thickness tear, undergoing an injection of glucocorticoid into the subacromial bursa (40mg Depo-Medrone in 1ml with 4ml 1% lidocaine).

2. Subacromial Decompression (SAD) group: individuals with rotator cuff tendinopathy without a full thickness tear, who had failed conservative therapy and were undergoing arthroscopic subacromial decompression surgery.

3. Rotator Cuff Repair (RCR) group: individuals with rotator cuff tendinopathy and a full thickness rotator cuff tear, who were undergoing rotator cuff repair surgery.

Each participant underwent tissue biopsy of the rotator cuff on the day of their intervention prior to receiving treatment and again during their follow up appointment in the outpatient clinic seven weeks later. Collection of demographic and clinical data was undertaken at the first visit including an Oxford Shoulder Score as a patient reported measure of pain and function in the shoulder, this score was repeated at the post-treatment visit.[198] The score was used in its revised configuration with zero as the minimum and 48 as the maximum score. All data collected was stored anonymously in a FileMaker® database.

Samples of the supraspinatus tendon were collected using an ultrasound guided core biopsy technique as described in chapter 6. Biopsies were taken

in a clinic setting under local anaesthetic from participants undergoing non-surgical interventions and in the operating theatre from participants undergoing surgical interventions.

Tissue samples taken during rotator cuff repair surgery in previous studies sampled the granulomatous torn edge of the tendon which was resected as part of the surgery.[41–46,48–70] This tissue is unlikely to be representative of the remainder of the tendon tissue and, as it is discarded, does not represent the tendon edge that will be expected to 'heal' back onto the tuberosity postoperatively. In order to avoid this problem and to ensure that pre- and post-repair tissue samples were obtained from the same location, the intraoperative tissue biopsies for the RCR group were taken once the repair was complete. In this manner, the same ultrasound image could be visualised intraoperatively and at the time of follow up tissue biopsy to ensure consistency and reliability of sampling. Figure 7.1 shows the plane in which the needle was used to sample the supraspinatus tendon following repair.

All post-treatment biopsies were taken in a clinic setting. At each time point, participants were positioned in the same manner and the biopsies were taken using the same method.

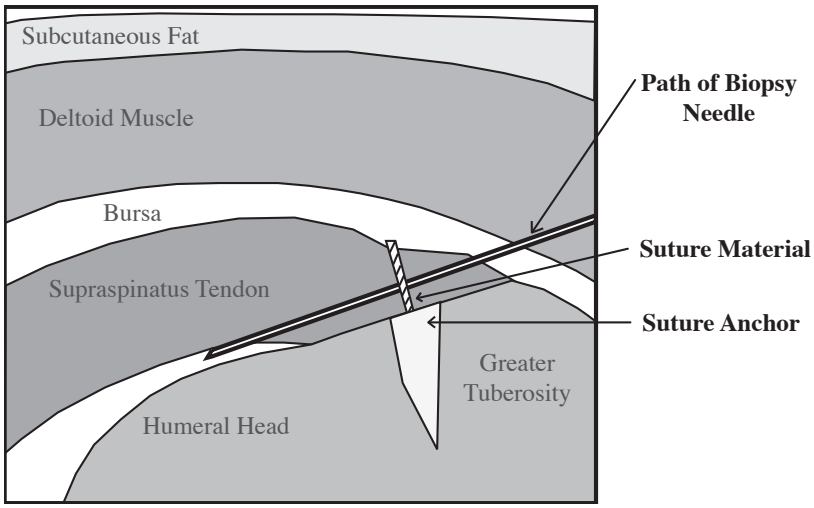

Figure 7.1: Diagram of intraoperative biopsy plane in the rotator cuff repair group.

7.2.1 Tissue Processing, Imaging and Analysis

The tissue samples obtained were processed as described in chapter 6. The precise details of all of the tissue processing steps are detailed in appendix B.

Histological and immunohistochemical analysis of the tissue samples was under taken to evaluate markers of, vascularity, inflammation, proliferation and apoptosis within the tissue:

- CD34, vascular endothelial antigen. This marker was used to identify vascular tissue within the samples.[180]
- CD45, leucocyte common antigen. This marker was used to identify white cells within the tissue samples as a measure of inflammatory cell infiltration.[181–183]

- MIB-1 (anti-Ki-67 antibody). This marker was used to identify cellular proliferation.[184,185]

- Active Caspase-3 (AC-3). This marker was used to identify cells undergoing apoptosis.[186]

The microscopy and image analysis were undertaken using the same method as previously described, as was the data collection and statistical analysis. The expression of immunohistochemical markers quantified from the image analysis was scaled to the control group included in chapter 6 for consistency of analysis.

7.3 Results

Thirty-seven participants were recruited into the study. Four participants did not undergo a post-treatment biopsy for several reasons: two participants from the GCI group declined the post-treatment biopsy so were excluded from the study; one participant in the SAD group had a post-operative infection of a surgical arthroscopy portal and was excluded from further biopsy and the study; one participant in the RCR group sustained an injury to the affected shoulder two days before the follow up visit and, although ultrasound scanning confirmed integrity of the repair, the arm was significantly bruised and swollen from the injury and a decision was taken not to proceed with a further biopsy and the participant was excluded from the study. One participant in the GCI group who underwent both biopsies was excluded due to the poor quality of the second biopsy, which was unsuitable for analysis.

Matched pairs of biopsies from thirty-two participants were included in the analysis. The group breakdown and demographic details are shown in table 7.1.

The pre and post-treatment data for expression of immunohistochemical markers in each group are displayed graphically in figures 7.2, 7.3, 7.4 and 7.5. Figure 7.6 shows the data for pre and post-treatment Oxford Shoulder Scores.

Vascularity was shown to increase significantly in the RCR group following surgery, although no significant change was seen in the other two treatment groups (see figure 7.2). Inflammation was significantly elevated in both of the surgical groups post-treatment (see figures 7.3). Proliferation decreased significantly in the GCI group (see figure 7.4). No significant changes were seen in the apoptotic activity or the Oxford Shoulder Scores pre and post-treatment in any of the groups.

Group	Number of Participants	Mean Age /years	♂ : ♀	Dominant Arm	Previous GCI	Mean Symptom Duration /months
GCI	10	50·3 [35–61]	4 : 6	7/10	5/10	19·9 [9–48]
SAD	13	48·2 [36–60]	9 : 4	7/13	13/13	16·3 [9–36]
RCR	9	59·9 [55–63]	6 : 3	7/9	9/9	17·6 [10–48]
ranges given in square brackets						

Table 7.1: Breakdown and demographics of the groups to which the thirty-two successful biopsy participants in the study were recruited

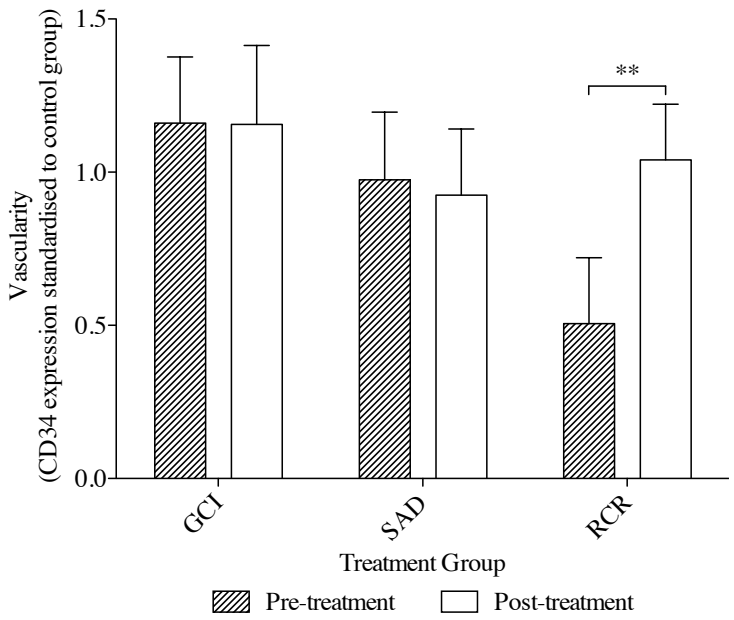

Figure 7.2: Vascularity, as measured by CD34 expression, of tissue samples from each of the treatment groups pre and post-treatment intervention (** denotes $p<0{\cdot}01$ for paired t-test of mean values pre and post-treatment).

7.4 Discussion

Understanding the pathophysiology of any condition is necessary in the development and evaluation of treatment modalities employed. In order to define the effects of a treatment intervention on its target tissue, measurement of biomarkers of disease must be evaluated before and after treatment in the same individual. This is the first study to undertake tissue analysis of the rotator cuff before and after a treatment interventions in-vivo. The method delivered paired tissue samples from cohorts of participants undergoing the three current interventions for various stages of rotator cuff tendinopathy. The technique has been shown to be effective, reproducible and provides a potential avenue for research into the development and evaluation of novel therapies.

The study results showed significant changes in tissue characteristics from each of the treatment groups. The GCI group showed a significant decline

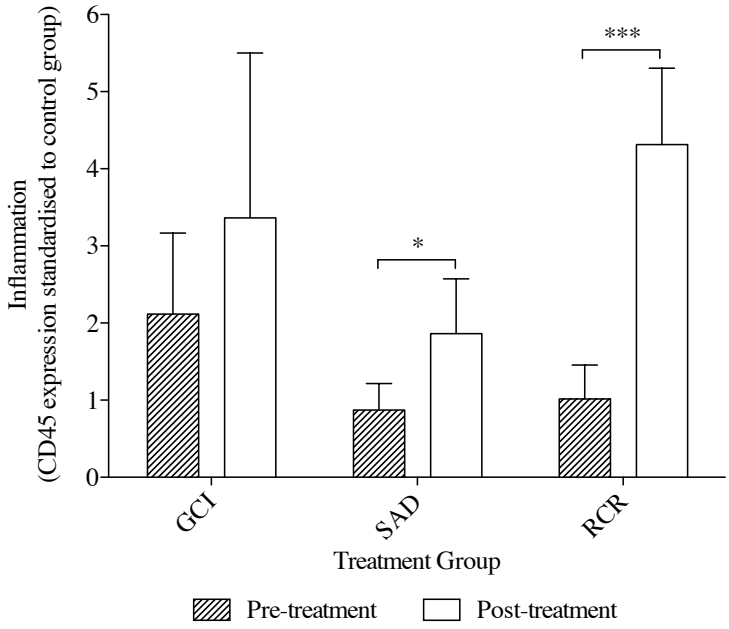

Figure 7.3: Inflammation, as measured by CD45 expression, of tissue samples from each of the treatment groups pre and post-treatment intervention (* denotes $p<0{\cdot}05$, *** denotes $p<0{\cdot}001$ for paired t-test of mean values pre and post-treatment).

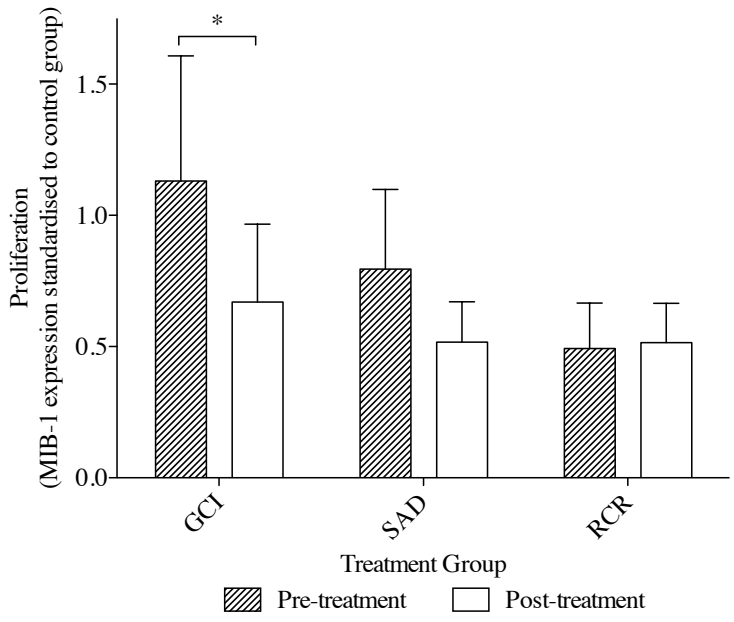

Figure 7.4: Proliferation, as measured by MIB-1 expression, of tissue samples from each of the treatment groups pre and post-treatment intervention (* denotes $p<0{\cdot}05$ for paired t-test of mean values pre and post-treatment).

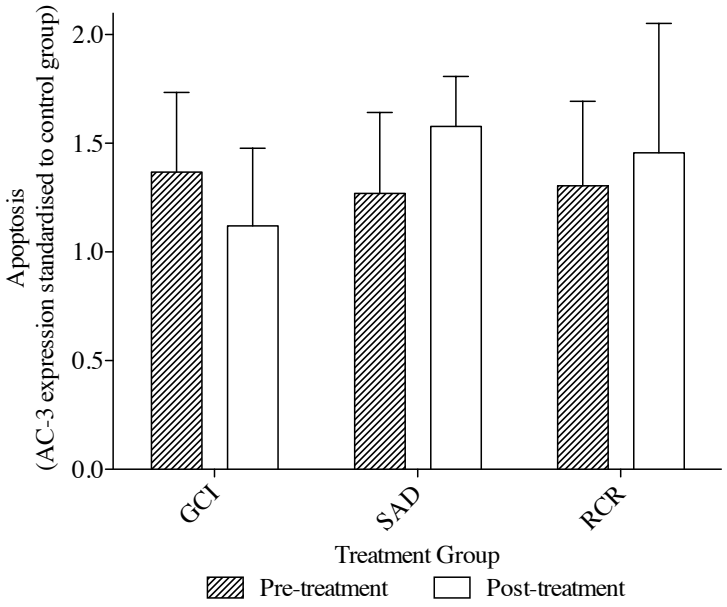

Figure 7.5:
Apoptosis, as measured by active caspase-3 expression, of tissue samples from each of the treatment groups pre and post-treatment intervention.

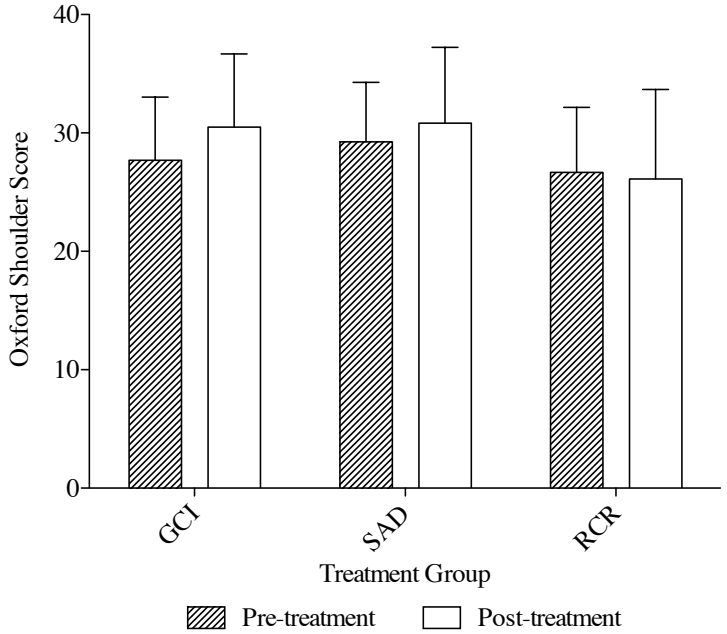

Figure 7.6:
Pre and post-treatment Oxford Shoulder Scores for each of the treatment groups.

in the degree of proliferative activity within the tissue at seven weeks post injection of glucocorticoid, although no significant changes was seen with regard to vascularity, inflammation or apoptosis (see figures 7.2, 7.3, 7.4 and 7.5). The potential detrimental effects of glucocorticoids on tendon tissue have been considered for some time and a recent meta-analysis of clinical findings has suggested that such treatment is of little or no benefit for this condition in the longer term and has a negative effect on lateral epicondylitis, a similar enthesopathic condition.[199,200] In-vitro study of the effects of glucocorticoids on tenocytes has shown them to reduce viability, extracellular matrix production and, in repeated studies, cause significant reduction in proliferative activity.[201–207] These in-vitro studies report results after exposure to glucocorticoid after time points far shorter than the seven weeks used in this study and, although the results from this work show a similar reduction in proliferation, this effect may be even more pronounced had the post-treatment biopsy been taken closer to the time of injection.

The SAD group demonstrated a significant increase in inflammation at seven weeks post-treatment without alteration in the other parameters assessed (see figure 7.3). Although significant, this increase in inflammatory activity can, almost certainly, be attributed to the residual effects of the surgical intervention. The RCR group showed an increase in inflammatory activity post-treatment far greater than the SAD group, also suggesting that the degree of trauma caused by the interventions undertaken may explain this change. A non-significant rise in inflammatory activity was seen in the GCI group which may suggest that the relatively minimal trauma caused by the core biopsy taken on the day of intervention causes a sustained inflammatory

response up to seven weeks following the sampling event.

The RCR group was the only group to demonstrate any significant alteration in vascularity post-treatment. The vascularity seen returned to a level comparable to that seen in the GCI and SAD groups which represent earlier stages of pathology (see figure 7.2). This increase in vascularity may represent a healing response triggered within the tendon that was initiated by the restoration of a tensile mechanical environment within the tissue and the inflammatory response seen following the surgery. These results support the principle of rotator cuff repair surgery by demonstrating the potential for the tendon to mount an inflammatory and vascular response to repair, perhaps indicating a healing reaction.

Despite the significant tissue changes shown in response to treatment, at the seven week post-treatment time point, no significant changes were demonstrated in the Oxford Shoulder Score, as a patient reported measure of shoulder pain and function (see figure 7.6). This study has introduced a method of analysis for rotator cuff tendinopathy that has demonstrated significant changes in the pathological tissue pre and post-treatment where no significant alteration in clinical condition was detectable using a validated clinical outcome measure. This offers a more detailed means of investigation and the potential for the use of outcome measures more sensitive to changes in response to treatment than clinical measures alone.

7.5 Limitations

As the first study to investigate tissue samples before and after treatment for rotator cuff tendinopathy, there are a diverse array of limitations that may have had an impact upon the results. With regard to the biopsy technique and tissue analysis process, the limitations of this aspect of the study were previously discussed in chapter 6. More specific to this study, the main limitations are inherent in the repetition of the biopsy, the timing of the post-treatment biopsy and the tissue analyses undertaken.

The biopsy technique excises a tiny core of tendon tissue from a defined location within the supraspinatus tendon. Repetition of the biopsy at a second time point, from the same location, offers the potential for residual effects of the first sampling episode to impact upon the tissue condition at the second time point. This feature may have been displayed as an increase in inflammation seen from each of the treatment groups. The surgical groups underwent significant trauma to the shoulder relative to the GCI group, perhaps explaining their increase in inflammation, although an increase was not expected from the GCI group. The elevated post-treatment inflammation in the GCI group was not significant and may be somehow related to the glucocorticoid injection administered, however, the potential for this feature to be in response to the biopsy taken cannot be ignored. A simple means of evaluating this phenomenon would be to take repeated biopsies from individuals who are not undergoing any treatment interventions to evaluate the effects of the biopsy alone. This option for investigation is unlikely to be possible due to limitations in ethical justification.

With regard to the practical aspects of the biopsy technique, no adverse effects of the initial or repeated biopsy were observed, although two participants in the GCI group declined a post-treatment biopsy. In both of these cases the participants did not describe worsening pain in the time following the biopsy and the injection of glucocorticoid, although their symptoms had not resolved and they voiced concerns that the biopsy may have restricted the potential benefit of their treatment so decided not to undergo a second biopsy.

In the development of the methodology of this study, a post-treatment time point of seven weeks was selected on the basis of practicality and minimal burden to the participants as there was no existing precedent with regard to tissue response to treatment that could be used as a guide. The participants in each group were routinely due to attend for follow up at 6–8 weeks post intervention; for the GCI group this point represented the time by which the pharmacological effects of the glucocorticoid injection should have worn off and for the SAD and RCR groups, a time at which they routinely begin to see improvements in pain and function following surgery. As such, the follow up for these individuals was fixed at seven weeks for consistency of method and to provide a starting point for this type of research.

The existing literature into the effects of glucocorticoids on tenocytes suggest that, for the GCI group, a more significant effect may have been seen had the biopsy been taken sooner after the intervention.[206] The study also showed significantly elevated levels of inflammation from the surgical groups, suggesting that the shoulder may still be undergoing a phase of resolution following surgical trauma; a later time point for tissue analysis

following surgical interventions may be more suitable in future studies.

The tissue characteristics analysed in this study focussed primarily on the cellular component of the tissue and used histological means of measurement. Attention to changes in the tissue at a sub-cellular level and with regard to the extracellular matrix may reveal more significant alterations in the biological activity within the tendon than can be detected using histology.

This work has introduced the concept of in-vivo pre and post-treatment tissue analysis in rotator cuff tendinopathy and future work using this method will allow the investigation of different time points post-treatment and the analysis of tissue samples using techniques other than histology and immunohistochemistry.

7.6 Significance

The pathophysiology of rotator cuff tendinopathy remains unclear resulting in limited capacity to develop and evaluate treatments for the condition. Analysis of tissue before and after a treatment intervention permits detailed study of the biological response to treatment. This study represents the first description of a method to analyse serial, in-vivo tissue samples from human rotator cuff tendon.

In addition, the results of histological and immunohistochemical analysis of this tissue have demonstrated a potentially negative effect of glucocorticoid therapy in terms of reduced proliferative activity within the tendon, a finding in keeping with existing in-vitro work. The results from rotator cuff repair treatment have also suggested the possibility of a healing response from the

torn tendon following surgical reattachment.

This study has opened the door to a means of treatment evaluation that can be more sensitive than clinical assessment alone and provides the opportunity to investigate the direct effects of treatment interventions administered. The application of such a method on a wider scale has the potential to inform the development and evaluation of novel therapies for rotator cuff tendinopathy.

Chapter 8

Age-Related Change in the Supraspinatus Tendon

8.1 Introduction

A clear understanding of the pathophysiology of rotator cuff tendinopathy is essential in the development of treatments and prevention of disease progression, as introduced in chapter 6. There are a number of factors that must be considered when trying to understand the causes of degeneration in rotator cuff tendons and what leads to the painful loss of function experienced by many patients. Some are specific to each individual such as genetic make-up, activity level, occupation, lifestyle and injury status; such a diverse array of characteristics represent a web of confounding influences that are almost impossible to tease apart. One major confounding factor in understanding the onset a progression of rotator cuff pathology that is common to all individuals is the process of ageing.

Rotator cuff tendinopathy is a condition that typically presents in patients above the age of forty years, peaks in presentation in the sixth decade and shows an increase in the incidence of structural tendon failure with advancing age.[13,14,42,208] Chapter 6 discussed the array of tissue work that has been undertaken in an effort to define the alterations in tendon tissue that occur through the spectrum of rotator cuff tendinopathy. A question that is commonly raised regarding this and other musculoskeletal conditions that include some element of degeneration, is what tissue changes seen are as a result of a pathological process and what changes are simply due to the normal process of ageing?

Published work into the effects of ageing on the rotator cuff tendons have identified alterations in cell morphology and number, degeneration and disorganisation of the extracellular matrix and reduced healing capacity.[39,43,44,47,209] As with the majority of tissue work evaluating pathological changes in tissue, these studies are limited due the the inconsistent methods with which the tissue samples studied were located, obtained and defined at a phenotypic level.

Ageing within musculoskeletal tissues is of increasing scientific interest. As lifestyle and healthcare has improved, the life expectancy of the population has increased. The population is ageing as a whole, life expectancy is increasing and individuals are remaining active much later into life; as such, the burden of healthcare attributable to degenerative musculoskeletal disease is increasing.[210–213]

Markers and modulators of tissue ageing represent an area of significant focus within degenerative medicine. The sirtuin family of intracellular pro-

teins have been suggested as modulator of ageing in cells, the declining concentration of which may be associated with age-related degeneration.[214–216] No work into specific marker of ageing in tendon tissue has been published.

The aim of this study was to evaluate tissue characteristics of the supraspinatus tendon across a wide age spectrum to identify patterns of change that may be associated with increasing age.

8.2 Methods

8.2.1 Participants and Tissue Sampling

Ethical approval for the study was granted by the local research ethics committee (Oxfordshire REC B, ref: 09/H0605/111 and Oxfordshire REC C, refs: 10/H0606/60 and 09/H0606/11). Participants were recruited from patients under the care of the shoulder team at a specialist orthopaedic hospital. Each participant underwent tissue biopsy of the rotator cuff and collection of demographic and clinical data. The participants recruited were undergoing treatment for glenohumeral instability or rotator cuff tendinopathy. The tissue sampling process was integrated into the treatments being administered in an effort to minimise the burden to participants. Ethical justification to obtain tissue samples from individuals who were not due to undergo an invasive intervention was not feasible at this stage.

Samples of supraspinatus tendon were collected using an ultrasound guided core biopsy technique as described in chapter 6. Biopsies were taken in a clinic setting under local anaesthetic from participants undergoing non-

surgical interventions and in the operating theatre from participants undergoing surgical interventions. In each setting participants were positioned in the same manner and the biopsies were taken using the same method.

Participants were recruited into groups defined by their age and symptomatology:

- Asymptomatic group: <35 years of age
- Symptomatic groups: 35–44 years, 45–54 years, 55–64 years, 65–74 years, 75 years and over

The asymptomatic group were recruited from young patients, under 35 years of age, who were undergoing anterior stabilisation surgery for traumatic shoulder dislocation. They had no history of rotator cuff tendinopathy and no evidence of structural damage to the rotator cuff on preoperative imaging or on arthroscopic assessment at the time of surgery. All participants had sustained anterior shoulder dislocation in the past and were undergoing surgery on an elective basis without dislocation in the previous two months, with shoulders in a quiescent state. All participants had type 1 shoulder instability without history or signs of connective tissue disorders or joint laxity.[178] This group represented the same control cohort that were analysed in chapter 6

The symptomatic groups were recruited from patients being treated for rotator cuff tendinopathy. All participants had subacromial impingement pain elucidated through history and examination findings including 'painful arc', positive Hawkins' and Jobe's tests.[16–18] The participants underwent an ultrasound scan of their affected shoulder during initial assessment and the

structural integrity of their rotator cuff tendons was recorded.

All of the individuals recruited into the study were undergoing treatment for a shoulder problem. In order to minimise the confounding effects of this methodological limitation the parameters for eligibility were clearly defined for each group. The asymptomatic group all had isolated, traumatic instability of the glenohumeral joint and were otherwise fit and well. The symptomatic groups had isolated rotator cuff tendinopathy in the shoulder, without concomitant pathology. Participants were excluded from the symptomatic groups if they had a history of significant trauma to the affected shoulder, previous or current shoulder problems other than rotator cuff tendinopathy, previous shoulder surgery, a history of systemic steroid use, local glucocorticoid injections in the last six weeks, history of tobacco smoking or a significant systemic medical condition such as diabetes or rheumatological condition.

8.2.2 Tissue Processing, Imaging and Analysis

The tissue samples obtained were treated in the same manner as described in chapter 6. The precise details of all of the tissue processing steps are detailed in appendix B.

Histological and immunohistochemical analysis of the tissue samples was under taken to evaluate markers of cellularity, vascularity, proliferation, apoptosis and ageing (age-related degeneration) within the tissue:

- Haematoxilin and Eosin (H&E). The stain was used to assess the quality of the biopsy sample taken and clearly identify the nuclei within

the tissue in order to permit a nucleic count as a marker of cellularity.

- CD34, vascular endothelial antigen. This marker was used to identify vascular tissue within the samples.[180]

- MIB-1 (anti-Ki-67 antibody). This marker was used to identify cellular proliferation.[184,185]

- Active Caspase-3 (AC-3). This marker was used to identify cells undergoing apoptosis.[186]

- Human Sirtuin-1 (SIRT-1). This antibody was used as a marker of tissue ageing.[214–216]

The microscopy and image analysis were undertaken using the same method as previously described, as was the data collection and statistical analysis. Due to the nature of potential confounding shoulder pathology of the individuals in the study the older age groups were analysed as cohorts compared to the <35 group as a baseline control population. The expression of immunohistochemical markers quantified from the image analysis was scaled to this control group as had been done in chapter 6 for consistency of analysis.

8.3 Results

Ninety-five participants were recruited into the study and underwent ultrasound guided core needle biopsy of the supraspinatus tendon. Table 8.1 details the group sizes.

Study Group (age /years)	No. of Participants
<35	16
35–44	11
45–54	15
55–64	25
65–74	17
≥75	11

Table 8.1: Participants recruited to each of the study defined age groups.

Adjacent 3μm sections of a single biopsy sample were stained using H&E and for expression of CD34, MIB-1 and active caspase-3 as shown in figure 6.6, shown in chapter 6. A section from each biopsy was also stained for SIRT-1 as shown in figure 8.1.

The data for cellularity, as measured by nucleic count, and expression of immunohistochemical markers for each group are displayed graphically in figures 8.2, 8.3, 8.4, 8.5 and 8.6.

Cellularity was not shown to vary significantly across the age groups (see figure 8.2), although data from the remaining assays demonstrate a number of patterns that develop across the age groups. Vascularity and proliferation remain sustained at a similar level to that seen in the <35 group up to the 45–54 group before showing a significant decline within the tissue as age increases beyond this point (see figures 8.3 and 8.4). Apoptosis showed a similar patter, although significantly reduce activity was only seen in the 65–74 age group (see figure 8.5). SIRT-1 expression, as a marker of ageing, showed a steady decline in expression across all of the age groups, reaching

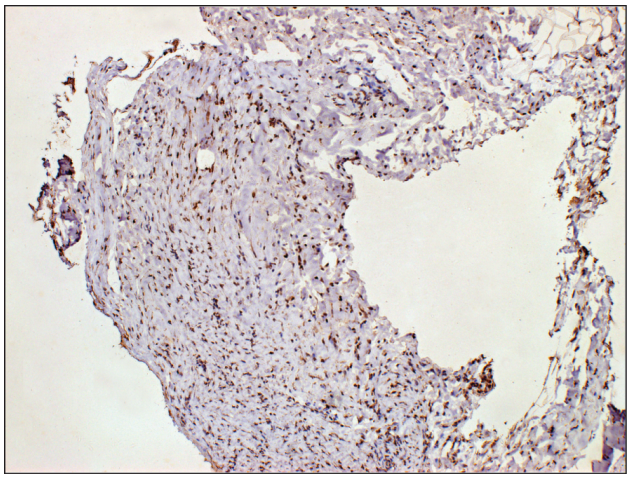

Figure 8.1: Light micrograph showing a section of supraspinatus tendon tissue stained to identify SIRT-1 expression (magnification 100x).

significance in the two oldest groups (see figure 8.6).

8.4 Discussion

The principal trend displayed by the results is one of the tendon tissue progressing towards a state of reduced viability and senescence as age increases. Features of viability within the tissue represented by vascularity and cellular activity all fell significantly in the older age groups studied.

Previous tissue studies have focussed primarily on the study of extracellular matrix changes in the tendon in association with age and were limited by the use of samples obtained from cadaveric sources or the torn edge of the structural defect within a full thickness rotator cuff tear.[42–44] The successful healing, as measured by repair integrity, of a torn rotator cuff has also been shown to be reduced in older patients.[217] These studies suggest worsening structural integrity within the supraspinatus tendon as age increases

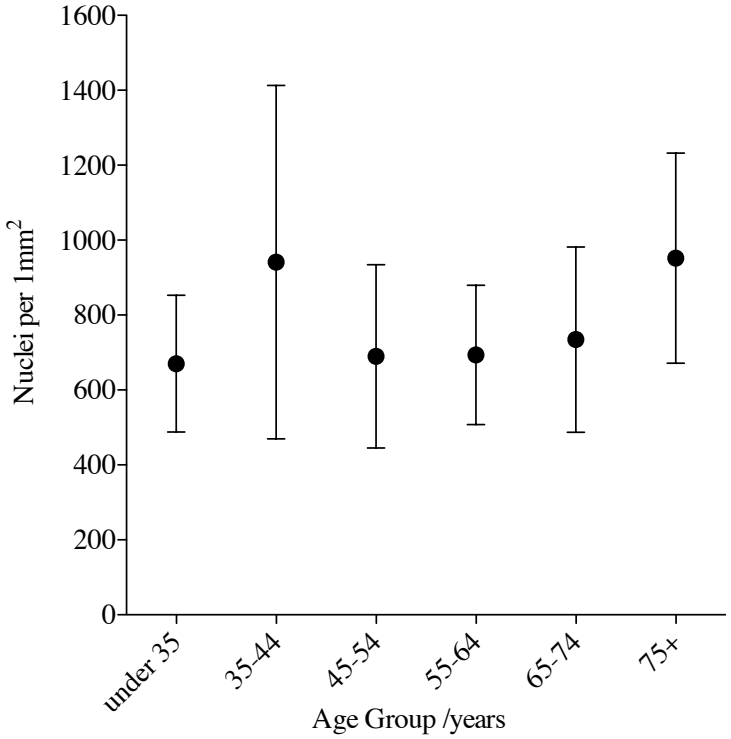

Figure 8.2: Cellularity, as measured by nucleic count, of tissue samples from each of the age groups.

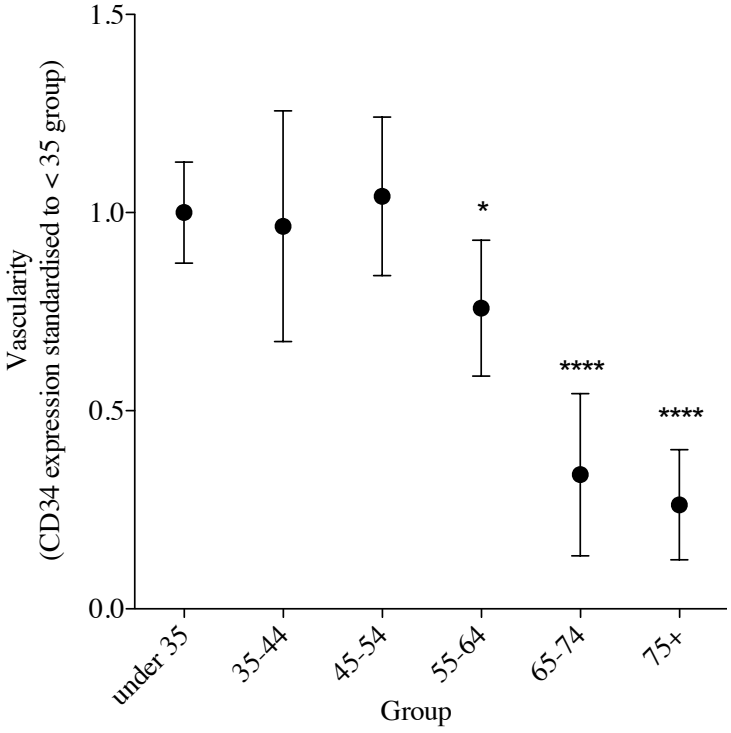

Figure 8.3: Vascularity, as measured by CD34 expression, of tissue samples from each of the age groups (* denotes p<9·05, **** denotes p<9·0001 for unpaired t-test of mean versus <35 group mean).

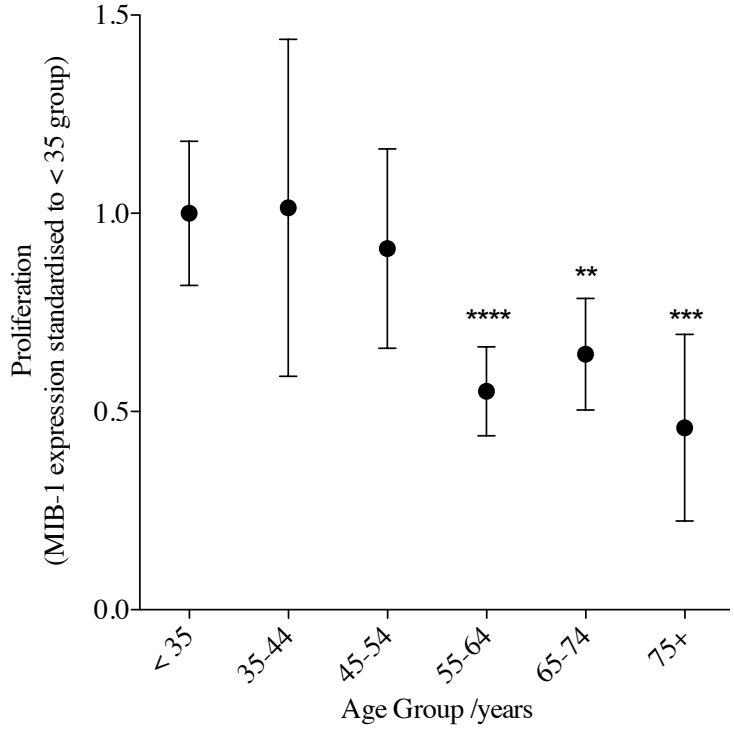

Figure 8.4: Proliferation, as measured by MIB-1 expression, of tissue samples from each of the age groups (** denotes p<9·01, *** denotes p<9·001, **** denotes p<9·0001 for unpaired t-test of mean versus <35 group mean).

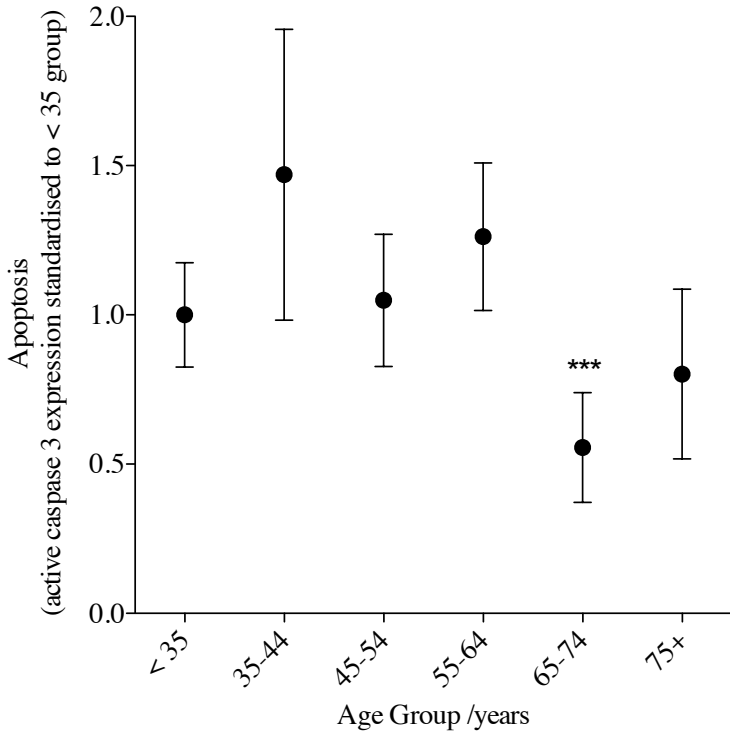

Figure 8.5: Apoptosis, as measured by active caspase-3 expression, of tissue samples from each of the age groups (*** denotes p<9·001 for unpaired t-test of mean versus <35 group mean).

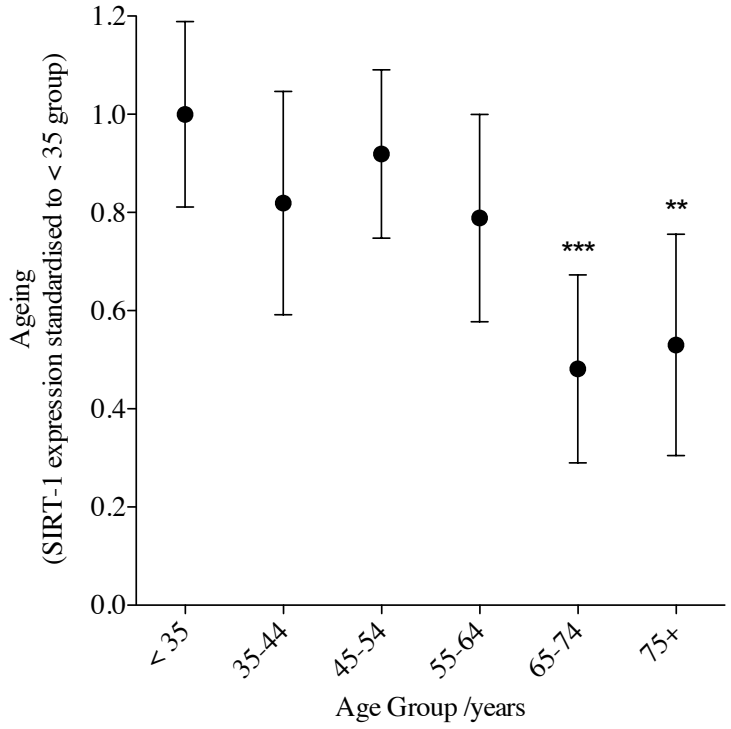

Figure 8.6:
Ageing, as measured by SIRT-1 expression, of tissue samples from each of the age groups (** denotes p<9·01, *** denotes p<9·001 for unpaired t-test of mean versus <35 group mean).

in addition to impaired healing potential.

The features of the tendon tissue assessed in this study focussed on the presence and activity of cells within the tissue. Although not a direct measure of extracellular matrix integrity or organisation, the adequate reattachment following repair or remodelling of a damaged supraspinatus tendon, is reliant upon the viability and activity of the cells within the tissue to facilitate the regeneration process. The results shown in this work support the finding from the clinical and basic science work previously described as the suprasinatus tendon has been shown to have reduced cellular activity and vascular supply with age, both of which are necessary if successful regeneration is to take place.

Although there appears to be a general decline in tissue viability with age in these samples, the data suggest that several of these features may be

maintained into an individual's sixth decade before decreasing significantly compared to the <35 age group. Vascularity and proliferative activity remain relatively unchanged from the <35 age group through the 35–44 to the 45–54 age group (see figures 8.3 and 8.4). Neither of the features show a significant change at these ages and the mean values vary very little between these groups. In the 55–64, 65–74 and ≥75 age groups, a significant drop off in both vascularity and proliferative activity is seen. Interestingly, the timing of this deterioration in blood supply and cellular activity within the tissue occurs over a very similar range to the peak age of symptomatic presentation and failure of rotator cuff tendons in the diseased population.[14,208] Apoptotic activity also shows a decline with age although the trend is not as clear statistically, compared to the results for vascularity and proliferation (see figure 8.5). Cell density was not shown to alter significantly with age, although the presence of inactive cells in an older tendon may result in the same outcome as reduced cellularity within the tissue.

These changing features in tissue character reflect a physiological 'shut down' within the tendon. This raises the question of what initial trigger may cause this process to occur? The process may be driven by an initial deterioration in vascularity leading to a general reduction in cellular activity, although this is unlikely to be a primary event. When considering age-related degeneration as a cause of tissue deterioration, the expression of SIRT-1 as a potential biomarker of ageing within musculoskeletal tissues must be taken into consideration. The data displayed in figure 8.6 demonstrate a gradual decline in SIRT-1 expression with increasing age. This finding is of particular interest when considered in the context of work that has suggested

mammalian SIRT-1 to be a factor capable of prolonging lifespan in yeast, improving the physical condition of ageing mice and leading to reduced bone formation in mice that are missing the SIRT-1 gene.[214–216] It may be that the gradual decline in SIRT-1 expression represents a mark of age-related change within this tissue that results in reduced vascularity, cell senescence and ultimately impacts upon the quality, integrity and regenerative capacity of the extracellular matrix.

The tissue samples evaluated in this study were obtained from patients with symptomatic rotator cuff tendinopathy, apart from the <35 group. As a result, the presence of pathology in the tissue being studied may have a significant confounding impact upon the results of the study. In support of this recruitment method, however, no significant difference was seen between the <35 group, acting as a control, and the 35–44 or 45–54 groups for any tissue measure. The similarity of tissue characteristics in these groups suggests that, whatever clinical manifestation of pathology may be present in the tendons of these individuals, it did not appear to be due to an age-related change in the parameters analysed in the study.

Figure 8.7 shows a graphical representation of the stages of pathology represented within each age group. The stages have been determined clinically by the treatment modality being received and the integrity of the rotator cuff for each participant as described in chapter 6. These progress from asymptomatic thorough glucocorticoid injection therapy (GCI) and subacromial decompression (SAD) without a full thickness rotator cuff tear to the terminal stage of tendinopathy with tendon failure and the presence of a full thickness rotator cuff tear (FTT). The figure shows that, as age increases,

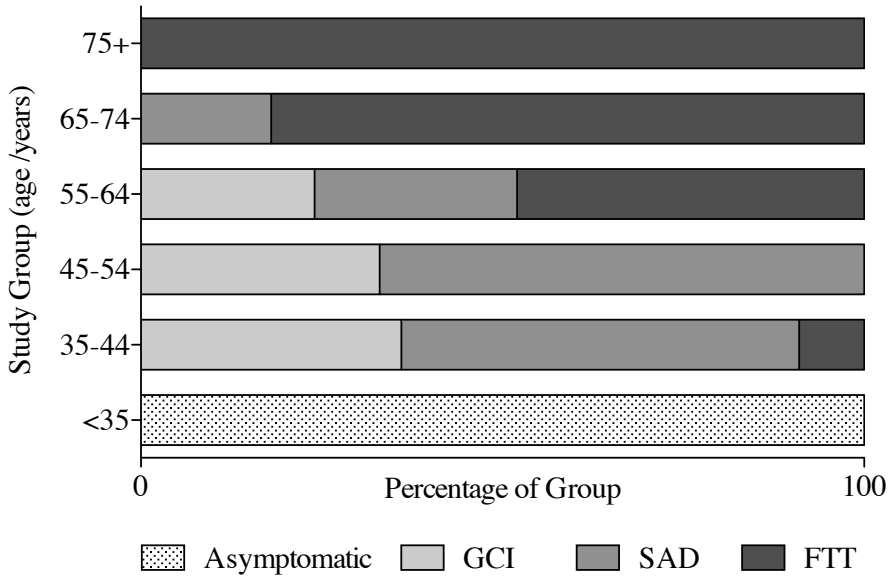

Figure 8.7: Graphical image of the stages of pathology represented by each age group within the study: glucocorticoid injection (GCI), subacromial decompression (SAD) and full thickness rotator cuff tear (FTT).

clinical stage of tendinopathy also progresses. Comparing the results from this study with those from chapter 6 it can be seen that both later disease progression and ageing are associated with a fall in vascularity and cellular inactivity without a significant change in cell number but it is not possible from this body of work to tease apart these causative factors.

This study has demonstrated clear, significant changes in the tissue characteristics of the supraspinatus tendon as age increases, with a maintenance of viability markers into the sixth decade before a significant deterioration in the cellular activity and potential to heal within the tendon tissue in the older age groups. Although studied in a diseased population, the results suggest a direct link between ageing and tendon degeneration, a trend supported by a

decline in SIRT-1 expression, a potential biomarker of ageing tissue.

Future work must identify age-matched cohorts of individuals without any history of symptomatic rotator cuff tendinopathy to clarify the nature of the tissue changes seen in the tendon that may be attributed to age or to pathology. This work represents a significant step forward in justifying the importance, feasibility and acceptability of such a study on ethical grounds.

8.5 Limitations

The major methodological limitation of this study is the use of a symptomatic population for tissue sampling and has been referenced throughout the chapter. This weakness limits the degree to which conclusions can be drawn as to the influence that advancing age may be a factor in the tissue changes seen within the tendon. Ethical justification to undertake this research with individuals who were not due to undergo some kind of invasive shoulder intervention was not possible at the time of study planning. The significant trends seen in the results from this work, however, lay the foundations for future work into ageing of musculoskeletal tissues including the supraspinatus tendon. The practical success of the study and use of this biopsy technique provide a clear methodology for future studies that aim to investigate an age-matched, asymptomatic population.

The limitations of methods used in this study for tissue processing and image analysis are shared with those of the previous study and discussed in chapter 6.

8.6 Significance

This analysis of a large number of tissue samples, topographically matched within the supraspinatus tendon, from well phenotyped individuals across a wide age spectrum has built on existing evidence from cadaveric work of the degenerative nature of rotator cuff tendon failure and its association with normal ageing.[42–44]

The results from this study clearly demonstrate a deterioration in tissue viability as demonstrated by falling vascular supply to the tissue and cell senescence. The study of a potential biomarker of tissue ageing in SIRT-1 expression has reinforced the suggestion that the tendinopathic process seen in the rotator cuff which has been considered pathological may, in no small part, be attributed to a normal ageing process.

The methodology demonstrated and evidence presented offers a consistent and reproducible analytical process that can be implemented to improve future research into musculoskeletal ageing. In a society of advancing years, degenerative musculoskeletal conditions is becoming more prevalent and an increasing burden on the healthcare system. An in-depth understanding of ageing, pathology and their interaction in these tissues is essential in order to effectively treat and prevent these conditions in the future.

Chapter 9

Discussion

9.1 Introduction

Effective clinical evaluation and management of musculoskeletal disease requires a detailed understanding of the pathological processes involved. Insight into the aetiology, progression and effects of treatment associated with such conditions provides a knowledge base that can be used to guide clinical practice. Accurate identification of the type and stage of disease presented by a patient offers clinicians the ability to provide an explanation of the diagnosis, likely prognosis and potential benefits and harms associated with available treatments. The process of information gathering, assimilation and explanation to a patient forms the mainstay of professional practice for clinicians treating any disease, however, the accuracy of the information given is reliant upon prior comprehensive, robust scientific investigation.

Rotator cuff tendinopathy, like many other musculoskeletal conditions, manifests itself in the life of a patient as the presence of pain and reduced

function from the affected limb.[13,14] The main focus of treatment therefore, has always been the elimination of such symptoms and signs through the use of pain killers, anti-inflammatories (on the the assumption that the condition had an inflammatory component), surgical decompression and the mechanical repair of structural defects in the affected tendons. The efficacy of such treatments is unclear, with evidence to support or refute their effectiveness limited in quantity and quality.[71,74,199]

An ever growing array of research into the biological changes associated with rotator cuff tendinopathy has built a library of heterogenous studies offering varied and often contradictory findings.[30] The lack of consensus in reporting from this work stems from investigation using tissue of questionable validity with regard to its relevance to rotator cuff tendinopathy in humans. The analysis of animal tissue in species that do not experience rotator cuff tendinopathy raises questions over the translatable nature of this work; cadaveric tissue is limited by the lack of information regarding phenotypic and symptomatic condition of the donors; the study of resected tissue from the excised edge of a torn rotator cuff tendon represents the terminal stages of pathology and may, in fact, represent an area of granulomatous tissue rather than true tendon and the use of control tissue from structures other than the supraspinatus tendon undermines the validity of any results from comparison with such samples.[35–70] These limitations and variability in study methodology and design restrict the conclusions that can be drawn from this vast body of work.

Clarity in the findings of tissue investigation into rotator cuff pathology can only be achieved through a rigorous and detailed review of the basic

methodology used to identify and collect tissue samples for analysis. The laboratory investigations and methodology used in the existing literature may be of impeccable quality, however, selection of unvalidated tissue sources and limited phenotyping and sampling consistency has undermined such scientific endeavour. Revisiting the basic requirements for robust tissue collection will provide greater validity, consistency and comparison of future research in this area.

Rotator cuff tendinopathy remains a significant clinical problem that is poorly understood and widely treated with interventions of unproven efficacy and unknown tissue effect. A standardised, validated and reproducible method of tissue evaluation will bestow greater significance on future research and allow the identification of clinically useful biomarkers of disease that can be used in the diagnosis, prognostication and treatment evaluation of the condition. The work included in this thesis has described high quality methods for tissue collection and analysis and begun to identify changes in biomarkers of disease that can inform future research into the understanding and treatment of rotator cuff tendinopathy.

9.2 Main Findings

Over the last decade a substantial and accelerating increase in the provision of surgical interventions for rotator cuff pathology has been demonstrated in England (see chapter 2). This increase has been sustained despite economic austerity nationwide and a lack of convincing evidence to support the use of either subacromial decompression or rotator cuff repair surgery.[71,73,74] Such a

change in practice demonstrates the significant demand within the population for treatment of this condition and the growing willingness of orthopaedic surgeons in England to offer surgical interventions without adequate evidence for their efficacy. Interestingly, the results from chapter 2 show a decline in rotator cuff repair surgery over the last three years, coinciding with the start of a large, multi-centre, randomised controlled trial evaluating techniques for such surgery. An association between the change in rates of rotator cuff repair surgery and a well publicised, ongoing investigation into that area, illustrates the power of well designed research to raise questions over current practice and potentially influence the behaviour of clinicians in how readily they undertake such an intervention. In the management of rotator cuff tendinopathy, the potential implications for future practice of research into the pathological processes seen and the effects of treatments used is substantial.

The basis of understanding and describing the tissue pathology associated with rotator cuff tendinopathy and the response of a tissue to treatment interventions relies upon the identification of biomarkers defining the stage of disease. These features may be any measurable parameter, although a tissue or imaging biomarker offers the most direct evaluation of the affected tendon. In order to undertake analyses using ultrasound as an accessible imaging modality and to accurately guide the sampling of rotator cuff tendon tissue, a training method for orthopaedic surgeons was described in chapter 3. The method allowed surgeons to learn to navigate and evaluate the integrity of the rotator cuff tendons independently and against a gold standard for diagnosis. Compared to the published literature for experienced

musculoskeletal radiologists and orthopaedic surgeons performing shoulder ultrasound, the method described in chapter 3 demonstrated similar levels of accuracy in the identification of full thickness rotator cuff tears within 50–100 scans, offering a more feasible option for training than the existing methods suggested.[24,96,101–103,109]

An ultrasound imaging biomarker of disease would offer a useful clinical and research tool in the evaluation of tissue condition without the need for tissue sampling. Chapter 4 investigated the use of contrast enhanced ultrasound to measure the vascularity of the rotator cuff tendons. Recently published work suggested this imaging modality to be effective in assessing peritendinous structures and suggested the possibility of using such a method to evaluate the tendon tissue specifically.[135–139] The study described in chapter 4 utilised the most advanced technology available to carry out contrast enhanced ultrasound studies of the supraspinatus tendon. Although the investigation reliably identified contrast agent, and hence blood volume, in vascular areas of the shoulder, this imaging modality was shown to be ineffective in the measurement of intratendinous blood volume.

Chapter 5 described the development of a topographically accurate, minimally invasive method for sampling the supraspinatus tendon from a consistent anatomical location. The method was employed in the studies described in chapters 6, 7 and 8 to obtain tissue samples from a large number of individuals without significant complication and on more than one occasion in the participants recruited to the study in chapter 7. The biopsy technique was well tolerated and delivered biopsy samples of consistent quality for analysis. This method provides access to tissue samples of supraspinatus tendon at all

stages of rotator cuff tendinopathy and at more than one time point, offering the potential to evaluate the tissue effects of administered treatments.

Chapters 6, 7 and 8 presented studies of three aspects of rotator cuff tendinopathy to investigate the aetiology and progression of pathology and the effects of current therapies. Chapter 6 demonstrated changes across the clinical spectrum of disease, suggesting the presence of an active phase within the tendon during the early stages of pathology, characterised by an increase in inflammatory cell infiltration and apoptosis. This stage of pathology has not been studied previously at a tissue level. This study represents the first description of tissue characteristics at the early stages of disease and in comparison with a topographically matched control from the supraspinatus tendon. The later stages of tendinopathy showed a deterioration in cellular activity and viability of the tendon with a decline in vascularity and proliferation. Existing literature evaluating tissue from the torn edges of rotator cuff tendon and using either subscapularis or cadaveric tendon as a control have shown both an increase and decrease in vascularity of torn supraspinatus tendons.[51,57,60] Comparison between this literature and the current study is difficult due to the variation in tissue used for analysis. The use of accurately located and well phenotyped tissue, all from the supraspinatus tendon, seen in chapter 6 strengthens the validity of these results when compared with previous work.

Evaluation of tendon tissue before and after treatment interventions was demonstrated in chapter 7. This study describes the first presentation of serial tissue samples from rotator cuff tendons, demonstrating the ability to evaluate current therapies. Following subacromial injection of glucocor-

ticoid the tissue showed a significant reduction in proliferation, similar to in-vitro results from existing published work.[202,204,206] This tissue analysis offers further evidence to support the long held suspicion that the use of glucocorticoids may have a detrimental effect on tendons in the long term, a finding that has being demonstrated clinically in lateral epicondylitis.[199] Evaluation of surgical treatments showed elevated inflammatory cell infiltrate in the tendon tissue at seven weeks, although this finding is most likely to be due to an ongoing reaction to the surgical intervention and highlighted by the relatively early time point for biopsy post surgery. A significant increase in vascularity of the supraspinatus tendon was demonstrated following rotator cuff repair surgery, a response that shows increased potential for healing within the tendon. This change within the tendon demonstrated a substantial alteration in its biology as vascularity returned to a level in keeping with that seen from intact rotator cuff tendons.

Rotator cuff tendinopathy has been considered and treated as a pathological condition for many decades, although the lack of presenting cases in young patients suggests that age-related degeneration may play a part in the aetiology of the condition. Chapter 8 explored the patterns of change in tissue characteristics with age in a symptomatic population compared to an asymptomatic, young population. In participants aged 35–54 years, despite the presence of pathology, no significant changes in tissue characteristics were identified compared to the healthy controls, all of whom were aged under 35 years. The older age groups demonstrated significant reductions in vascularity, proliferation and apoptosis as well as a fall in the expression of SIRT-1 as a marker of age-related degeneration. These findings show a deteriora-

tion in tissue viability and activity with age, the cellular component of the tendon becomes senescent and inactive in conjunction with falling vascularity. Previous studies looking at age-related changes in the supraspinatus evaluated cadaveric samples and identified degenerative changes in the extracellular matrix, findings that could certainly be in keeping with reduced cellular activity in the tendon and an inability to repair and remodel damage.[42–44] This study offers strong evidence to support the theory that ageing is a major contributing factor in the onset and progression of rotator cuff tendinopathy.

9.3 Strengths and Limitations

The major focus of each of the imaging and tissue studies in this work has been the development of rigorous, consistent methodology that permits the evaluation of clinically and scientifically relevant sources of tissue in the study of rotator cuff tendinopathy. The attention to detail at each step of the technical development of the ultrasound training method, biopsy technique, tissue processing and image analysis has been driven by the desire to consolidate a definitive means for identification and evaluation of biomarkers of pathology. The heterogeneity of sampling methods, choice of tissue and means of analysis in the existing literature has prevented the integration of published works into a coherent description of the aetiology and progression of rotator cuff tendinopathy, limiting the application of this vast body of work into the development of effective treatments for the condition. The use of the methods described here will permit consistency between tissue sam-

ples taken from discrete cohorts and offer the potential for collaborative and cumulative research between groups.

The main limitations of the work presented are derived from technological deficiencies, the existing lack of knowledge regarding the phenotypic progression of tendinopathy, the restrictions associated with small tissue samples and the ethical justification of novel, invasive tissue sampling methods.

The use of ultrasound as an imaging modality, although significantly advanced over the last twenty years, remains limited by the subjective interpretation of the user and the relative resolution of the modality. Further advancements in ultrasound technology or investigation into the interpretation of raw ultrasound data rather than visual image analysis may provide the potential for imaging biomarkers in the future although, currently, the subjective analysis of images and the use of contrast enhanced ultrasound is not sensitive enough to offer any more than macroscopic structural information.

Investigation into the spectrum of rotator cuff pathology relied upon the use of and progression between current treatment interventions to identify the clinical stage of pathology. In the absence of a biomarker of disease this measure provided a surrogate identifier of disease progression in conjunction with macroscopic integrity. Although a degree of heterogeneity exists within these cohorts, limited understanding of the condition prevented further division of the groups. The use of the methodology described may provide further insight into the condition and allow the development of more accurately phenotyped stages of pathology.

As the first study to evaluate serial tissue samples in the rotator cuff, a

relatively arbitrary time point had to be selected for initial analysis. The work presented may offer guidance for future studies in order to define and investigate other time points of relevance. The results from the surgical groups showed ongoing inflammation at seven weeks post-operatively suggesting that a longer time point may be more appropriate for post-treatment investigation of those groups. Future work may allow for the description of the temporal response to treatment interventions in the short and longer term using several cohorts of analysis and further serial biopsies.

The impact of ageing on the supraspinatus tendon was described in chapter 8, although the presence of pathology in these study groups offers a significant potential confounding factor to the results. A lack of significant change in tissue characteristics between the young asymptomatic group and the symptomatic participants aged up to 54 years supports the conclusions regarding age-related change, however, the investigation of age-matched, asymptomatic individuals is needed to clarify these findings. Ethical approval for such a study may now be possible in future work following the positive results from these studies and the successful, safe use of the biopsy method described.

The limitations inherent in these studies do not undermine the results described although place them in perspective when compared to the position of current research. There remain many unanswered questions with regard to rotator cuff tendinopathy and its treatment and these studies provide substantial advancement in terms of methodology and guidance for future research priorities.

9.4 Thesis Scope

Chapter 1 introduced a number of questions to be investigated in this thesis, each of which has been addressed by one or more of the studies described.

1. How prevalent is surgical treatment for rotator cuff tendinopathy and has this changed over the last decade?

Chapter 2 investigated the provision of surgical treatment for rotator cuff tendinopathy across England over the last decade. A vast increase in number of procedures was seen over that period across the country, with subacromial decompression accelerating over time. Interestingly, the performance of rotator cuff repair surgery was shown to fall in conjunction with the start of a large multi centre randomised trial into the efficacy of such surgery. This supports the value of, and need for, high quality research in questioning the efficacy of, and effecting a change in, clinical practice.

2. What can ultrasound offer as an imaging modality in the development of tissue and imaging biomarkers of rotator cuff tendinopathy?

In chapter 3 the potential for ultrasound to be used as an imaging tool for surgeons in a clinical setting was demonstrated. The method described is also of value in a research environment to evaluate the structural integrity of the rotator cuff in experimental groups.

The application of contrast enhanced ultrasound in the development of an imaging biomarker of tendinopathy within the supraspinatus was investigated in chapter 4 and shown to be unsuitable due to the limitations of the

technology. Developments in ultrasound or magnetic resonance imaging may offer more sensitive options for investigation in the future.

The use of ultrasound to accurately navigate the rotator cuff and guide a biopsy needle into the supraspinatus tendon was applied in the biopsy method described in chapter 5.

3. Can a minimally invasive biopsy method be developed to provide samples of the supraspinatus tendon in a safe, repeatable and topographically consistent manner for laboratory analysis?

The stepwise development of a minimally invasive, ultrasound guided biopsy method for sampling the supraspinatus was demonstrated in chapter 5. The method was shown to be topographically accurate and facilitated sampling of the tendon from individuals with rotator cuff tendinopathy in both a clinic and theatre setting. The samples obtained were of comparable quality to previous surgical resection samples and shown to be adequate for histological and immunohistochemical analysis.

4. What cellular tissue changes are seen in the supraspinatus tendon across the spectrum of rotator cuff tendinopathy, in response to current treatments and in association with advancing age?

A series of experimental cohorts were identified and investigated in chapters 6, 7 and 8. The tissue analysed demonstrated significant changes in cellular characteristics across the spectrum of pathology, in response to current treatments and in association with age. These findings have provided several new

insights into rotator cuff pathology and described target areas and methods for future research.

9.5 Contribution to Existing Knowledge

The work included in this thesis contributes to a number of areas of the existing literature surrounding rotator cuff tendinopathy including healthcare provision, imaging analysis and tissue evaluation.

The identification of a vast increase in provision of treatment for this condition over the last decade in the absence of good scientific support for such interventions raises questions regarding the economic and clinical justification for this practice. These findings support the need for further research into rotator cuff tendinopathy and its treatments. This is important in raising awareness of research and the future recruitment of both patient and clinician participants to large multi-centre clinical trials and research studies.

The development of validated, reproducible techniques for image and tissue analysis of the rotator cuff from this work will provide and consistent research methodology that can be used in future studies. These techniques provide the opportunity for non-radiologists to undertake ultrasound evaluation of the rotator cuff and to obtain tissue samples collected in a manner that permits comparison of studies performed in different research centres or under the auspices of large clinical trials.

The tissue analyses of several patient cohorts in this work has provided the first description of tendon evaluation across the whole spectrum of pathology, including asymptomatic controls and the comparison of paired tissue samples

before and after treatment. The findings from these studies suggest an early active phase of pathology within the tendon and describe the failing nature of the tissue with progressive pathology. Many of these degenerative changes have been shown to increase significantly with age and support the theory that rotator cuff tendinopathy may, in no small part, represent a process of age-related change. Evaluation of treatments has added credence to the suggestion that the use of glucocorticoids in the treatment of tendon pathology may lead to detrimental change of the tissue in the long term and has shown the possibility of a healing reaction from the rotator cuff following surgical repair.

9.6 Implications for Future Research and Clinical Practice

Several of the studies described offer the opportunity for further development of the understanding of rotator cuff tendinopathy. The biopsy method described can be employed universally across rotator cuff tissue research to standardise tissue samples that can then be used in pooling of research efforts. The tissue analyses undertaken in each of the studies described can be expanded to include investigation of the mechanical, extracellular and subcellular (biochemical, protein, genetic) features of the tissue. These types of tissue analysis may offer a more sensitive means of identifying changes in the tendon tissue than provided by histology alone.

Future research leading on from this work should focus on a number of

key areas:

1. Further characterisation of the aetiology and progression of the tendinopathic spectrum seen in the rotator cuff investigating pain mechanisms and tissue degeneration within the tendons.

2. Use of tissue analysis to evaluate current treatments at time points other than those investigate within this body of work and assessment of novel, biologic therapies to treat the condition. Biological outcomes should then be combined with measure of clinical outcome such as patient reported outcome measures to develop robust and informative randomised clinical trials to assess current and novel therapies.

3. The impact of ageing on the degenerative state of the rotator cuff tendons must be quantified separately from the effects of any pathological condition that may be a contributing aetiology. The next stage of analysis should be to recruit a cohort of asymptomatic individuals from across the age spectrum and undertake tissue biopsy and analysis similar to that carried out in chapter 8.

4. Dissemination and standardisation of the ultrasound, biopsy and tissue analysis methods devised in this work to facilitate comparative and collaborative research into rotator cuff tendinopathy.

Some progress in these areas has already begun. The samples collected as part of this work are being used to extend the biological assessment of the tendon tissue across the stages of disease, treatment and age with investigation into the presence of nociceptive fibres and chemical markers within the

tissue and more detailed assessment of the degenerative changes occurring within the tenocytes, looking particularly at the p53 pathway.

Investigation into the tissue effects of novel biologic therapies in combination with clinical outcome is underway with recruitment of patients with rotator cuff tendinopathy to a double blind randomised controlled trial investigating the use of platelet-rich plasma as a novel treatment for rotator cuff tendinopathy (clinical trial number: ISRCTN10464365).

Ethical application is underway to recruit a 'normal, asymptomatic, age-matched cohort' of individuals from whom tissue samples of the rotator cuff tendons can be acquired and analysed in comparison to the previously sampled 'diseased' cohort with the aim of separating pathological changes in the tissue from those that are part of normal ageing.

The ultrasound training method described in chapter 3 provides an essential research tool for the evaluation of structural integrity within the rotator cuff and the accurate guidance of the biopsy needle for tissue sampling. In clinical practice, however, this method is of value to many non-radiologist clinicians treating rotator cuff tendinopathy as part of a comprehensive, fast and cost-effective one-stop clinic for assessment and treatment. This method has recently been introduced by the British Elbow and Shoulder Society as part of newly published guidelines on training in shoulder ultrasound for orthopaedic surgeons.[112]

9.7 Conclusions

The practice of orthopaedic surgery and the treatment of musculoskeletal conditions such as rotator cuff tendinopathy has progressed in a largely empirical manner since it began, often trialling therapies derived on the basis of tenuous theories of action to treat pain and reduced function. This pattern of treatment development for rotator cuff tendinopathy has resulted in a wide array of therapeutic options, none of which have been conclusively proven to be effective.[71] A more logical and, potentially, more effective means by which successful treatments can be developed relies upon investigation of the pathophysiology associated with the aetiology and progression of a condition. An understanding of this process provides targets for potential treatments that may permit the restriction of disease progression or effect a healing response. Despite significant scientific efforts, the large body of work investigating the characteristics underlying rotator cuff tendinopathy has been limited by the tissue samples available for analysis, preventing the development of well defined biomarkers of disease.

For the first time, the methods described in this work provide access to, and analysis of, rotator cuff tendon tissue at all stages of disease progression, before and after treatment and within an asymptomatic population. The development and application of these methods has given an insight into the entire spectrum of pathology, the response to current therapies and the potential effects of ageing on the rotator cuff. These studies offer clear direction for areas of future research and robust methods by which such investigation can be carried out. This work represents a significant step forward in the

study of rotator cuff tendinopathy and offers the potential for a greater understanding of the pathophysiology of the condition and the development and evaluation of novel therapeutic interventions.

References

[1] M Urwin, D Symmons, T Allison, T Brammah, H Busby, M Roxby, A Simmons, and G Williams. Estimating the burden of musculoskeletal disorders in the community: the comparative prevalence of symptoms at different anatomical sites, and the relation to social deprivation. *Annals of the rheumatic diseases*, 57:649–655, 1998.

[2] D van der Windt, B Koes, B de Jong, and L Bouter. Shoulder disorders in general practice: incidence, patient characteristics, and management. *Annals of the rheumatic diseases*, 54:959–964, 1995.

[3] L Linsell, J Dawson, K Zondervan, P Rose, T Randall, R Fitzpatrick, and A Carr. Prevalence and incidence of adults consulting for shoulder conditions in UK primary care; patterns of diagnosis and referral. *Rheumatology*, 45(2):215–221, 2006.

[4] D van der Windt, B Koes, A Boeke, W Devillé, and B Jong. Shoulder disorders in general practice: prognostic indicators of outcome. *The British Journal of General Practice*, 46:519–523, 1996.

[5] A Aurora, J McCarron, J P Iannotti, and K Derwin. Commercially available extracellular matrix materials for rotator cuff repairs: state of the art and future trends. *Journal of Shoulder and Elbow Surgery*, 16(5 Suppl):S171–8, September 2007.

[6] L S Oh, B R Wolf, M P Hall, B A Levy, and R G Marx. Indications for rotator cuff repair: a systematic review. *Clin Orthop Relat Res*, 455:52–63, February 2007.

[7] C Mitchell, A Adebajo, E Hay, and A Carr. Shoulder pain: diagnosis and management in primary care. *British Medical Journal*, 331(7525):1124–1128, November 2005.

[8] A J K Ostor, C Richards, A Prevost, C A Speed, and B L Hazleman. Diagnosis and relation to general health of shoulder disorders presenting to primary care. *Rheumatology*, 44:800–805, 2005.

[9] H Gray. *Anatomy of the Human Body*. 1918.

[10] A F DePalma. The classic. Surgical anatomy of the rotator cuff and the natural history of degenerative periarthritis. Surg Clin North Am. 1963;43:1507-1520. *Clin Orthop Relat Res*, 466(3):543–551, March 2008.

[11] J Clark. Tendons, ligaments, and capsule of the rotator cuff. Gross and microscopic anatomy. *The Journal of Bone and Joint Surgery (American Version)*, 74:713–725, 1992.

[12] K Birnbaum, A Prescher, and K D Heller. Anatomic and functional aspects of the kinetics of the shoulder joint capsule and the subacromial bursa. *Surgical and Radiologic Anatomy*, 20(1):41–45, 1998.

[13] T Baring, R Emery, and P Reilly. Management of rotator cuff disease: specific treatment for specific disorders. *Best practice & research Clinical rheumatology*, 21(2):279–294, April 2007.

[14] T Bunker. Rotator cuff disease. *Current Orthopaedics*, 16:223–233, 2002.

[15] E G McFarland, H S Selhi, and E Keyurapan. Clinical evaluation of impingement: what to do and what works. *The Journal of Bone and Joint Surgery (American Version)*, 88(2):432–441, February 2006.

[16] L Kessel and M Watson. The painful arc syndrome. Clinical classification as a guide to management. *Journal of Bone and Joint Surgery (British Volume)*, 59(2):166–172, May 1977.

[17] R J Hawkins and J C Kennedy. Impingement syndrome in athletes. *American Journal of Sports Medicine*, 8(3):151–158, May 1980.

[18] F W Jobe and D R Moynes. Delineation of diagnostic criteria and a rehabilitation program for rotator cuff injuries. *American Journal of Sports Medicine*, 10(6):336–339, November 1982.

[19] C S Neer. Anterior acromioplasty for the chronic impingement syndrome in the shoulder: a preliminary report. *The Journal of bone and joint surgery American volume*, 54(1):41–50, 1972.

[20] L U Bigliani, D S Morrison, and E W April. The morphology of the acromion and its relationship to rotator cuff tears. *Orthop. Trans.*, 10:228, October 1986.

[21] A Goud, D Segal, P Hedayati, J J Pan, and B N Weissman. Radiographic evaluation of the shoulder. *European Journal of Radiology*, 68(1):2–15, October 2008.

[22] T O Smith, T Back, A P Toms, and C B Hing. Diagnostic accuracy of ultrasound for rotator cuff tears in adults: a systematic review and meta-analysis. *Clinical radiology*, 66(11):1036–1048, November 2011.

[23] J O de Jesus, L Parker, A J Frangos, and L N Nazarian. Accuracy of MRI, MR arthrography, and ultrasound in the diagnosis of rotator cuff tears: a meta-analysis. *American Journal of Roentgenology*, 192(6):1701–1707, June 2009.

[24] S A Teefey, D A Rubin, W D Middleton, C F Hildebolt, R A Leibold, and K Yamaguchi. Detection and quantification of rotator cuff tears. Comparison of ultrasonographic, magnetic resonance imaging, and arthroscopic findings in seventy-one consecutive cases. *Journal of Bone and Joint Surgery (American Volume)*, 86-A(4):708–716, April 2004.

[25] A Meyer. The minuter anatomy of attrition lesions. *Journal of Bone and Joint Surgery (American Volume)*, 13:341–360, 1931.

[26] F W Jobe, R S Kvitne, and C E Giangarra. Shoulder pain in the overhand or throwing athlete. The relationship of anterior instability and rotator cuff impingement. *Orthopaedic review*, 18(9):963–975, September 1989.

[27] R P Nirschl. Rotator cuff tendinitis: basic concepts of pathoetiology. *Instructional course lectures*, 38:439–445, 1989.

[28] J Jerosch, W H Castro, H U Sons, and M Moersler. [Etiology of sub-acromial impingement syndrome–a biomechanical study]. *Beiträge zur Orthopädie und Traumatologie*, 36(9):411–418, September 1989.

[29] S Ogata and H K Uhthoff. Acromial enthesopathy and rotator cuff tear. A radiologic

and histologic postmortem investigation of the coracoacromial arch. *Clin Orthop Relat Res*, (254):39–48, May 1990.

[30] B J F Dean, S L Franklin, and A J Carr. A systematic review of the histological and molecular changes in rotator cuff disease. *Bone and Joint Research*, 1:158–166, 2012.

[31] J E Carpenter, C L Flanagan, S Thomopoulos, E H Yian, and L J Soslowsky. The effects of overuse combined with intrinsic or extrinsic alterations in an animal model of rotator cuff tendinosis. *American Journal of Sports Medicine*, 26(6):801–807, November 1998.

[32] A Kimura, M Aoki, S Fukushima, S Ishii, and K Yamakoshi. Reconstruction of a defect of the rotator cuff with polytetrafluoroethylene felt graft. Recovery of tensile strength and histocompatibility in an animal model. *Journal of Bone and Joint Surgery (British Volume)*, 85(2):282–287, March 2003.

[33] M Kobayashi, E Itoi, H Minagawa, N Miyakoshi, S Takahashi, Y Tuoheti, K Okada, and Y Shimada. Expression of growth factors in the early phase of supraspinatus tendon healing in rabbits. *Journal of Shoulder and Elbow Surgery*, 15(3):371–377, May 2006.

[34] S A Rodeo, H G Potter, S Kawamura, A S Turner, H J Kim, and B L Atkinson. Biologic augmentation of rotator cuff tendon-healing with use of a mixture of osteoinductive growth factors. *The Journal of bone and joint surgery American volume*, 89(11):2485–2497, November 2007.

[35] F M Buck, H Grehn, M Hilbe, C W A Pfirrmann, S Manzanell, and J Hodler. Magnetic resonance histologic correlation in rotator cuff tendons. *Journal of magnetic resonance imaging : JMRI*, 32(1):165–172, July 2010.

[36] M D Chard, T E Cawston, G P Riley, G A Gresham, and B L Hazleman. Rotator cuff degeneration and lateral epicondylitis: a comparative histological study. *Annals of the rheumatic diseases*, 53(1):30–34, January 1994.

[37] D Determe, M Rongières, J Kany, and J Glasson. Anatomic study of the tendinous rotator cuff of the shoulder. *Surgical and Radiologic Anatomy*, 18:195–200, 1996.

[38] M Gotoh, K Hamada, H Yamakawa, A Tomonaga, A Inoue, and H Fukuda. Significance of granulation tissue in torn supraspinatus insertions: an immunohistochemical study with antibodies against interleukin-1 beta, cathepsin D, and matrix metalloprotease-1. *Journal of orthopaedic research : official publication of the Orthopaedic Research Society*, 15(1):33–39, January 1997.

[39] A Hijioka, K Suzuki, T Nakamura, and T Hojo. Degenerative change and rotator cuff tears. An anatomical study in 160 shoulders of 80 cadavers. *Archives of orthopaedic and trauma surgery*, 112(2):61–64, 1993.

[40] J Kumagai, K Sarkar, and H K Uhthoff. The collagen types in the attachment zone of rotator cuff tendons in the elderly : an immunohistochemical study. *Journal of rheumatology*, 21(11):2096–2100, 1994.

[41] F Oliva, L Zocchi, A Codispoti, E Candi, M Celi, G Melino, N Maffulli, and U Tarantino. Transglutaminases expression in human supraspinatus tendon ruptures and in mouse tendons. *Biochemical and biophysical research communications*, 379(4):887–891, February 2009.

[42] G Riley, R Harrall, C Constant, M Chard, T E Cawston, and B L Hazleman.

Glycosaminoglycans of human rotator cuff tendons: changes with age and in chronic rotator cuff tendinitis. *Annals of the rheumatic diseases*, 53:367–376, 1994.

[43] G P Riley, M J Goddard, and B L Hazleman. Histopathological assessment and pathological significance of matrix degeneration in supraspinatus tendons. *Rheumatology (Oxford, England)*, 40(2):229–230, February 2001.

[44] G P Riley, R L Harrall, C R Constant, T E Cawston, and B L Hazleman. Prevalence and possible pathological significance of calcium phosphate salt accumulation in tendon matrix degeneration. *Annals of the rheumatic diseases*, 55(2):109–115, February 1996.

[45] G P Riley, R L Harrall, C R Constant, M D Chard, T E Cawston, and B L Hazleman. Tendon degeneration and chronic shoulder pain: changes in the collagen composition of the human rotator cuff tendons in rotator cuff tendinitis. *Annals of the rheumatic diseases*, 53(6):359–366, June 1994.

[46] Graham P Riley, Valerie Curry, Jeroen DeGroot, Benno van El, Nicole Verzijl, Brian L Hazleman, and Ruud A Bank. Matrix metalloproteinase activities and their relationship with collagen remodelling in tendon pathology. *Matrix biology : journal of the International Society for Matrix Biology*, 21(2):185–195, March 2002.

[47] C L Wilson and G L Duff. Pathologic study of degeneration and rupture of the supraspinatus tendon. *Archives of Surgery*, 47(2):121–135, 1943.

[48] R T Benson, S M McDonnell, H J Knowles, J L Rees, A J Carr, and P A Hulley. Tendinopathy and tears of the rotator cuff are associated with hypoxia and apoptosis. *Journal of Bone and Joint Surgery (British Volume)*, 92(3):448–453, March 2010.

[49] A Cole, S Cordiner-Lawrie, A Carr, and N Athanasou. Localised deposition of amyloid in tears of the rotator cuff. *Journal of Bone and Joint Surgery (British Volume)*, 83-B(4):561–564, 2001.

[50] H Fukuda, K Hamada, and K Yamanaka. Pathology and pathogenesis of bursal-side rotator cuff tears viewed from en bloc histologic sections. *Clin Orthop Relat Res*, (254):75–80, May 1990.

[51] C Goodmurphy, J Osborn, E Akesson, and S Johnson. An immunocytochemical analysis of torn rotator cuff tendon taken at the time of repair. *Journal of Shoulder and Elbow Surgery*, 12(4):368–374, 2003.

[52] D Goutallier, J-M Postel, S Van Driessche, and M-C Voisin. [Histological lesions of supraspinatus tendons in full thickness tears of the rotator cuff]. *Revue de chirurgie orthopédique et réparatrice de l'appareil moteur*, 91(2):109–113, April 2005.

[53] S Lakemeier, J Braun, T Efe, C Foelsch, E Archontidou-Aprin, S Fuchs-Winkelmann, J R J Paletta, and M D Schofer. Expression of matrix metalloproteinases 1, 3, and 9 in differing extents of tendon retraction in the torn rotator cuff. *Knee surgery, sports traumatology, arthroscopy*, 19(10):1760–1765, October 2011.

[54] S Lakemeier, J J A Reichelt, T Patzer, S Fuchs-Winkelmann, J R J Paletta, and M D Schofer. The association between retraction of the torn rotator cuff and increasing expression of hypoxia inducible factor 1 and vascular endothelial growth factor expression: an immunohistological study. *BMC musculoskeletal disorders*, 11:230, 2010.

[55] I K Y Lo, R Boorman, L Marchuk, R Hollinshead, D A Hart, and C B Frank. Matrix

molecule mRNA levels in the bursa and rotator cuff of patients with full-thickness rotator cuff tears. *Arthroscopy*, 21(6):645–651, June 2005.

[56] I K Y Lo, L L Marchuk, R Hollinshead, D A Hart, and C B Frank. Matrix metalloproteinase and tissue inhibitor of matrix metalloproteinase mRNA levels are specifically altered in torn rotator cuff tendons. *American Journal of Sports Medicine*, 32(5):1223–1229, July 2004.

[57] U G Longo, F Franceschi, L Ruzzini, C Rabitti, S Morini, N Maffulli, and V Denaro. Histopathology of the supraspinatus tendon in rotator cuff tears. *The American journal of sports medicine*, 36(3):533–538, March 2008.

[58] U G Longo, F Franceschi, L Ruzzini, C Rabitti, S Morini, N Maffulli, F Forriol, and V Denaro. Light microscopic histology of supraspinatus tendon ruptures. *Knee surgery, sports traumatology, arthroscopy*, 15(11):1390–1394, November 2007.

[59] K Lundgreen, O B Lian, L Engebretsen, and A Scott. Tenocyte apoptosis in the torn rotator cuff: a primary or secondary pathological event? *British Journal of Sports Medicine*, 45(13):1035–1039, October 2011.

[60] T J W Matthews, G Hand, J L Rees, N Athanasou, and A Carr. Pathology of the torn rotator cuff tendon Reduction in potential for repair as tear size increases. *Journal of Bone and Joint Surgery (British Volume)*, 88-B(4):489–495, 2006.

[61] N L Millar, J H Reilly, S C Kerr, A L Campbell, K J Little, W J Leach, B P Rooney, and I B McInnes. Hypoxia: a critical regulator of early human tendinopathy. *Annals of the rheumatic diseases*, 71(2):302–310, February 2012.

[62] N L Millar, A J Hueber, J H Reilly, Y Xu, U G Fazzi, G A C Murrell, and I B McInnes. Inflammation is present in early human tendinopathy. *The American journal of sports medicine*, 38(10):2085–2091, October 2010.

[63] J Premdas, J B Tang, J P Warner, M M Murray, and M Spector. The presence of smooth muscle actin in fibroblasts in the torn human rotator cuff. *Journal of orthopaedic research : official publication of the Orthopaedic Research Society*, 19(2):221–228, March 2001.

[64] I Shirachi, M Gotoh, Y Mitsui, K Nakama, K Kojima, T Okawa, F Higuchi, and K Nagata. Collagen production at the edge of ruptured rotator cuff tendon is correlated with postoperative cuff integrity. *Arthroscopy*, 27(9):1173–1179, September 2011.

[65] A Tomonaga, K Hamada, M Gotoh, H Yamakawa, K Kobayashi, and H Fukuda. Expression of procollagen alpha 1 type III mRNA in rotator cuff tears. *The Tokai journal of experimental and clinical medicine*, 25(3):125–134, October 2000.

[66] M X Wang, A Wei, J Yuan, A Clippe, A Bernard, B Knoops, and G A Murrell. Antioxidant enzyme peroxiredoxin 5 is upregulated in degenerative human tendon. *Biochemical and biophysical research communications*, 284(3):667–673, June 2001.

[67] B Wu, T de la Rosa, Q Yu, A Wang, J Xu, and M H Zheng. Cellular response and extracellular matrix breakdown in rotator cuff tendon rupture. *Archives of orthopaedic and trauma surgery*, 131(3):405–411, March 2011.

[68] Y Xu, F Bonar, and G A C Murrell. Neoinnervation in rotator cuff tendinopathy. *Sports medicine and arthroscopy review*, 19(4):354–359, December 2011.

[69] J Yuan, G A C Murrell, A-Q Wei, and M X Wang. Apoptosis in rotator cuff tendonopathy. *Journal of orthopaedic research : official publication of the Orthopaedic*

Research Society, 20(6):1372–1379, November 2002.

[70] S Chaudhury, C Holland, F Vollrath, and A J Carr. Comparing normal and torn rotator cuff tendons using dynamic shear analysis. *Journal of Bone and Joint Surgery (British Volume)*, 93(7):942–948, July 2011.

[71] R J Murphy and A J Carr. Shoulder pain. *Clinical Evidence*, 2010, 2010.

[72] R Murphy and A Carr. Management of shoulder pain in general practice. *InnovAiT*, 2(7):402–407, 2009.

[73] S Chaudhury, S E Gwilym, J Moser, and A J Carr. Surgical options for patients with shoulder pain. *Nature reviews. Rheumatology*, 6(4):217–226, April 2010.

[74] J A Coghlan, R Buchbinder, S Green, R V Johnston, and S N Bell. Surgery for rotator cuff disease. *Cochrane database of systematic reviews (Online)*, (1):CD005619, 2008.

[75] O Dorrestijn, M Stevens, J C Winters, K van der Meer, and R L Diercks. Conservative or surgical treatment for subacromial impingement syndrome? A systematic review. *Journal of Shoulder and Elbow Surgery*, 18(4):652–660, July 2009.

[76] S Ketola, J Lehtinen, I Arnala, M Nissinen, H Westenius, H Sintonen, P Aronen, Y T Konttinen, A Malmivaara, and T Rousi. Does arthroscopic acromioplasty provide any additional value in the treatment of shoulder impingement syndrome?: a two-year randomised controlled trial. *Journal of Bone and Joint Surgery (British Volume)*, 91(10):1326–1334, October 2009.

[77] World Health Organisation (WHO). International Statistical Classification of Diseases and Related Health Problems. WHO, January 1994.

[78] Office of Population Censuses and Surveys (OPCS). Classification of Surgical Operations and Procedures. OPCS, January 1987.

[79] W R Dunn, B R Schackman, C Walsh, S Lyman, E C Jones, R F Warren, and R G Marx. Variation in orthopaedic surgeons' perceptions about the indications for rotator cuff surgery. *The Journal of bone and joint surgery American volume*, 87(9):1978–1984, September 2005.

[80] M A Vitale, R R Arons, S Hurwitz, C S Ahmad, and W N Levine. The rising incidence of acromioplasty. *The Journal of bone and joint surgery American volume*, 92(9):1842–1850, August 2010.

[81] A C Colvin, N Egorova, A K Harrison, A Moskowitz, and E L Flatow. National trends in rotator cuff repair. *The Journal of bone and joint surgery American volume*, 94(3):227–233, February 2012.

[82] T Holmgren, H Bjornsson Hallgren, B Oberg, L Adolfsson, and K Johansson. Effect of specific exercise strategy on need for surgery in patients with subacromial impingement syndrome: randomised controlled study. *British Medical Journal*, 344:e787–e787, February 2012.

[83] H Ellman and S P Kay. Arthroscopic subacromial decompression for chronic impingement. Two- to five-year results. *Journal of Bone and Joint Surgery (British Volume)*, 73(3):395–398, May 1991.

[84] J M Olsewski and A D Depew. Arthroscopic subacromial decompression and rotator cuff debridement for stage II and stage III impingement. *Arthroscopy*, 10(1):61–68, February 1994.

[85] V R Patel, D Singh, P T Calvert, and J I Bayley. Arthroscopic subacromial decompression: results and factors affecting outcome. *Journal of Shoulder and Elbow Surgery*, 8(3):231–237, 1999.

[86] G M Gartsman and D P O'connor. Arthroscopic rotator cuff repair with and without arthroscopic subacromial decompression: a prospective, randomized study of one-year outcomes. *Journal of Shoulder and Elbow Surgery*, 13(4):424–426, 2004.

[87] H E Henkus, P B de Witte, R G H H Nelissen, R Brand, and E R A van Arkel. Bursectomy compared with acromioplasty in the management of subacromial impingement syndrome: a prospective randomised study. *Journal of Bone and Joint Surgery (British Volume)*, 91(4):504–510, April 2009.

[88] J B Moseley, N J Petersen, T J Menke, B A Brody, D H Kuykendall, J C Hollingsworth, C M Ashton, and N P Wray. A controlled trial of arthroscopic surgery for osteoarthritis of the knee. *The New England journal of medicine*, 347(2):81–88, July 2002.

[89] N K Poppen and P S Walker. Normal and abnormal motion of the shoulder. *The Journal of bone and joint surgery American volume*, 58(2):195–201, March 1976.

[90] A B Goldman and B Ghelman. The double-contrast shoulder arthrogram. A review of 158 studies. *Radiology*, 127(3):655–663, June 1978.

[91] J Beltran, L A Gray, J C Bools, W Zuelzer, L D Weis, and L J Unverferth. Rotator cuff lesions of the shoulder: evaluation by direct sagittal CT arthrography. *Radiology*, 160(1):161–165, July 1986.

[92] L A Mack, F A Matsen, R F Kilcoyne, P K Davies, and M E Sickler. US evaluation of the rotator cuff. *Radiology*, 157(1):205–209, October 1985.

[93] L L Seeger. Magnetic resonance imaging of the shoulder. *Clin Orthop Relat Res*, (244):48–59, July 1989.

[94] R P Karzel and S J Snyder. Magnetic resonance arthrography of the shoulder. A new technique of shoulder imaging. *Clinics in sports medicine*, 12(1):123–136, January 1993.

[95] R H Cofield. Rotator cuff disease of the shoulder. *The Journal of bone and joint surgery American volume*, 67(6):974–979, July 1985.

[96] S A Teefey, S A Hasan, W D Middleton, M Patel, R W Wright, and K Yamaguchi. Ultrasonography of the rotator cuff. A comparison of ultrasonographic and arthroscopic findings in one hundred consecutive cases. *Journal of Bone and Joint Surgery (American Volume)*, 82(4):498–504, April 2000.

[97] J Ahovuo, P Paavolainen, and P Slätis. The diagnostic value of arthrography and plain radiography in rotator cuff tears. *Acta orthopaedica Scandinavica*, 55(2):220–223, April 1984.

[98] J H Mink, E Harris, and M Rappaport. Rotator cuff tears: evaluation using double-contrast shoulder arthrography. *Radiology*, 157(3):621–623, December 1985.

[99] C Charousset, L Bellaïche, L D Duranthon, and J Grimberg. Accuracy of CT arthrography in the assessment of tears of the rotator cuff. *Journal of Bone and Joint Surgery (British Volume)*, 87(6):824–828, June 2005.

[100] W Grassi, A Farina, E Filippucci, and C Cervini. Sonographically guided procedures in rheumatology. *Seminars in arthritis and rheumatism*, 30(5):347–353, 2001.

[101] American Institute of Ultrasound in Medicine. Official Statement: Training Guidelines for the Performance of Musculoskeletal Ultrasound Examinations, November 2009.

[102] European Federation of Societies for Ultrasound in Medicine and Biology. Minimum training requirements for the practice of medical ultrasound in europe. Appendix 12: Musculoskeletal ultrasound. *Ultraschall in der Medizin*, 29(1):94–96, 2008.

[103] Board of the Faculty of Clinical Radiology. Ultrasound Training Recommendations for Medical and Surgical Specialties. *The Royal College of Radiologists*, pages 1–58, January 2005.

[104] G Allen. Shoulder ultrasound imaging-integrating anatomy, biomechanics and disease processes. *European Journal of Radiology*, 68:137–146, 2008.

[105] L A Mack, D A Nyberg, and F A Matsen. Sonographic evaluation of the rotator cuff. *Radiologic Clinics of North America*, 26(1):161–177, January 1988.

[106] H Sugaya, K Maeda, K Matsuki, and J Moriishi. Repair integrity and functional outcome after arthroscopic double-row rotator cuff repair. A prospective outcome study. *The Journal of bone and joint surgery American volume*, 89(5):953–960, May 2007.

[107] J Bishop, S Klepps, I K Lo, J Bird, J N Gladstone, and E L Flatow. Cuff integrity after arthroscopic versus open rotator cuff repair: a prospective study. *Journal of Shoulder and Elbow Surgery*, 15(3):290–299, May 2006.

[108] D W Ziegler. The use of in-office, orthopaedist-performed ultrasound of the shoulder to evaluate and manage rotator cuff disorders. *Journal of Shoulder and Elbow Surgery*, 13(3):291–297, May 2004.

[109] A Al-Shawi, R Badge, and T Bunker. The detection of full thickness rotator cuff tears using ultrasound. *Journal of Bone and Joint Surgery (British Volume)*, 90(7):889–892, July 2008.

[110] R P Ottenheijm, M J Jansen, J B Staal, A van den Bruel, R E Weijers, R A de Bie, and G-J Dinant. Accuracy of diagnostic ultrasound in patients with suspected subacromial disorders: a systematic review and meta-analysis. *Archives of physical medicine and rehabilitation*, 91(10):1616–1625, October 2010.

[111] M Jeyam, L Funk, and J Harris. Are Shoulder Surgeons Any Good at Diagnosing Rotator Cuff Tears Using Ultrasound?: A Comparative Analysis of Surgeons vs Radiologist. *International journal of shoulder surgery*, 2(1):4–6, January 2008.

[112] British Elbow and Shoulder Society. Point of Access Shoulder Ultrasound by Shoulder Surgeons, 2011.

[113] T Matthews, S Smith, C Peach, and J Rees. In vivo measurement of tissue metabolism in tendons of the rotator cuff: implications for surgical management. *Journal of Bone and Joint Surgery (British Volume)*, 89(5):633–638, 2007.

[114] J F Lohr and H K Uhthoff. The microvascular pattern of the supraspinatus tendon. *Clin Orthop Relat Res*, (254):35–38, May 1990.

[115] J Rathbun and I Macnab. The microvascular pattern of the rotator cuff. *Journal of Bone and Joint Surgery (British Volume)*, 52(3):540–553, August 1970.

[116] A Hoksrud, L Ohberg, H Alfredson, and R Bahr. Color Doppler ultrasound findings in patellar tendinopathy (jumper's knee). *The American journal of sports medicine*,

36(9):1813–1820, September 2008.

[117] A S Klauser, M Franz, R Arora, G M Feuchtner, J Gruber, M Schirmer, W R Jaschke, and M F Gabl. Detection of vascularity in wrist tenosynovitis: power doppler ultrasound compared with contrast-enhanced grey-scale ultrasound. *Arthritis research & therapy*, 12(6):R209, 2010.

[118] D Cosgrove and N Lassau. Imaging of perfusion using ultrasound. *European journal of nuclear medicine and molecular imaging*, 37 Suppl 1:S65–85, August 2010.

[119] S Feinstein. The powerful microbubble: from bench to bedside, from intravascular indicator to therapeutic delivery system, and beyond. *American Journal of Physiology- Heart and Circulatory ...*, 287:H450–H457, 2004.

[120] C Greis. Quantitative evaluation of microvascular blood flow by contrast-enhanced ultrasound (CEUS). *Clinical Hemorheology and Microcirculation*, 49(1-4):137–149, 2011.

[121] R Uchimoto, K Niwa, H Eguchi, N Kamiyama, Y Mine, T Miyazawa, and M Brautigam. In vivo kinetics of microbubbles of SH U 508 A (Levovist): comparison with indocyanine green in rabbits. *Ultrasound in Medicine & Biology*, 25(9):1365–1370, November 1999.

[122] J Lindner, J Song, A Jayaweera, and J Sklenar. Microvascular rheology of Definity microbubbles after intra-arterial and intravenous administration. *Journal of the American Society of Echocardiography*, 15:396–403, 2002.

[123] A Jones, H S Kaplan, and F Windholz. Air-contrast colon examination with colloidal barium. *Radiology*, 56(4):561–566, April 1951.

[124] J R Lindner. Microbubbles in medical imaging: current applications and future directions. *Nature reviews Drug discovery*, 3(6):527–532, June 2004.

[125] J Liu, G Wansaicheong, D Merton, and F Forsberg. Contrast-enhanced Ultrasound Imaging: State of the Art. *Journal of Medical Ultrasound*, 2005.

[126] R Eckersley, J Sedelaar, M Blomley, H Wijkstra, N M deSouza, D O Cosgrove, and J M C H delaRosette. Quantitative microbubble enhanced transrectal ultrasound as a tool for monitoring hormonal treatment of prostate cancer. *The Prostate*, 51:256–267, 2002.

[127] B Kaufmann, K Wei, and J Lindner. Contrast Echocardiography. *Current Problems in Cardiology*, 32:51–96, 2007.

[128] D Czitrom, D Karila-Cohen, E Brochet, and J Juliard. Acute assessment of microvascular perfusion patterns by myocardial contrast echocardiography during myocardial infarction: relation to timing and extent of functional recovery. *Heart*, 81:12–16, 1999.

[129] J Christiansen, H Leong-Poi, L Amiss, D Drake, S Kaul, and J R Lindner. Skin perfusion assessed by contrast ultrasound predicts tissue survival in a free flap model. *Ultrasound in Medicine & Biology*, 28(3):315–320, 2002.

[130] L Prantl, S Schreml, M Walter, P Kasprzak, A Stehr, M Nerlich, S Feurbach, and E Jung. Evaluation of microcirculation of free flaps of the lower leg by contrast harmonic imaging (CHI) with time intensity curve (TIC) analysis. *Clinical Hemorheology and Microcirculation*, 39(1):343–350, 2008.

[131] K Darge, B Zieger, W Rohrschneider, and S Ghods. Contrast-Enhanced Harmonic

Imaging for the Diagnosis of Vesicoureteral Reflux in Pediatric Patients. *American Journal of Roentgenology*, 177:1411–1415, 2001.

[132] K Darge. Voiding urosonography with US contrast agents for the diagnosis of vesicoureteric reflux in children. *Pediatric Radiology*, 38:54–63, 2008.

[133] V Spiss, A Loizides, M Plaikner, S Ostermann, S Peer, and H Gruber. Contrast Enhanced Ultrasound of the lower limb deep venous system: a technical feasibility study. Technical innovation. *Medical ultrasonography*, 13(4):267–271, December 2011.

[134] I-H Song, U Rediner, K-G Hermann, G R Burmester, and M Backhaus. Contrast-Enhanced Ultrasound for the Monitoring of the Efficacy of Intra-Articular Glucocorticosteroids in 2 Patients with Inflammatory Knee Joint Synovitis. *Ultraschall in der Medizin*, August 2012.

[135] R Adler, S Fealy, J Rudzki, W Kadrmas, N Verma, A Pearle, S Lyman, and R F Warren. Rotator Cuff in Asymptomatic Volunteers: Contrast-enhanced US Depiction of Intratendinous and Peritendinous Vascularity. *Radiology*, 248(3):954–961, 2008.

[136] J Rudzki, R Adler, R Warren, W Kadrmas, N Verma, A D Pearle, S Lyman, and S Fealy. Contrast-enhanced ultrasound characterization of the vascularity of the rotator cuff tendon: Age- and activity-related changes in the intact asymptomatic rotator cuff. *Journal of Shoulder and Elbow Surgery*, 17(1S):96S–100S, 2008.

[137] S C Gamradt, R A Gallo, R S Adler, A Maderazo, D W Altchek, R F Warren, and S Fealy. Vascularity of the supraspinatus tendon three months after repair: characterization using contrast-enhanced ultrasound. *Journal of Shoulder and Elbow Surgery*, 19(1):73–80, 2010.

[138] E R Cadet, R S Adler, R A Gallo, S C Gamradt, R F Warren, F A Cordasco, and S Fealy. Contrast-enhanced ultrasound characterization of the vascularity of the repaired rotator cuff tendon: short-term and intermediate-term follow-up. *Journal of Shoulder and Elbow Surgery*, 21(5):597–603, May 2012.

[139] T Funakoshi, N Iwasaki, T Kamishima, M Nishida, Y Ito, M Kondo, and A Minami. In vivo visualization of vascular patterns of rotator cuff tears using contrast-enhanced ultrasound. *The American journal of sports medicine*, 38(12):2464–2471, December 2010.

[140] F Piscaglia, C Nolsoe, C F Dietrich, D O Cosgrove, O H Gilja, M Bachmann Nielsen, T Albrecht, L Barozzi, M Bertolotto, O Catalano, M Claudon, D A Clevert, J M Correas, M D'Onofrio, F M Drudi, J Eyding, M Giovannini, M Hocke, A Ignee, E M Jung, A S Klauser, N Lassau, E Leen, G Mathis, A Saftoiu, G Seidel, P S Sidhu, G ter Haar, D Timmerman, and H P Weskott. The EFSUMB Guidelines and Recommendations on the Clinical Practice of Contrast Enhanced Ultrasound (CEUS): update 2011 on non-hepatic applications. *Ultraschall in der Medizin*, 33(1):33–59, February 2012.

[141] Douglas L Miller, Michalakis A Averkiou, Andrew A Brayman, E Carr Everbach, Christy K Holland, James H Wible, and Junru Wu. Bioeffects considerations for diagnostic ultrasound contrast agents. *Journal of ultrasound in medicine : official journal of the American Institute of Ultrasound in Medicine*, 27(4):611–32– quiz 633–6, April 2008.

[142] Bracco. Investigators Brochure SonoVue. January 2007.

[143] M Krix. Quantification of enhancement in contrast ultrasound: a tool for monitoring of therapies in liver metastases. *European radiology*, 15 Suppl 5:E104–8, December 2005.

[144] B Kaufmann and J Lindner. Molecular imaging with targeted contrast ultrasound. *Current Opinion in Biotechnology*, 2007.

[145] K Ferrara, R Pollard, and M Borden. Ultrasound Microbubble Contrast Agents: Fundamentals and Application to Gene and Drug Delivery. *ANNUAL REVIEW OF BIOMEDICAL ENGINEERING*, 2007.

[146] K Lundgreen, Ø Lian, A Scott, and L Engebretsen. Increased levels of apoptosis and p53 in partial-thickness supraspinatus tendon tears. *Knee surgery, sports traumatology, arthroscopy : official journal of the ESSKA*, October 2012.

[147] M K Shindle, C C T Chen, C Robertson, A E DiTullio, M C Paulus, C M Clinton, F A Cordasco, S A Rodeo, and R F Warren. Full-thickness supraspinatus tears are associated with more synovial inflammation and tissue degeneration than partial-thickness tears. *Journal of Shoulder and Elbow Surgery*, 20(6):917–927, September 2011.

[148] D H Sonnabend, Y Yu, C R Howlett, G D Harper, and W R Walsh. Laminated tears of the human rotator cuff: a histologic and immunochemical study. *Journal of Shoulder and Elbow Surgery*, 10(2):109–115, March 2001.

[149] B Tillander, L Franzén, and R Norlin. Fibronectin, MMP-1 and histologic changes in rotator cuff disease. *Journal of orthopaedic research : official publication of the Orthopaedic Research Society*, 20(6):1358–1364, November 2002.

[150] Y Tuoheti, E Itoi, R L Pradhan, I Wakabayashi, S Takahashi, H Minagawa, M Kobayashi, K Okada, and Y Shimada. Apoptosis in the supraspinatus tendon with stage II subacromial impingement. *Journal of Shoulder and Elbow Surgery*, 14(5):535–541, September 2005.

[151] R T Benson, S McDonnell, J L Rees, N Athanasou, and A Carr. The morphological and immunocytochemical features of impingement syndrome and partial-thickness rotator cuff tear in relation to outcome after subacromial decompression. *Journal of Bone and Joint Surgery (British Volume)*, 91-B(1):119–123, 2009.

[152] P Jennings, J Donald, A Coral, J Rode, and W Lees. Ultrasound-guided core biopsy. *Lancet*, pages 1369–1371, June 1989.

[153] T Movin, P Guntner, A Gad, and C Rolf. Ultrasonography-guided percutaneous core biopsy in Achilles tendon disorder. *Scandinavian Journal of Medicine & Science in Sports*, 7:244–248, 1997.

[154] T Movin. Tendon tissue sampling. *Scandinavian Journal of Medicine & Science in Sports*, 10:368–371, 2000.

[155] J Kartus, T Movin, and N Papadogiannakis. A Radiographic and Histologic Evaluation of the Patellar Tendon after Harvesting Its Central Third. *The American journal of sports medicine*, 28:218–226, 2000.

[156] M Liden, T Movin, L Ejerhed, N Papadogiannakis, E Blomen, K Hultenby, and J Kartus. A Histological and Ultrastructural Evaluation of the Patellar Tendon 10 Years After Reharvesting Its Central Third. *American Journal of Sports Medicine*, 36:781–788, 2008.

[157] B E Sullivan, C C Carroll, B Jemiolo, S W Trappe, S P Magnusson, S Dossing, M Kjaer, and T A Trappe. Effect of acute resistance exercise and sex on human patellar tendon structural and regulatory mRNA expression. *Journal of applied physiology*, 106(2):468–475, February 2009.

[158] S-M Vimpeli, I Saarenmaa, H Huhtala, and S Soimakallio. Large-core needle biopsy versus fine-needle aspiration biopsy in solid breast lesions: comparison of costs and diagnostic value. *Acta radiologica (Stockholm, Sweden : 1987)*, 49(8):863–869, October 2008.

[159] P G Lindgren. Percutaneous needle biopsy. A new technique. *Acta radiologica: diagnosis*, 23(6):653–656, 1982.

[160] J A Pang, V Tsang, B L Hom, and C Metreweli. Ultrasound-guided tissue-core biopsy of thoracic lesions with Trucut and Surecut needles. *Chest*, 91(6):823–828, June 1987.

[161] A Damera, A J Evans, E J Cornford, A R M Wilson, H C Burrell, J J James, S E Pinder, I O Ellis, A H S Lee, and R D Macmillan. Diagnosis of axillary nodal metastases by ultrasound-guided core biopsy in primary operable breast cancer. *British Journal of Cancer*, 89(7):1310–1313, October 2003.

[162] D C Howlett, L Menezes, D J Bell, I Ahmed, T Witcher, N Bhatti, K Ramesar, and M D Williams. Ultrasound-guided core biopsy for the diagnosis of lumps in the neck: results in 82 patients. *The British journal of oral & maxillofacial surgery*, 44(1):34–37, February 2006.

[163] B D Fornage, J D Coan, and C L David. Ultrasound-guided needle biopsy of the breast and other interventional procedures. *Radiologic Clinics of North America*, 30(1):167–185, January 1992.

[164] G Schueller, C Schueller-Weidekamm, and T Helbich. Accuracy of ultrasound-guided, large-core needle breast biopsy. *European radiology*, 18:1761–1773, 2008.

[165] A Turner. Experiences with sheep as an animal model for shoulder surgery: Strengths and shortcomings. *Journal of Shoulder and Elbow Surgery*, 16:158S–163S, 2007.

[166] S Coleman, S Fealy, J Ehteshami, and J MacGillivray. Chronic Rotator Cuff Injury and Repair Model in Sheep. *Journal of Bone and Joint Surgery (American Volume)*, 85:2391–2402, 2003.

[167] K V Iserson. The origins of the gauge system for medical equipment. *The Journal of emergency medicine*, 5(1):45–48, 1987.

[168] K E Fredfeldt. An easily made ultrasound biopsy phantom. *Journal of ultrasound in medicine : official journal of the American Institute of Ultrasound in Medicine*, 5(5):295–297, May 1986.

[169] B Silver, T S Metzger, and T A Matalon. A simple phantom for learning needle placement for sonographically guided biopsy. *American Journal of Roentgenology*, 154(4):847–848, April 1990.

[170] B D Fornage. A simple phantom for training in ultrasound-guided needle biopsy using the freehand technique. *Journal of ultrasound in medicine : official journal of the American Institute of Ultrasound in Medicine*, 8(12):701–703, December 1989.

[171] M P McNamara and M E McNamara. Preparation of a homemade ultrasound biopsy phantom. *Journal of clinical ultrasound : JCU*, 17(6):456–458, July 1989.

[172] R A Nicholson and M Crofton. Training phantom for ultrasound guided biopsy. *The British journal of radiology*, 70:192–194, February 1997.

[173] G A Sisney and K A Hunt. A low-cost gelatin phantom for learning sonographically guided interventional breast radiology techniques. *American Journal of Roentgenology*, 171(1):65–66, July 1998.

[174] R O Bude and R S Adler. An easily made, low-cost, tissue-like ultrasound phantom material. *Journal of clinical ultrasound : JCU*, 23(4):271–273, May 1995.

[175] H Mike Kim, Nirvikar Dahiya, Sharlene A Teefey, William D Middleton, Georgia Stobbs, Karen Steger-May, Ken Yamaguchi, and Jay D Keener. Location and initiation of degenerative rotator cuff tears: an analysis of three hundred and sixty shoulders. *The Journal of bone and joint surgery American volume*, 92(5):1088–1096, May 2010.

[176] R E Cotton and D F Rideout. Tears of the Humeral Rotator Cuff; a Radiological and Pathological Necropsy Survey. *Journal of Bone and Joint Surgery (British Volume)*, 46:314–328, May 1964.

[177] M J Skyhar, D W Altchek, R F Warren, T L Wickiewicz, and S J O'Brien. Shoulder arthroscopy with the patient in the beach-chair position. *Arthroscopy*, 4(4):256–259, 1988.

[178] A Lewis, T Kitamura, and J I L Bayley. (ii) The classification of shoulder instability: new light through old windows! *Current Orthopaedics*, 18(2):97–108, April 2004.

[179] Her Majesty's Stationery Office. Human Tissue Act 2004.

[180] L Fina, H V Molgaard, D Robertson, N J Bradley, P Monaghan, D Delia, D R Sutherland, M A Baker, and M F Greaves. Expression of the CD34 gene in vascular endothelial cells. *Blood*, 75(12):2417–2426, June 1990.

[181] I S Trowbridge, R Hyman, and C Mazauskas. Surface molecules of cultured human lymphoid cells. *European journal of immunology*, 6(11):777–782, November 1976.

[182] L C Andersson, C Wasastjerna, and C G Gahmberg. Different surface glycoprotein patterns on human T-, B- and leukemic-lymphocytes. *International journal of cancer. Journal international du cancer*, 17(1):40–46, January 1976.

[183] L C Andersson and C G Gahmberg. Surface glycoproteins of human white blood cells. Analysis by surface labeling. *Blood*, 52(1):57–67, July 1978.

[184] J Gerdes, U Schwab, H Lemke, and H Stein. Production of a mouse monoclonal antibody reactive with a human nuclear antigen associated with cell proliferation. *International journal of cancer. Journal international du cancer*, 31(1):13–20, January 1983.

[185] J Gerdes, H Lemke, H Baisch, H H Wacker, U Schwab, and H Stein. Cell cycle analysis of a cell proliferation-associated human nuclear antigen defined by the monoclonal antibody Ki-67. *Journal of immunology (Baltimore, Md. : 1950)*, 133(4):1710–1715, October 1984.

[186] I Hadjiloucas, A P Gilmore, N J Bundred, and C H Streuli. Assessment of apoptosis in human breast tissue using an antibody against the active form of caspase 3: relation to tumour histopathological characteristics. *British Journal of Cancer*, 85(10):1522–1526, November 2001.

[187] J Schindelin, I Arganda-Carreras, E Frise, V Kaynig, M Longair, T Pietzsch,

S Preibisch, C Rueden, S Saalfeld, B Schmid, J Tinevez, D White, V Hartenstein, K Eliceiri, P Tomancak, and A Cardona. Fiji: an open-source platform for biological-image analysis. *Nature methods*, 9(7):676–682, July 2012.

[188] B Andres and G Murrell. Treatment of Tendinopathy: What Works, What Does Not, and What is on the Horizon. *Clin Orthop Relat Res*, 466:1539–1554, 2008.

[189] H Alfredson. The chronic painful Achilles and patellar tendon: research on basic biology and treatment. *Scandinavian Journal of Medicine & Science in Sports*, 15(4):252–259, August 2005.

[190] R Ainsworth and J S Lewis. Exercise therapy for the conservative management of full thickness tears of the rotator cuff: a systematic review. *British Journal of Sports Medicine*, 41(4):200–210, April 2007.

[191] S Green, R Buchbinder, and S Hetrick. Acupuncture for shoulder pain (Review). *The Cochrane database of systematic reviews*, 2005.

[192] R Buchbinder, S Green, and J M Youd. Corticosteroid injections for shoulder pain. *The Cochrane database of systematic reviews*, (1):CD004016, 2003.

[193] S Green, R Buchbinder, and R Glazier. Systematic review of randomised controlled trials of interventions for painful shoulder: selection criteria, outcome assessment, and efficacy. *British Medical Journal*, 316:354–360, 1998.

[194] B J Cole, L P McCarty, R W Kang, W Alford, P B Lewis, and J K Hayden. Arthroscopic rotator cuff repair: prospective functional outcome and repair integrity at minimum 2-year follow-up. *Journal of Shoulder and Elbow Surgery*, 16(5):579–585, 2007.

[195] K Anderson, M Boothby, D Aschenbrener, and M van Holsbeeck. Outcome and structural integrity after arthroscopic rotator cuff repair using 2 rows of fixation: minimum 2-year follow-up. *The American journal of sports medicine*, 34(12):1899–1905, December 2006.

[196] L M Galatz, C M Ball, S A Teefey, W D Middleton, and K Yamaguchi. The outcome and repair integrity of completely arthroscopically repaired large and massive rotator cuff tears. *The Journal of bone and joint surgery American volume*, 86-A(2):219–224, February 2004.

[197] J E Kuhn. Exercise in the treatment of rotator cuff impingement: a systematic review and a synthesized evidence-based rehabilitation protocol. *Journal of Shoulder and Elbow Surgery*, 18(1):138–160, 2009.

[198] J Dawson, R Fitzpatrick, and A J Carr. Questionnaire on the perceptions of patients about shoulder surgery. *Journal of Bone and Joint Surgery (British Volume)*, 78-B(4):593–600, 1996.

[199] B K Coombes, L Bisset, and B Vicenzino. Efficacy and safety of corticosteroid injections and other injections for management of tendinopathy: a systematic review of randomised controlled trials. *Lancet*, 376(9754):1751–1767, November 2010.

[200] A Scott and K M Khan. Corticosteroids: short-term gain for long-term pain? *The Lancet*, 376(9754):1714–1715, November 2010.

[201] A S Wei, J J Callaci, D Juknelis, G Marra, P Tonino, K B Freedman, and F H Wezeman. The effect of corticosteroid on collagen expression in injured rotator cuff tendon. *The Journal of bone and joint surgery American volume*, 88(6):1331–1338, June 2006.

[202] N Scutt, C G Rolf, and A Scutt. Glucocorticoids inhibit tenocyte proliferation and Tendon progenitor cell recruitment. *Journal of orthopaedic research : official publication of the Orthopaedic Research Society*, 24(2):173–182, February 2006.

[203] M W N Wong, Y Y N Tang, S K M Lee, and B S C Fu. Glucocorticoids suppress proteoglycan production by human tenocytes. *Acta orthopaedica*, 76(6):927–931, December 2005.

[204] M W N Wong, Y Y N Tang, S K M Lee, B S C Fu, B P Chan, and C K M Chan. Effect of dexamethasone on cultured human tenocytes and its reversibility by platelet-derived growth factor. *The Journal of bone and joint surgery American volume*, 85-A(10):1914–1920, October 2003.

[205] N Z Baboldashti, R C Poulsen, S L Franklin, M S Thompson, and P A Hulley. Platelet-rich plasma protects tenocytes from adverse side effects of dexamethasone and ciprofloxacin. *The American journal of sports medicine*, 39(9):1929–1935, September 2011.

[206] R C Poulsen, A J Carr, and P A Hulley. Protection against glucocorticoid-induced damage in human tenocytes by modulation of ERK, Akt, and forkhead signaling. *Endocrinology*, 152(2):503–514, February 2011.

[207] P Torricelli, M Fini, G Giavaresi, A Carpi, A Nicolini, and R Giardino. Effects of systemic glucocorticoid administration on tenocytes. *Biomedicine & pharmacotherapy = Biomédecine & pharmacothérapie*, 60(8):380–385, September 2006.

[208] S Moosmayer, H-J Smith, R Tariq, and A Larmo. Prevalence and characteristics of asymptomatic tears of the rotator cuff: an ultrasonographic and clinical study. *Journal of Bone and Joint Surgery (British Volume)*, 91(2):196–200, February 2009.

[209] E A Codman and I B Akerson. The Pathology Associated with Rupture of the Supraspinatus Tendon. *Annals of surgery*, 93(1):348–359, January 1931.

[210] P Lloyd-Sherlock, M McKee, S Ebrahim, M Gorman, S Greengross, M Prince, R Pruchno, G Gutman, T Kirkwood, D O'Neill, L Ferrucci, S B Kritchevsky, and B Vellas. Population ageing and health. *Lancet*, 379(9823):1295–1296, April 2012.

[211] Ageing well: a global priority. *Lancet*, 379(9823):1274, April 2012.

[212] B J Seligman, M R Cullen, and R I Horwitz. Aging, transition, and estimating the global burden of disease. *PloS one*, 6(5):e20264, 2011.

[213] CJL Murray and A D Lopez. Alternative projections of mortality and disability by cause 1990-2020: Global Burden of Disease Study. *Lancet*, 349:1498–1504, 1997.

[214] JR Edwards, K Zainabadi, ST Lwin, and E Elefteriou. The longevity gene SIRT-1 independently controls both osteoblast and osteoclast function. In *American Society of Bone and Mineral Research 30th Annual Meeting*. J Bone Miner Res, 2008.

[215] O Fernandez-Capetillo. Sirt1 improves healthy ageing and protects from metabolic syndrome-associated cancer. *NATURE*.

[216] V D Longo and B K Kennedy. Sirtuins in Aging and Age-Related Disease. *Cell*, 126(2):257–268, July 2006.

[217] J H Oh, S H Kim, J Y Kang, C H Oh, and H S Gong. Effect of age on functional and structural outcome after rotator cuff repair. *The American journal of sports medicine*, 38(4):672–678, April 2010.

Appendix A

OPCS-4 and ICD-10 codes

The following codes were used to identify completed consultant episodes from the Hospital Episode Statistics Database between 2000 and 2012 that included subacromial decompression and/or rotator cuff repair. Three groups were identified from the episodes collected:

i. those containing subacromial decompression only

ii. those containing rotator cuff repair and subacromial decompression

iii. those containing rotator cuff repair only

As the OPCS-4 coding system was updated from OPCS-4·2 in the year 2000 through to OPCS-4·6 in the year 2011, a specific series of codes and search terms were used for each new version of the coding system.

A.1 Subacromial Decompression Codes

Any of these ICD-10 diagnosis codes		Any of these OPCS-4 procedure codes
M75·1	In combination with...	W84·8
M75·3		Y52·8
M75·4		
M75·5		

Table A.1: ICD-10 and OPCS-4·2 codes used to identify subacromial decompression surgery between 2000–06.

Any of these ICD-10 diagnosis codes		Any of these OPCS-4 procedure codes
M75·1	In combination with...	W84·8
M75·3		Y52·8
M75·4		Y76·7
M75·5		

Table A.2: ICD-10 and OPCS-4·3 codes used to identify subacromial decompression surgery between 2006–07.

Any of these ICD-10 diagnosis codes		Any of these OPCS-4 procedure codes
M75·1	In combination with...	W84·8
M75·3		Y52·8
M75·4		Y76·7
M75·5		W84·4

Table A.3: ICD-10 and OPCS-4·4 codes used to identify subacromial decompression surgery between 2007–09.

Search 1:

Any of these ICD-10 diagnosis codes		Any of these OPCS-4 procedure codes
M75·1	In combination with...	W84·8
M75·3		Y52·8
M75·4		Y76·7
M75·5		W84·4

Search 2:

This OPCS-4 procedure code
O29·1

The total episode count for this period was calculated as the sum of the counts from Search 1 and Search 2, although duplicates were only counted once.

Table A.4: ICD-10 and OPCS-4·5 and OPCS-4·6 codes used to identify subacromial decompression surgery between 2009–12.

A.2 Rotator Cuff Repair Codes

This OPCS-4 procedure code
T79·1

Table A.5: OPCS-4·2 codes used to identify rotator cuff repair surgery between 2000–06.

These OPCS-4 procedure codes
T79·1
T79·3

Table A.6: OPCS-4·3 and OPCS-4·4 codes used to identify rotator cuff repair surgery between 2006–09.

These OPCS-4 procedure codes
T79·1
T79·3
T79·4
T79·5

Table A.7: OPCS-4·5 and OPCS-4·6 codes used to identify rotator cuff repair surgery between 2009–12.

Appendix B

Histopathology Methods

B.1 Tissue Processing

All tissue samples were placed into a solution of 10% buffered formalin solution immediately after the biopsy was obtained. The samples were labelled with a randomly generated number to ensure blinding of the staining and analysis process and were stored at room temperature for one week to be fixed. The formalin fixed samples were then embedded in paraffin to permit sectioning and were orientated to be sectioned in a longitudinal direction. Sectioning of paraffin blocked samples were undertaken using a Leica®-LM microtome (Leica Microsystems, Wetzler, Germany); 3μm sections were obtained and placed onto X-tra® adhesive glass slides (Leica Biosystems, Peterborough, United Kingdom) and labelled with the same identification number as the parent biopsy. The slides were baked overnight at 50°C.

B.2 Staining

For each of the staining and immunohistochemistry protocols the slides were processed a batch i.e. the staining process was not undertaken until all samples had been obtained, fixed, embedded, sectioned and baked. This allowed for consistency of method between slides and ensured the most efficient and economical use of time and resources.

Prior to each staining method the slides were de-waxed in xylene solution for 5 minutes before being hydrated through reducing concentrations of industrial methylated spirits (IMS), thorough washing in each solution (100%, 90%, 70%, water). Once in 70% IMS, the following protocols were used for each stain and immunohistochemistry antibody application. The procedures were standardised by using an automated, computer controlled staining machine to minimise human error in the procedure (Dako Autostainer - Dako UK, Ely, Cambridge, UK).

B.2.1 Haematoxilin and Eosin

Procedure:

1. Hydrate in distilled water and rinse thoroughly
2. Stain with Mayer's haematoxilin for 5 minutes
3. Wash in tap water
4. Blue in 2% sodium hydrogen carbonate for 5 seconds
5. Wash in tap water
6. Stain in 1% eosin for 5 minutes
7. Wash in tap water
8. Finish slides according to procedure listed in section B.2.8

B.2.2 CD34 Antibody - Vascular Endothelium

Procedure:

1. Block endogenous peroxidase in 0·6% hydrogen peroxide in 80% IMS solution for 30 minutes
2. Wash with tap water
3. Wash well with Tris buffered saline
4. Incubate for 30 minutes with 200μL CD34 primary antibody (Dako CD34 (QBend10) antibody solution diluted to 1:50 concentration)
5. Wash several times with Tris buffered saline
6. Proceed with secondary antibody and DAB staining as per procedure in section B.2.7

Control tissue: Colon

B.2.3 CD45 Antibody - Leucocyte Common Antigen

Procedure:

1. Block endogenous peroxidase in 0·6% hydrogen peroxide in 80% IMS solution for 30 minutes
2. Wash with tap water
3. Place slides in plastic rack and immerse in Tris/EDTA buffer solution
4. Microwave at full power in 800 Watt microwave for 10 minutes
5. Wash with distilled water
6. Wash well with Tris buffered saline
7. Incubate for 30 minutes with 200μL CD45 primary antibody (Dako CD45 (Leucocyte Common Antigen) antibody solution diluted to 1:50 concentration)
8. Wash several times with Tris buffered saline
9. Proceed with secondary antibody and DAB staining as per procedure in section B.2.7

Control tissue: Colon

B.2.4 MIB-1 (Ki-67) Antibody

Procedure:

1. Block endogenous peroxidase in 0·6% hydrogen peroxide in 80% IMS solution for 30 minutes
2. Wash with tap water
3. Place slides in plastic rack and immerse in Tris/EDTA buffer solution
4. Microwave at full power in 800 Watt microwave for 10 minutes
5. Pour away and renew Tris/EDTA buffer solution
6. Microwave at full power in 800 Watt microwave for 10 minutes
7. Wash with distilled water
8. Wash well with Tris buffered saline
9. Incubate for 30 minutes with 200μL MIB-1 primary antibody (Dako MIB-1 (Ki-67) antibody solution diluted to 1:200 concentration)
10. Wash several times with Tris buffered saline
11. Proceed with secondary antibody and DAB staining as per procedure in section B.2.7

Control tissue: Tonsil

B.2.5 Active Caspase-3 Antibody

Procedure:

1. Block endogenous peroxidase in 0·6% hydrogen peroxide in 80% IMS solution for 30 minutes
2. Wash with tap water
3. Place slides in plastic rack and immerse in Tris/EDTA buffer solution
4. Microwave at full power in 800 Watt microwave for 10 minutes
5. Pour away and renew Tris/EDTA buffer solution
6. Microwave at full power in 800 Watt microwave for 10 minutes
7. Wash with distilled water
8. Wash well with Tris buffered saline
9. Incubate for 30 minutes with 200μL Active Caspase-3 primary antibody (R&D Systems Active Caspase-3 antibody solution diluted to 1:500 concentration)
10. Wash several times with Tris buffered saline
11. Proceed with secondary antibody and DAB staining as per procedure in section B.2.7

Control tissue: Appendix

B.2.6 Sirtuin-1 Antibody

Procedure:

1. Block endogenous peroxidase in 0·6% hydrogen peroxide in 80% IMS solution for 30 minutes
2. Wash with tap water
3. Place slides in plastic rack and immerse in Tris/EDTA buffer solution
4. Microwave at full power in 800 Watt microwave for 10 minutes
5. Pour away and renew Tris/EDTA buffer solution
6. Microwave at full power in 800 Watt microwave for 10 minutes
7. Wash with distilled water
8. Wash well with Tris buffered saline
9. Incubate for 30 minutes with 200μL Sirtuin-1 primary antibody (Abnova Sirtuin-1 antibody solution diluted to 1:250 concentration)
10. Wash several times with Tris buffered saline
11. Proceed with secondary antibody and DAB staining as per procedure in section B.2.7

Control tissue: Appendix

B.2.7 Envision Kit

Procedure:

1. Incubate for 30 minutes with 200μL secondary rabbit/mouse antibody (Dako^{TM} REAL^{TM} EnVision Kit)
2. Wash several times with Tris buffered saline
3. Incubate for 5 minutes in freshly prepared DAB solution (Dako^{TM} REAL^{TM} EnVision Kit)
4. Wash well with distilled water
5. Counter stain in Mayer's Haematoxilin for 3 minutes
6. Blue in 2% sodium hydrogen carbonate solution for 20 seconds
7. Finish slides according to procedure listed in section B.2.8

B.2.8 Finishing and Storage

Procedure:

1. Dehydrate in IMS: thorough washing in each solution of 70%, 90% and 100% alcohol
2. Clear in xylene solution for 5 minutes
3. Mount in DPX solution and fit glass cover slip
4. Allow to set with slides stored horizontally overnight
5. Label slides with unique identifying barcode sticker (Pro-Curo sample number)
6. Store in boxes containing batches of a single stain type to facilitate efficient imaging