

# ANTIQUITY

a review of world archaeology



**CAMBRIDGE**  
UNIVERSITY PRESS

**Summary justice or the King's will? The first case of formal facial mutilation from Anglo-Saxon England**

Journal:	<i>Antiquity</i>
Manuscript ID	AQY-RE-19-132.R2
Manuscript Type:	Research
Date Submitted by the Author:	n/a
Complete List of Authors:	Cole, Garrard; University College London, Institute of Archaeology Ditchfield, Peter; University of Oxford, Research Laboratory for Archaeology, School of Archaeology Dulias, Katharina; University of York, Department of Archaeology Edwards, Ceiridwen; University of Huddersfield, Department of Biological Sciences Reynolds, Andrew; University College London, Institute of Archaeology Waldron, Tony; University College London, Institute of Archaeology
Keywords:	Anglo Saxon, facial mutilation, Law codes
Research Region:	Britain & Ireland

SCHOLARONE™  
Manuscripts

**Title:****Summary justice or the King's will? The first case of formal facial mutilation from  
Anglo-Saxon England****Authors:**

Garrard Cole<sup>1</sup>

Peter W. Ditchfield<sup>2</sup>

Katharina Dulias<sup>3,4</sup>

Ceiridwen J. Edwards<sup>2,3</sup>

Andrew Reynolds<sup>1</sup>

Tony Waldron<sup>1</sup>

**Affiliations:**

1. Institute of Archaeology, University College London, 31-34 Gordon Square, London WC1H 0PY, United Kingdom

2. Research Laboratory for Archaeology, School of Archaeology, University of Oxford, 1 South Parks Road, Oxford OX1 3TG, United Kingdom

3. Department of Biological and Geographical Sciences, School of Applied Sciences, University of Huddersfield, Joseph Priestley Building, Queensgate, Huddersfield HD1 3DH, United Kingdom

4. Current address: Department of Archaeology, University of York, BioArCh Environment Building, Wentworth Way, York YO10 5DD, United Kingdom

## Abstract

*This paper presents the first archaeological evidence for specific facial mutilation from Anglo-Saxon England, involving removal of the nose, upper lip and possible scalping, inflicted upon a young adult female of about 18 years of age. The injuries are consistent with documented punishments for female thieving slaves and adulteresses. Although mutilations of this kind do not appear in the written record until the tenth century AD, the instance reported here suggests that the practice emerged a century earlier. This case is examined against a wider consideration of the motivations and meaning of facial disfigurement in past societies.*

## Introduction

There is extensive evidence for mutilation of the human cranium, both intentional and incidental, in both past societies and contemporary ones. Archaeological traces of specific, pre-meditated, injuries include decapitation, either pre-, peri- or post-mortem, modification of the teeth, and trepanation, while less co-ordinated trauma can result from accidents and interpersonal violence (Geldof 2015; Mays 1996; Nikolić *et al.* 2017; Stuckert & Kricun 2011). This evidence covers a wide time span, from dynastic Egypt up to modern times, with locations being widespread, including the Far East, Asia, North and South America, the Middle East, Africa and Europe (Sperati 2009, with qualifying comments from Van Der Graaf 2009). Sperati (2009) notes that mutilation has commonly been applied to the limb extremities and the head, but the face especially serves as a brutally obvious medium for marking out certain individuals from others. This is because the human face is not only defined by the morphology of underlying bone, muscle and fat, but soft tissues, such as those forming the ears, nose, and lips, all serve to make each face distinct, facilitating social communication and allowing the expression of emotions.

The widespread and long established practice of facial mutilation is also evidenced by early techniques of plastic surgery. Damage to the nose by whatever means – punishment, fighting, duelling, or by accident – led to early attempts at both aesthetic (Lupo 1997) and total (Mazzolo & Marcus 1983) reconstruction to try to restore the appearance of the face (see Arora *et al.* 2017 for a comprehensive review). The earliest operations seem to have originated in India (Brain 1988; Tewari & Shukla 2005), where surgeons, following the ideas

1  
2  
3 of Sushruta recorded around 600 BC, used cheek and forehead flaps to reconstruct the nose.  
4  
5 The success of the operation must have been variable given the opportunity for infection, but  
6  
7 the first published account of the operation in the west, in 1794 in the *Gentleman's Magazine*,  
8  
9 was accompanied by an illustration of a patient whose nose had been successfully restored  
10  
11 (BL 1794).

12  
13 Whilst there is some archaeological evidence for intentional mutilation of limbs  
14 (Brothwell & Møller-Christensen 1963; Fernades et al. 2017), there is limited evidence for  
15 facial mutilation; most likely because it may have only affected soft tissues without leaving  
16 traces on the skeleton. Early excavations of a Romano-British site at Lowbury Hill, Berkshire  
17 (Atkinson 1916), uncovered supposedly mutilated facial bones, but these should be treated  
18 with caution as the effects of taphonomic change were not fully understood at this time.  
19 Possible evidence of scalping has been reported at the Romano-British sites of Wroxeter  
20 (Barker 1981) and St. Albans (Mays & Steele 1996); although the Wroxeter case appears to  
21 be an example of possible frontal scalping, the St. Albans example is now considered to  
22 result from post-mortem defleshing on account of the large number (> 90) of presumed cut  
23 marks over the surface of the skull (Niblett 1999). Anglo-Saxon examples of skulls with cuts  
24 to the head and face are also known (for example from Eccles, Kent, and Maiden Castle,  
25 Dorset), but the random nature of these injuries is best explained as a function of fighting  
26 with edged weapons or as the result of an attack on a defenceless person (Brothwell 1971;  
27 Wenham 1989). A mutilated skull from Eustace Street, Dublin, dating to post-AD 1600,  
28 exhibits probable loss of the nose (Carty 2015), but it appears to have been cleaved in more  
29 than one plane and thus fits better into a 'non-specific' category of mutilation (Carty 2015, 3,  
30 11). Evidence for removal of the external ear is less forthcoming, probably because the  
31 pinnae could readily be removed by a sharp knife blade running parallel to the skull without  
32 leaving a trace on the underlying bone. One example is reported in skeleton 171 from the  
33 Late Anglo-Saxon cemetery at North Elmham, Norfolk (Wade-Martins 1980, 365-7).  
34 However, there seems to be more to this event than simple ear removal, as part of the  
35 temporal bone had also been removed by a sharp bladed weapon. This would probably have  
36 been fatal owing to the resultant damage to the middle meningeal blood vessels, and exposure  
37 of brain tissue. Another potential case is reported at medieval Jewbury, York. Again multiple  
38 unhealed cuts using a heavy sharp bladed weapon are reported on a young female. The ears  
39 may have been removed but probably not through prime intent (McComish 2000).  
40  
41  
42  
43  
44  
45  
46  
47  
48  
49  
50  
51  
52  
53  
54  
55  
56  
57  
58  
59  
60

1  
2  
3 This paper, by contrast, considers a human cranium with evidence for specific and  
4 formalised facial mutilation in the form of total removal of the nose and partial removal of  
5 the upper lip, with possible frontal scalping.  
6  
7

### 8 **The Oakridge cranium: archaeological context and dating**

9  
10  
11 The cranium in question was recovered in the 1960s during rescue excavations prior to  
12 housing development at Oakridge, Basingstoke, Hampshire, England (**Figure 1**). Restricted  
13 archaeological intervention was permitted, with limited recording of archaeological features  
14 and partial recovery of finds, with the exception of a carefully excavated well and a burial of  
15 Romano-British date (Oliver 1993). The Romano-British burial was discovered accidentally  
16 during excavation of a drainage inspection pit by a mechanical excavator. For some unknown  
17 reason, a further cranium recovered from the spoil, our Oakridge individual, was not analysed  
18 at the time. The nature of the recovery of the cranium means that we do not know if it derived  
19 from a complete body or whether the head had been removed, perhaps for the purposes of  
20 display prior to burial.  
21  
22

23  
24  
25 At the time of examination for the present paper, the cranium had not been cleaned  
26 and the cranium interior, orbits, nasal cavity and tooth sockets were filled with a distinctive  
27 fine dark brown sandy silt, free of chalk or flint inclusions, which allowed the cranium to be  
28 associated with a specific feature exposed on the east side of the drainage pit. The parent  
29 chalk geology, with thin rendzina soil cover, resulted in variable sized chalk flecks/lumps in  
30 all other feature fills at the site and Mary Oliver, the original excavator, is confident that the  
31 cranium derived from this feature (pers. comm.). The cleaned cranium is shown in **Figure 2**.  
32  
33  
34  
35  
36  
37  
38  
39  
40

41 Radiocarbon dating of the cranium gave an uncalibrated date of  $1173 \pm 24$  years BP  
42 (OxA-26646: AD 776-899 (87.3%) and AD 920-946 (8.1%) at 95.4%; see the Supplementary  
43 Material for full details), dating the individual to the middle to late Anglo-Saxon period.  
44  
45  
46

### 47 **Osteological assessment: age at death, biological sex and evidence of trauma**

48  
49 In summary, the osteological analysis (see supplementary text for full details) provided the  
50 following results. The cranium was generally well preserved, with the exception of the  
51 ectocranial surface of the occipital bone and both surfaces of the left and right parietals in  
52 close proximity to the parieto-occipital suture. Here there was widespread surface  
53 degradation, suggesting that this part of the cranium had been affected by different  
54 taphonomic conditions, possibly water flowing above a silt layer.  
55  
56  
57  
58  
59  
60

1  
2  
3 The cranium was clearly that of a young person (**Figure 3**). The only *in-situ* erupted  
4 tooth was a left first maxillary molar, which was lightly worn. The third molars were visible  
5 in the maxilla, just erupting from their crypts, and all other sockets were present but with the  
6 relevant teeth lost post-mortem. The baso-sphenoid suture was just starting to fuse, but the  
7 temporo-occipital and parieto-occipital sutures were totally unfused. These features in  
8 combination indicate a developmental age of around 15-18 years.  
9

10  
11  
12  
13  
14 The cranium had rounded features, with prominent frontal bossing, a gracile  
15 zygomatic arch, and a sharply-defined supra-orbital margin. These characteristics are typical  
16 of females, but young males may also exhibit such features prior to full expression of  
17 sexually dimorphic traits. Given the young age of the individual, and the absence of the  
18 pelvis, it was not possible to confidently determine the sex of the individual on the basis of  
19 morphological traits. Instead, the cranium was attributed as female based on ancient DNA  
20 analysis of the X and Y chromosomes (see Supplementary Material). Stable isotope analysis  
21 suggested that the woman was probably non-local, although it was not possible to identify a  
22 likely region of origin (see Supplementary Material).  
23  
24  
25  
26  
27  
28  
29

30 There was clear evidence of peri-mortem trauma (**Figure 2**) in the facial region. First,  
31 there was a linear cut on the medial left frontal bone with a v-shaped profile, oriented  
32 obliquely to the right when facing the cranium. Second, the removal of sediment revealed  
33 exposed trabecular bone at the base of the nasal aperture, cutting through the front of the  
34 maxillary central incisor sockets. The anterior nasal spine was also missing. The trabecular  
35 zone was surrounded by a margin of sharply defined cortical bone, especially at the base of  
36 the nasal aperture. The lower left and right lateral margins of the nasal aperture were also  
37 truncated. Overall, there appeared to be one or more straight cuts through the nasal margin  
38 from midway up the nasal aperture through the anterior nasal spine to the prosthion,  
39 consistent with slicing cuts from a knife (see Supplementary Material). Close examination of  
40 the lateral aspect revealed a sharp v-shaped nick on the left side of the nasal aperture with the  
41 cut through the lips at a slightly different angle to that through the nasal margins. This  
42 suggests that at least two cuts were made to inflict the injuries (**Figure 4**), indicating intent  
43 rather than a fortuitous blow, and restraint while the injuries were inflicted.  
44  
45  
46  
47  
48  
49  
50  
51  
52  
53  
54

55 There can be little doubt that the victim died around the time her nose was cut off.  
56 The edges of the wound are sharp with no signs of remodelling to indicate survival for even a  
57 few days. The injury to her nose could have been sufficient to cause her death, as it is likely  
58 that the wound would have damaged the network of arteries in the back of her nose. The nose  
59  
60

1  
2  
3 is supplied by two plexuses of arteries. The anterior one, known as Kiesselbach's plexus, is  
4 responsible for the great majority of nose-bleeds (Pope & Hobbs 2005), with bleeding easily  
5 controlled by applied pressure. The posterior, or Woodruff's plexus, tends to cause bleeding  
6 down the throat and can only be controlled by packing the rear of nasal structures above the  
7 soft palate, a procedure unlikely to have been known to Anglo-Saxon practitioners. The nasal  
8 wound may well have caused profuse bleeding from the posterior plexus leading to death by  
9 choking. However, whether her death resulted directly from the mutilation or from other  
10 injuries is unknowable in the absence of the rest of her skeleton and, alternatively, the  
11 wounds may have been made sometime in the interval between the victim's death and final  
12 deposition, whilst the bone was still in fresh condition.

21 The cut across the forehead may be related to the formal removal of the nose, scalping  
22 or removal of the person's hair. In examples elsewhere, archaeological evidence for scalping  
23 has been observed in the form of multiple small cuts circling the cranium (Axtell &  
24 Sturtevant 1980), but the skill of the person performing the operation is likely to affect the  
25 presence or otherwise of skeletal traces, as is the nature of the blade used. A long narrow iron  
26 blade, for example, is likely to leave a different trace to a shorter, broader flint blade  
27 (Greenfield 2002). Scalping may also be partial rather than complete.

33 In summary, the cranium belonged to a young, possibly non-local, female of around  
34 18 years of age. She had a sharp force wound obliquely across her forehead, possibly caused  
35 by a knife, and two mutilating cuts on her face, one through the upper and lower parts of the  
36 bony nasal aperture, the other through the bone in front of the upper central incisors. The  
37 lateral and posterior aspects of the cranium had been damaged by post-depositional changes.

### 42 **Landscape context**

44 The Oakridge burial lay *c.* 80m south of the boundary between a detached part of the parish  
45 of Basing in the Hundred (an Anglo-Saxon supra-local territory) of Basingstoke and the  
46 tithing of Chineham, itself a detached part of the parish of Monk Sherborne, which was in the  
47 neighbouring Hundred of Chuteley by 1831 (Page 1911: 113) (**Figure 5**). In the Domesday  
48 Survey of 1086 (DB Hampshire 23: 10; Williams & Martin 2002: 107), Chineham was an  
49 estate in its own right and originally part of the Hundred of Basingstoke, lying as it does in  
50 the centre of that district, which inspires confidence in the antiquity of the boundaries within  
51 it.  
52  
53  
54  
55  
56  
57  
58  
59  
60

1  
2  
3  
4  
5  
6  
7  
8  
9  
10  
11  
12  
13  
14  
15  
16  
17  
18  
19  
20  
21  
22  
23  
24  
25  
26  
27  
28  
29  
30  
31  
32  
33  
34  
35  
36  
37  
38  
39  
40  
41  
42  
43  
44  
45  
46  
47  
48  
49  
50  
51  
52  
53  
54  
55  
56  
57  
58  
59  
60

The Domesday Survey records 56 hides (the basic unit of land assessment in the Anglo-Saxon period) of land in Basingstoke Hundred in the time of Edward the Confessor (AD 1042-1066). Although the extent of the Hundred is much less than the nominal 100 hides for such a territory, after the Norman conquest Basingstoke continued to act as the centre for an associated grouping of six Hundreds (Cam 1944: 99; Yorke 1995: 40), perhaps reflecting the extent of an earlier ‘tribal’ territory.

That Basing and Basingstoke were significant places by the time the Oakridge mutilation occurred is borne out by the element common to both place-names. Basing is a name of so-called –ingas type, meaning ‘people of Basa’ (Ekwall 1960: 30). It is possible, using such evidence, to identify ‘tribal’ groupings and territories dating to at least the seventh and eighth century AD, if not earlier, particularly in this part of central southern England (Eagles 2018: 167-9). Such groups are likely to have been headed by families who, by a process of competition and allegiance, formed the basis for the kingdom of Wessex. The important sixth- and seventh-century AD Anglo-Saxon elite centre at Cowdery’s Down (Millett & James 1983) lay only two kilometres to the south-east of Oakridge and also within Basingstoke Hundred. Basing itself was a royal manor by at least the tenth century, as it featured in the will of King Eadred (AD 946-955), being bequeathed to his mother Queen Eadgifu (Tollerton 2011: 92). It is only by AD 1086 that Basingstoke appears to have succeeded Basing as the key settlement in the district (Hinton 1986: 162).

If the Oakridge Iron Age site was visible as an earthwork in the Anglo-Saxon period, then one can easily see how it might have been used a point of reference for the setting out of a local boundary, a feature that has been commonly observed elsewhere. The placing of the burial, if indeed it relates to the boundary, suggests that the latter is of at least ninth or tenth century AD date, possibly earlier. This aspect broadly aligns with a series of boundary burials elsewhere (Reynolds 2009b) that suggest defined local territories from the seventh and eighth century AD onwards, and an alternative view to that which sees local land units as mainly tenth and eleventh century formations (Hooke 1998: 68). We can be sure, on the basis of this evidence combined, that the Oakridge burial lay very close to an ancient boundary.

### **An Anglo-Saxon outcast?**

The Oakridge burial is best explained by considering the nature of the injuries sustained by the victim in combination with the topographical setting of the find as considered above. Although the radiocarbon date encompasses a documented battle at Basing between Vikings

1  
2  
3 and Anglo-Saxons in AD 871, there is nothing to suggest that this isolated burial is related to  
4 that event.  
5

6  
7 Isolated human burials form a recognised category of disposal of the dead in Anglo-  
8 Saxon England and are a particular feature of the Christian Period (from the seventh century  
9 AD onwards). While pre-Christian (fifth to seventh century AD) communities in England  
10 appear to have buried individuals marked out by 'negative' burial rites at the edges of their  
11 community cemeteries (Reynolds 2009a), it later became common practice to bury certain  
12 individuals in isolated locations away from 'normal' community cemeteries, partly drawing  
13 upon pre-existing notions of liminal places as suitable repositories for social outcasts. This  
14 recognised the binary notions of 'good' and 'evil' found in the Christian canon and  
15 subsequently realised in a landscape setting. Large-scale execution cemeteries also emerge  
16 during the later seventh and eighth century AD (Reynolds 2009b) and continue into the  
17 twelfth century AD and perhaps later. In view of these sites, it can be suggested that isolated  
18 burials are the result of local community actions rather than supra-local ones.  
19  
20

21 Both written descriptions of boundary markers (charters) and archaeological  
22 discoveries attest the practice of placing certain individuals on the boundaries of local land  
23 units. Textual sources reveal a tenth century AD horizon for individual burials, while  
24 radiocarbon dating of excavated isolates has shown a late sixth or seventh century AD origin  
25 for the practice (Reynolds 2009a: 209-18); however, written descriptions of boundaries only  
26 proliferate from the tenth century AD onwards.  
27  
28

29 It is noteworthy that isolated burials are a long-lived phenomenon, with explicitly  
30 documented examples known as late as the early modern period, particularly with regard to  
31 suicides and other social outcasts (Reynolds 2009a: 217). Instances of the practice are  
32 widespread, but a couple of local examples will suffice to illustrate the point. Just over ten  
33 kilometres south-east of Oakridge, an Anglo-Saxon charter of AD 1046 for an estate at  
34 Hoddington (Sawyer 1968: Cat. No. 1013) records a 'heathen burial' as one of its boundary  
35 markers; a terminology that an earlier Hampshire charter of AD 973-974, for an estate at  
36 Crondall twenty kilometres east of Oakridge, explicitly relates to the burial of a person  
37 marking the boundary noting "*where Ælfstan lieth in a heathen [i.e. outcast] burial*" (Sawyer  
38 1968: Cat. No. 820). The Oakridge burial is particularly significant in that it uniquely exhibits  
39 formal trauma inflicted upon an individual in combination with a liminal setting. Given that  
40 only the cranium was recovered, it may be that the head had been removed from the body as  
41  
42  
43  
44  
45  
46  
47  
48  
49  
50  
51  
52  
53  
54  
55  
56  
57  
58  
59  
60

part of the punishment, perhaps for the purposes of display, as is evidenced elsewhere in Anglo-Saxon England (Reynolds 2009a: 273-4).

### **Mutilation in the Anglo-Saxon legal context**

Textual sources provide insights into the range of mutilations encountered in a judicial/punitive setting and, in some instances, their motivations. The removal of hands and feet on account of theft is first noted in the seventh century AD law code of King Ine of Wessex (AD 688-725) (I 18 and 37). Amputation of the hand for theft, this time from the church, appears in King Alfred's (AD 871-899) law code (Alf 6), while the punishment for a slave who rapes another slave was castration (Alf 25.1). The second law code of Athelstan (AD 924-939) prescribed cutting off a moneyer's hand should he mint base or light coins (II Ath 14.1). The sources become more relevant to the Oakridge find, however, with King Edmund's third law code, where scourging, removal of the scalp, and mutilation of the little finger are listed as the penalty for thieving slaves (III Edm 4). King Edgar's (AD 959-975) third law code lists removal of the tongue for making false accusations (III Edg 4) but, in relating the miracles of Winchester's St. Swithun, the tenth and eleventh century AD writer Lantfred recalls an otherwise unattested law of Edgar for thieves, which required that the transgressor be "*tortured at length by having his eyes put out, his hands cut off, his ears torn off, his nostrils carved open and his feet removed; and finally, with the skin and hair of his head shaved off, he would be abandoned in the open fields*" (Wormald 1999: 25).

The so-called Laws of Edward and Guthrum (of probable late tenth century AD date) refer to unspecified mutilating and maiming of a criminal (E&G 10). King Aethelred's (AD 978-1016) first law code records branding for slaves found guilty at judicial ordeal (I Ath 2), and his fourth code provides a further instance of amputation of the hand for striking false coins (IV Ath 5.3), as does King Cnut's (AD 1016-1035) second law code (II C 8.1), which also records cutting out of the tongue for false accusation (II C 16) and removal of the hands or feet for theft (II C 30.4). Of particular relevance is a further clause in Cnut's second code that prescribes the putting out of eyes, the removal of the nose, ears, upper lip and scalp for a 'greater crime' than theft (II C 30.5). Clause 32.1 goes on to note branding for a slave guilty at ordeal, clause 36 requires removal of the hand for swearing a false oath, while clause 53 lists the removal of the nose and ears in the case of a woman accused of adultery.

1  
2  
3 With specific regard to the kind of injuries found on the Oakridge cranium, the legal  
4 corpus indicates that mutilation of the head was a punishment limited to quite particular  
5 circumstances in the case of slaves, adulteresses and particularly heinous offences.  
6  
7

### 8 9 **Concluding remarks**

10  
11 Violent punishment is a gruesome means by which societies exercise power over their  
12 citizens (Amussen 1995) and ritual mutilation, like execution, has been a feature of many  
13 societies for millennia (Skinner 2014). Mutilation was intended not to kill, but to humiliate or  
14 disable, and was meted out as punishment for crimes that did not warrant the death penalty. It  
15 can involve amputation of a limb (Mavroforou *et al.* 2014), or cutting off parts of the face,  
16 the ears or the nose (Sperati 2009); in the case of the latter, the victim would literally ‘lose  
17 face’ (Groebner 1995). In some cultures, mutilation of the nose was particularly reserved for  
18 females as this destroyed their beauty (Skinner 2015); when practiced on men (as an  
19 alternative to genital mutilation), it was seen as especially debasing (Van Eickels 2004),  
20 although many may have preferred it to the alternative. There are even hagiographic reports  
21 of self-mutilation, usually by nuns, as a means of preventing sexual assault by invaders  
22 (Sperati 2009).  
23  
24  
25  
26  
27  
28  
29  
30  
31

32 The nose itself is particularly significant, being the most prominent facial feature  
33 morphologically different to the nose of animals, with downward-facing nostrils hiding the  
34 internal structural complexity. When the nose is deliberately mutilated, or when social  
35 difficulties arise for people affected by diseases such as leishmaniasis, tumours, and other  
36 conditions, which may modify or destroy the normal appearance of the nose (Ashmead 1903;  
37 Friedman 1972), concepts of dehumanisation or divine punishment may have been invoked.  
38 The importance of the nose to human faces is reflected in the long established practice of  
39 physically removing them from statues of people no longer in favour or power ‘poena post-  
40 mortem’ (Kyle 1998; Varner 2001, 2004) or as a political punishment (Amussen 1995). The  
41 significance of normal facial appearance is also reflected in ancient codes of law. These  
42 introduced many forms of bodily mutilation as punishment for various crimes and included  
43 amputation of one or both hands and the slicing or cutting off of noses, ears and lips.  
44  
45  
46  
47  
48  
49  
50  
51  
52

53 The young woman whose remains were found at Oakridge was probably not born or  
54 raised in Hampshire, but we cannot say anything more about her locality of origin or how she  
55 came to the part of southern England in which she was found. Whilst the skeletal evidence  
56 taken in isolation allows multiple possible explanations for the trauma, the combination of all  
57  
58  
59  
60

1  
2  
3 the forms of evidence discussed above leads us to conclude that this is a case of deliberate  
4 facial mutilation, with possible scalping or, more likely, removal of hair. The specificity of  
5 the wounds strongly suggests that her mutilation was punitive, either at the hands of a local  
6 lynch mob marking her perceived offence by established custom, or by local administrators  
7 applying legal prescription. In either scenario, the woman, or at least her head, was then  
8 buried, outcast to the limit of the local territory. As noted above, the isolated nature of the  
9 burial is perhaps an indication of punishment at the most local level.

10  
11  
12  
13  
14  
15  
16 In conclusion, this paper presents evidence for facial mutilation. The person upon  
17 whom such awful injuries were inflicted may have suffered at the hands of a local  
18 community, but a penalty determined by a royal agent is also possible. Even though  
19 mutilations of the kind exhibited on the Oakridge cranium do not appear in the written record  
20 until the tenth century AD, the case reported here suggests that the practice emerged a  
21 century earlier. Irrespective of the circumstances behind the incident, this case appears to be  
22 the first archaeological example of this particularly brutal form of facial disfigurement from  
23 Anglo-Saxon England.  
24  
25  
26  
27  
28  
29  
30  
31  
32  
33  
34  
35  
36  
37  
38  
39  
40  
41  
42  
43  
44  
45  
46  
47  
48  
49  
50  
51  
52  
53  
54  
55  
56  
57  
58  
59  
60

## Acknowledgements

The authors would like to thank: David Allen, Curator of Archaeology, Hampshire Cultural Trust, for permitting invasive analysis of the specimen; Mary Oliver for discussing the original excavation; Tom Higham, Oxford University, for assistance with the radiocarbon sampling; Stuart Laidlaw, UCL, for photographic assistance; and the AEON EarthLAB, University of Cape Town, South Africa, for strontium analysis. KD was supported by The Leverhulme Trust via a Doctoral Scholarship Scheme entitled “*Genetic Journeys into History: The Next Generation*”, awarded to Martin Richards, University of Huddersfield. CJE was supported by The Leverhulme Trust (grant RPG-388) and the John Fell OUP Research Fund (112/247). The genetic research was funded by the NBAF Pilot Scheme, grant NBAF685, awarded to the Research Laboratory for Archaeology, University of Oxford. The authors would also like to thank the two anonymous reviewers for their helpful and constructive comments.

## References

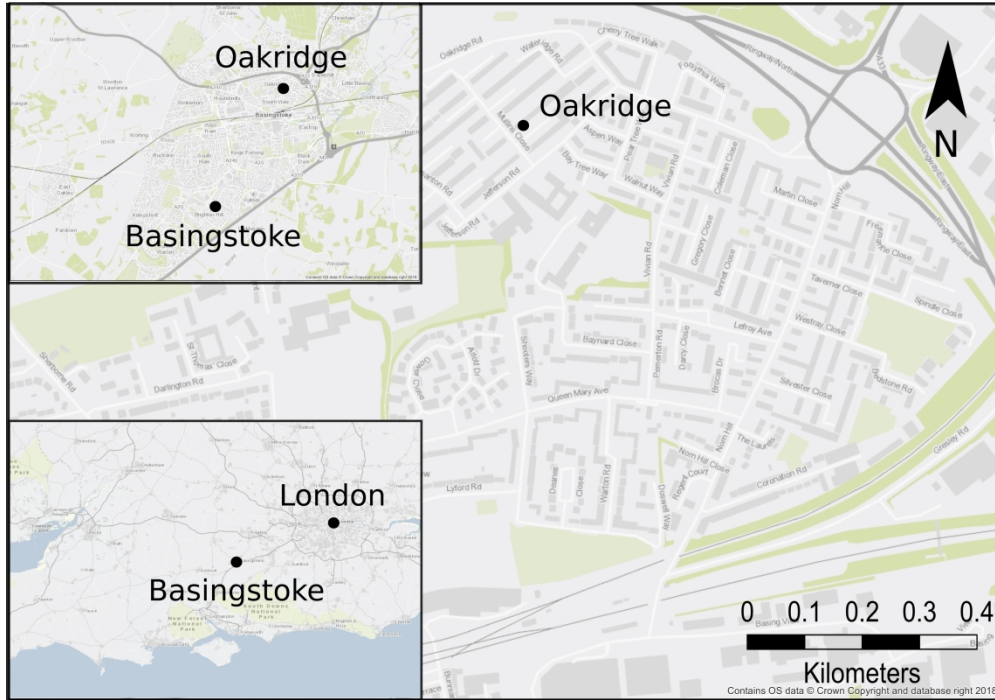- AMUSSEN, S.D. 1995. Punishment, discipline, and power: the social meaning of violence in early modern England. *Journal of British Studies* 34: 1-34.
- ARORA, D., C. MOHAN., P. BHARDWAJ., SADHNA. & A. SRIVASTAVA. 2017. History of Rhinoplasty. *International Journal of Advanced & Integrated Medical Sciences* 2(1): 40–43.
- ASHMEAD, A.S. 1903. Testimony of the Huacos (Mummy-Grave) Potteries of Old Peru. *Proceedings of the American Philosophical Society* 42(174): 378-396.
- ATKINSON, D. 1916. *The Romano-British Site on Lowbury Hill in Berkshire*. Reading: University College Reading.
- AXTELL, J. & W.C. STURTEVANT. 1980. The Unkindest Cut, or Who Invented Scalping *The William and Mary Quarterly* 37: 451–72.
- BARKER, P. 1981. *Wroxeter Roman City Excavations 1966-1980*. London: Department of the Environment.
- BL. 1794. Hindu rhinoplasty. *The Gentleman's Magazine* 64(2): 891–92.
- BRAIN, D.J. 1998. The early history of rhinoplasty. *Facial Plastic Surgery* 9: 81–88.
- BROTHWELL, D. 1971. Forensic aspects of the so-called Neolithic skeleton Q1 from Maiden Castle, Dorset. *World Archaeology* 3(2): 233-41.
- BROTHWELL, D. & V. MØLLER-CHRISTENSEN. 1963. Medico-Historical Aspects of a Very Early Case of Mutilation. *Danish Medical Bulletin* 10(1): 21-25.
- CAM, H. 1944. *Liberties and Communities in Medieval England*. Cambridge: Cambridge University Press.
- CARTY, N. 2015. 'The Halved Heads': Osteological Evidence for Decapitation in Medieval Ireland. *Papers from the Institute of Archaeology* 25(1): 1–20.
- EAGLES, B. 2018. *From Roman Civitas to Anglo-Saxon Shire: Topographical Studies on the Formation of Wessex*. Oxford: Oxbow Books.
- EKWALL, E. 1960. *The Oxford Dictionary of English Place-Names* (4th edition). Oxford: Clarendon Press.
- FERNANDES, T., M. LIBERATO., C. MARQUES. & E. CUNHA. 2017. Three cases of feet and hand amputation from Medieval Estremoz, Portugal *International Journal of Palaeopathology* 18: 63–68.

- 1  
2  
3 FRIEDMAN, L.W. 1972. Amputations and Prostheses in Primitive Cultures. *Bulletin of*  
4 *Prosthetics Research* 10: 105-138.  
5  
6 GELDOLF, M.R. 2015. 'And describe the shapes of the dead': Making Sense of the  
7 Archaeology of Armed Violence., in L. Tracy & K. DeVries (ed.) *Wounds and Wound*  
8 *Repair in Medieval Culture*: 57–80. Leiden: Brill.  
9  
10 GREENFIELD, H.J. 2002. Distinguishing Metal (Steel and Low-tin Bronze) from Stone (Flint  
11 and Obsidian) Tool Cut Marks on Bone: An Experimental Approach, in J.R. Mathieu  
12 (ed.) *Experimental Archaeology: Replicating Past Objects, Behaviors, and Processes*:  
13 35–54. Oxford: British Archaeological Reports.  
14  
15 GROEBNER, V. 1995. Losing face, saving face: noses and honour in the late medieval town.  
16 *History Workshop Journal* 40: 1-15.  
17  
18 HINTON, D. 1986. The place of Basing in mid-Saxon history. *Proceedings of the Hampshire*  
19 *Field Club and Archaeological Society* 42: 162-3.  
20  
21 HOOKE, D. 1998. *The Landscape of Anglo-Saxon England*. London and Washington:  
22 Leicester University Press.  
23  
24 KYLE, D.G. 1998. *Spectacles of Death in Ancient Rome*. London: Routledge.  
25  
26 LUPO, G. 1997. The history of aesthetic rhinoplasty: special emphasis on the saddle nose.  
27 *Aesthetic Plastic Surgery* 21: 309–27.  
28  
29 MAVROFOURO, A., K. MALIZOS., T. KARACHIALOS., K. CHATZITHEOFILOU. & A.D.  
30 GIANNOUKAS. 2014. Punitive limb amputation. *Clinical Orthopaedics and Related*  
31 *Research* 472: 3102-3106.  
32  
33 MAYS, S.A. 1996. Healed limb amputations in human osteoarchaeology and their causes: A  
34 case study from Ipswich, UK *International Journal of Osteoarchaeology* 6: 101–13.  
35  
36 MAYS, S. & J. STEELE. 1996. A mutilated human skull from Roman St Albans, Hertfordshire,  
37 England. *Antiquity* 70: 155-161.  
38  
39 MAZZOLO, R.F. & S. MARCUS. 1983. History of total nasal reconstruction with particular  
40 emphasis on the folded forehead flap technique. *Plastic and Reconstructive Surgery* 72:  
41 408–414.  
42  
43 MCCOMISH, J. 2000. The Medieval Jewish Cemetery at Jewbury, York *Jewish Culture and*  
44 *History* 3: 21–30.  
45  
46 MILLETT, M. & S. JAMES. 1983. Excavations at Cowdery's Down, Basingstoke, Hampshire,  
47 1978-81. *Archaeological Journal* 140: 151-279.  
48  
49 NIBLETT, R. 1999. *The Excavation of a Ceremonial Site at Folly Lane, Verulamium*.  
50 Britannia Monograph Series 14. London: Society for the Promotion of Roman Studies.  
51  
52  
53  
54  
55  
56  
57  
58  
59  
60

- 1  
2  
3 NIKOLIĆ, V., S. SAVIĆ., V. ANTUNOVIĆ., S. MARINKOVIĆ., C. ANDRIEUX. & I. TOMIĆ. 2017.  
4  
5 Decapitation in reality and fine art: A review *Forensic Science International* 280: 103–  
6  
7 12.
- 8 OLIVER, M. 1993. Excavation of an Iron Age and Romano-British settlement site at  
9  
10 Oakridge, Basingstoke, Hampshire 1965-6. *Proceedings of the Hampshire Field Club*  
11  
12 *and Archaeological Society* 48: 55-94.
- 13 PAGE, W. 1911. *A History of the County of Hampshire Volume 4*. London: Oxford University  
14  
15 Press.
- 16  
17 POPE, L.E.R. & C.G.L. HOBBS. 2005. Epistaxis: an update on current management.  
18  
19 *Postgraduate Medical Journal* 81: 309-314.
- 20 REYNOLDS, A. 2009a. *Anglo-Saxon Deviant Burial Customs*. Oxford: Oxford University  
21  
22 Press.
- 23  
24 REYNOLDS, A. 2009b. *The emergence of Anglo-Saxon judicial practice: the message of the*  
25  
26 *gallows*. Aberdeen: The Centre for Anglo-Saxon Studies University of Aberdeen.
- 27 SAWYER, P. H. 1968. *Anglo-Saxon Charters: An Annotated List and Bibliography* (Royal  
28  
29 Historical Society Guides and Handbooks 8). London: Royal Historical Society.
- 30 SKINNER, P. 2014. The gendered nose and its lack: “Medieval” nose-cutting and its modern  
31  
32 manifestations. *Journal of Women's History* 26(1): 45-67.
- 33  
34 — 2015. Marking the face, cuing the soul? Reading the disfigurement of women in the later  
35  
36 Middle Ages, in N.K. Yoshikawa (ed.) *Medicine, Religion and Gender in Medieval*  
37  
38 *Culture*: 181-201. Suffolk: Boydell and Brewer.
- 39 SPERATI, G. 2009. Amputation of the nose through history. *Acta Otorhinolaryngologica*  
40  
41 *Italica* 29: 44-50.
- 42  
43 STUCKERT, C.A. & M.E. KRICUN. 2011. Case Study: A case of bilateral forefoot amputation  
44  
45 from the Romano-British cemetery of Lankhills, Winchester, UK *International Journal*  
46  
47 *of Paleopathology* 1: 111–16.
- 48 TEWARI, M. & H.S. SHUKLA. 2005. Shushruta: ‘The Father Of Indian Surgery’. *Indian*  
49  
50 *Journal of Surgery* 67: 229–30.
- 51 TOLLERTON, L. 2011. *Wills and Will-Making in Anglo-Saxon England*. Woodbridge: Boydell  
52  
53 and Brewer.
- 54  
55 VAN DE GRAAF, R.C. 2009. Some remarks on the revival of rhinoplasty in Europe in the  
56  
57 early nineteenth century. *Acta Otorhinolaryngologica Italica* 29: 226-227.
- 58 VAN EICKELS, K. 2004. Gendered violence: castration and blinding as punishment for treason  
59  
60 in Normandy and Anglo-Norman England. *Gender & History* 16: 588-602.

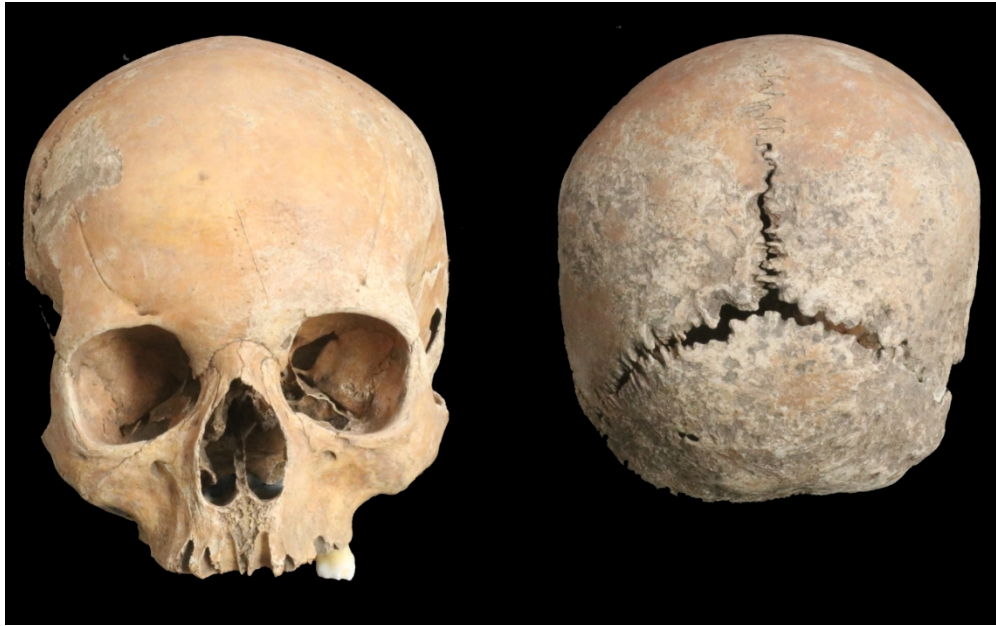- 1  
2  
3 VARNER, E.R. 2001. Punishment after death: Mutilation of images and corpse abuse in  
4 ancient Rome. *Mortality* 6(1): 45-64.  
5  
6 — 2004. *Mutilation and Transformation: Damnatio Memoriae and Roman Imperial*  
7 *Portraiture*. Leiden: Brill.  
8  
9  
10 WADE-MARTINS, P. 1980. *Excavations at North Elmham Park*. Gressenhall: Norfolk  
11 Archaeological Unit.  
12  
13 WENHAM, S.J. 1989. Anatomical interpretations of Anglo-Saxon weapon injuries, in S.C.  
14 Hawkes (ed.), *Weapons and Warfare in Anglo-Saxon England* (Oxford University  
15 Committee for Archaeology Monographs 21): 123-39. Oxford: Oxford University  
16 Press.  
17  
18  
19 WILLIAMS, A. & G.B. MARTIN. 2002. *Domesday Book: A Complete Translation*. London:  
20 Penguin.  
21  
22  
23 WORMALD, P. 1999. *The Making of English Law: King Alfred to the Twelfth Century. Volume*  
24 *1 Legislation and its Limits*. Oxford: Basil Blackwell.  
25  
26  
27 YORKE, B. 1995. *Wessex in the Early Middle Ages*. London: Leicester University Press.  
28  
29  
30  
31  
32  
33  
34  
35  
36  
37  
38  
39  
40  
41  
42  
43  
44  
45  
46  
47  
48  
49  
50  
51  
52  
53  
54  
55  
56  
57  
58  
59  
60

1  
2  
3  
4  
5  
6  
7  
8  
9  
10  
11  
12  
13  
14  
15  
16  
17  
18  
19  
20  
21  
22  
23  
24  
25  
26  
27  
28  
29  
30  
31  
32  
33  
34  
35  
36  
37  
38  
39  
40  
41  
42  
43  
44  
45  
46  
47  
48  
49  
50  
51  
52  
53  
54  
55  
56  
57  
58  
59  
60



Location of Oakridge at Basingstoke, Hampshire, England.

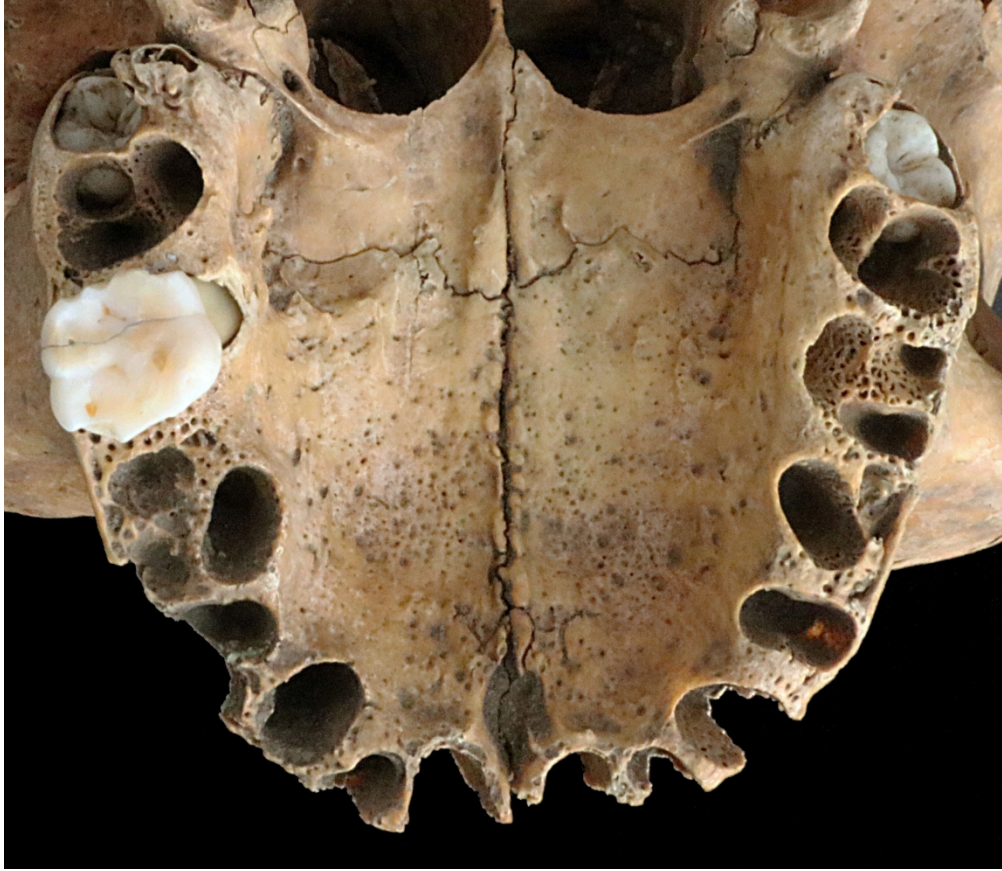
289x202mm (300 x 300 DPI)



Views of the cleaned cranium showing the well preserved anterior aspect and the degraded posterior aspect.


172x107mm (300 x 300 DPI)

1  
2  
3  
4  
5  
6  
7  
8  
9  
10  
11  
12  
13  
14  
15  
16  
17  
18  
19  
20  
21  
22  
23  
24  
25  
26  
27  
28  
29  
30  
31  
32  
33  
34  
35  
36  
37  
38  
39  
40  
41  
42  
43  
44  
45  
46  
47  
48  
49  
50  
51  
52  
53  
54  
55  
56  
57  
58  
59  
60



Occlusal view of the maxilla, showing the erupted left first molar. The third molars are visible in their crypts.

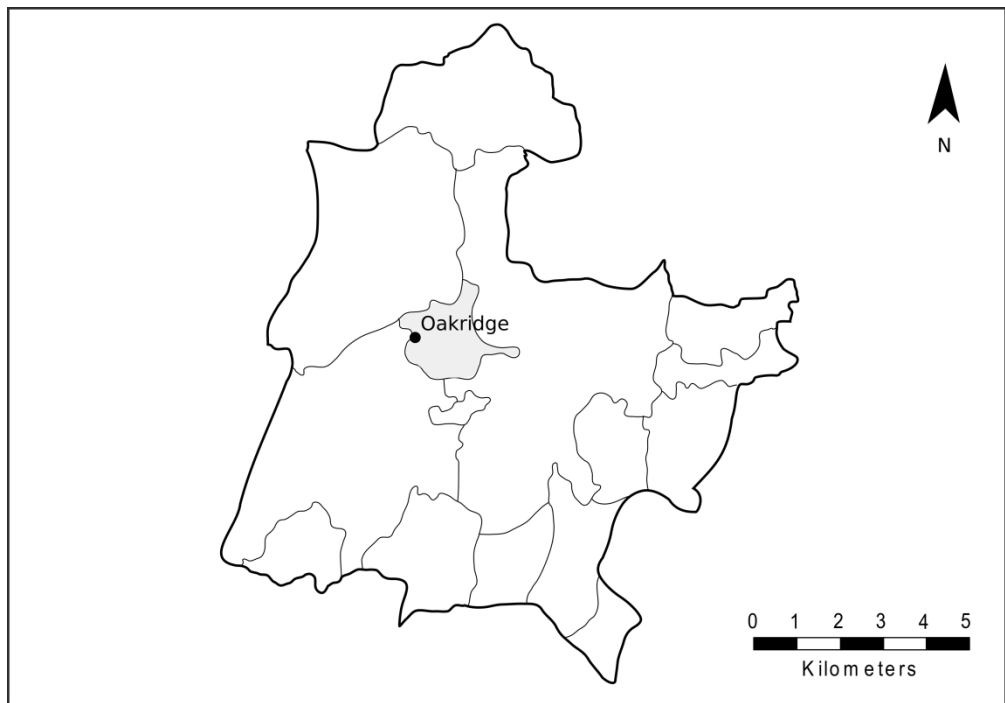
275x239mm (300 x 300 DPI)



Close-up views of the facial trauma. From left to right, top to bottom; the oblique frontal cut; the obliquely angled cuts through at the lower margin of the nasal aperture from the front and from above, and the anterior of the maxilla; the linear cut through the lateral margin of the nasal aperture; and the sharp nick on the right side. The cuts and nicks are marked by arrows.

290x205mm (300 x 300 DPI)

1  
2  
3  
4  
5  
6  
7  
8  
9  
10  
11  
12  
13  
14  
15  
16  
17  
18  
19  
20  
21  
22  
23  
24  
25  
26  
27  
28  
29  
30  
31  
32  
33  
34  
35  
36  
37  
38  
39  
40  
41  
42  
43  
44  
45  
46  
47  
48  
49  
50  
51  
52  
53  
54  
55  
56  
57  
58  
59  
60



The territorial context of the Oakridge burial. The site is located on the western boundary of the Anglo-Saxon estate of Chineham (highlighted in light grey) in Basingstoke Hundred.

289x202mm (300 x 300 DPI)

1  
2  
3 **SUPPLEMENTARY MATERIAL**  
4  
5  
6  
7

8  
9 **Summary justice or the King's will? The first case of formal facial mutilation from**  
10  
11 **Anglo-Saxon England**  
12  
13  
14  
15

16 **Authors: Garrard Cole, Peter W. Ditchfield, Katharina Dulias,**  
17  
18  
19 **Ceiridwen J. Edwards, Andrew Reynolds and Tony Waldron**  
20  
21  
22  
23  
24

25 **Contents**  
26

27  
28 1. OSTEOLOGICAL ANALYSIS 2–8  
29  
30 2. RADIOCARBON DATING 9  
31  
32  
33 3. STABLE ISOTOPIC ANALYSIS 10–14  
34  
35  
36 4. ANCIENT DNA ANALYSIS 15–19  
37  
38  
39 5. LITERATURE CITED 20–26  
40  
41  
42  
43  
44  
45  
46  
47  
48  
49  
50  
51  
52  
53  
54  
55  
56  
57  
58  
59  
60

## 1. OSTEOLOGICAL ANALYSIS

The osteological analysis was carried out using standard methods (outlined in WEA 1980 and Buikstra & Ubelaker 1994). The basis behind the methods was to use as many age and sex variable factors as possible. The limited material in this case restricted analysis to cranium morphology, suture fusion, dental development and tooth wear.

### **Taphonomic considerations**

The cranium in question was found in an unclean state in the Hampshire Cultural Trust stores. This turned out to be fortunate for two reasons; firstly, it allowed excavation damage to be excluded as a cause for crucial changes to the facial area (as detailed below); secondly, it allowed the otherwise poorly recorded material to be associated with a specific distinctive archaeological feature, which served to explain the taphonomic changes observed on part of the exterior surface.

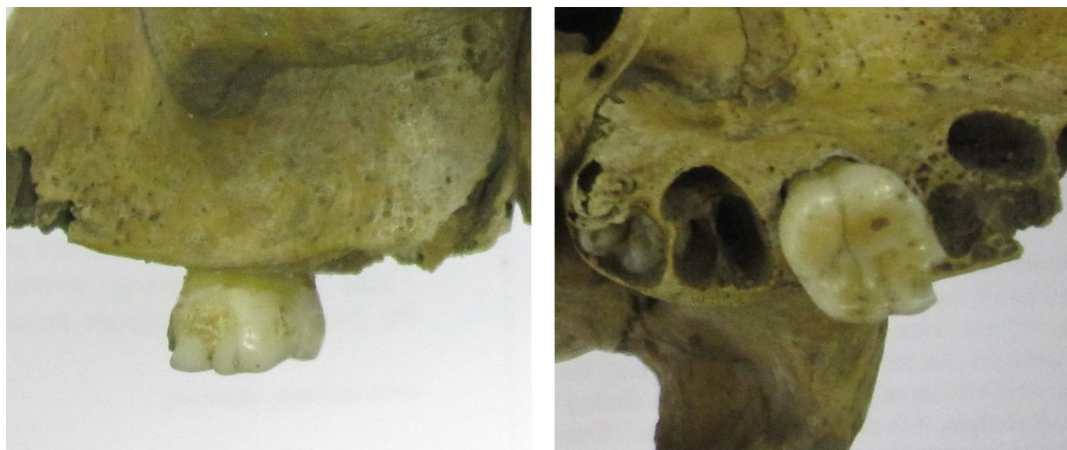
The cranium as found was covered in a very fine dark silt sediment with no sign of any chalk inclusions as were reported in almost all archaeological features observed during the excavations. The silt totally filled all tooth sockets, with the exception of a solitary *in-situ* left first maxillary molar. The nasal aperture was also completely filled with a thin layer of sediment, masking the face, especially between the anterior nasal spine and prosthion (or rather where the prosthion would have been).

The exterior surface showed variable irregular surface degradation, more pronounced on the occipital bone. The endocranial surface was generally in very good condition. The unmodified bone surface was coloured a medium orange brown, whilst the degraded surface was lighter in colour. The surface taphonomy changes are consistent with partial exposure in a wet environment. The right temporal bone was not recovered. The sharp well-defined appearance of the zygomatic part of the right zygomatico-temporal suture suggests the loss of the temporal occurred shortly before recovery from the spoil heap.

### **Age at death estimation**

The human skeleton and dentition undergoes changes associated with age. Age-dependent factors include dental development and eruption, long bone diaphysis length, long bone epiphyseal fusion, cranial suture fusion and changes to the morphology of the pelvis,

1  
2  
3 specifically the auricular surface and the pubic symphysis. For some populations known to  
4 have had an appropriate diet, wear of the occlusal surface of the teeth may also be used. One  
5 complicating factor is the sex-dependent nature of some of these changes. The error ranges  
6  
7  
8  
9



24 on the age estimates increases significantly with age.

25  
26 **Figure S1. Upper left M1 tooth in-situ in maxilla, showing occlusal and buccal views.**

27  
28  
29  
30 The primary age-at-death indicators were the state of development of the few teeth present and  
31 the status of some cranial sutures and synchondroses. The cranium was clearly that of a  
32 young person, as the maxillary third molars were just erupting from their crypts (**Figure S1**).  
33 The only *in-situ* erupted tooth was a left first maxillary molar. The tooth was lightly worn,  
34 with loss of cusp enamel, but the crown was otherwise complete, apart from a small chip at  
35 the mesio-buccal corner. There appeared to be a taphonomic linguo-buccal fissure running  
36 through the crown and slight amounts of dental calculus. This sole molar was extracted for  
37 dietary and locational stable isotopic analysis, revealing fully developed roots. An X-ray  
38 showed that the sockets for the second molars were as deep as those of the first molars,  
39 suggesting that the second molar was also fully developed. The third molars were visible in  
40 the maxilla, but had not erupted. The third molars had fully developed crowns with roots  
41 some way between quarter and half development. All other sockets were present but with the  
42 relevant teeth lost post-mortem. Dental development data (Moorrees *et al.* 1963; Al Qahtani  
43 2008) suggests a developmental age at death of  $15 \pm 3$  years. The utility of dental formation  
44 for estimating developmental age (Moorrees *et al.* 1963) has been validated by Saunders *et*  
45 *al.* (1993). The method strictly only applies to mandibular dentition, but it is applicable to the  
46 maxillary permanent molars as the developmental stages closely match (Al Qahtani 2008,  
47 2014).  
48  
49  
50  
51  
52  
53  
54  
55  
56  
57  
58  
59  
60

Miles (1962) developed techniques for determining age at death based on tooth wear. He used a high tooth wear population from the Anglo-Saxon period as his reference, so the method is applicable here. The pattern of occlusal wear on the first molar suggests a range of  $18 \pm 3$  years.

Cranial suture fusion has a long history for age at death estimation (Broca 1868), but in spite of recent attempts to improve its utility (Alhazmi *et al.* 2017), still tends to be used as an indicator of last resort. The state of cranial suture fusion is listed in **Table S1**.

**Table S1: Fusion status of the cranial sutures.**

Suture	Fusion state
Metopic	Fused, not visible
Nasal	Fusing
Sagittal	Fusing
Coronal	Fusing
Occipito-mastoid	Unfused
Lambdoid	Unfused
Parieto-temporal	Unfused
Zygomatoco-temporal	Unfused

The basal occipito-sphenoidal synchondrosis was unfused, though the surface morphology suggested that fusion was in progress. Data from Alhazmi *et al.* (2017) suggests the individual had a developmental age at death in the range 10-20 years.

### **Biological sex determination**

The human skeleton exhibits some degree of sexual dimorphism. This can be used, with appropriate caveats, to assess the biological sex of the individual. Skeletal dimorphism starts to be expressed during puberty and becomes clearest in early adulthood. However, older females may develop changes to the skull normally associated with males, and so age has to be taken into account when assessing sex. The primary data for assessment comes from skull morphology, pelvis morphology and long bone metrics. In this case, cranium morphology was the sole source of data.

The cranium had rounded features, with prominent frontal bossing, a gracile zygomatic arch, and a sharply-defined supra-orbital margin. The maxilla was very broad in relation to its antero-posterior length. The mastoid process was short but rather broad in the antero-posterior direction. Superficial surface degradation had removed the fine detail of the exterior

1  
2  
3 surface of the occipital bone, but it appeared to lack prominent muscle attachments. The  
4 temporal ridge was also smooth. These features suggest the individual was possibly female.

### 7 **Trauma**

8  
9  
10 Cleaning of the cranium revealed clear evidence of peri-mortem trauma (**Figure 2**). First,  
11 there was a linear cut on the medial left frontal bone with a v-shaped profile, oriented  
12 obliquely to the right when facing the cranium. Second, the removal of sediment revealed  
13 exposed trabecular bone at the base of the nasal aperture, cutting through the front of the  
14 maxillary central incisor sockets. The anterior nasal spine was also missing. The trabecular  
15 zone was surrounded by a margin of sharply defined cortical bone, especially at the base of  
16 the nasal aperture. The lower left and right lateral margins of the nasal aperture were also  
17 truncated. These features mark the trauma as peri-mortem, though it is not clear whether the  
18 event happened before death or shortly afterwards whilst the bone was still fresh.

19  
20 Overall, there appeared to be one or more straight cuts through the nasal margin from  
21 midway up the nasal aperture through the anterior nasal spine to the prosthion. The cuts  
22 removed the anterior nasal spine and the area in proximity to prosthion. Close examination of  
23 the lateral aspect revealed a sharp v-shaped nick on the left side of the nasal aperture, with the  
24 cut through the lips at a slightly different angle to that through the nasal margins. The  
25 direction of inclination of the cuts is consistent with a right-handed opponent facing the  
26 victim.

### 37 **Ethnicity**

38  
39  
40 Cranial morphology may give some clue as to the ethnicity of regional origin of an  
41 individual, and there are general trends of shape thought to broadly distinguish major regional  
42 groups, such as European, Asian, African and Native American. However, there is  
43 considerable overlap between the skull shapes for these regions, and any such assessment  
44 serves only as a guide. The analysis is usually performed via a multidimensional discriminant  
45 analysis of metrical data for the skull (or cranium) in question. Fordisc (ver. 3.1; Jantz &  
46 Ousley 2005) is the best known and most widely used implementation of this approach. The  
47 measurements are made between pairs of well-defined anatomical landmarks, with each  
48 measurement identified by a distinct three-letter code. The resultant data set is tested against  
49 reference populations of skulls of known ancestry. The program produces a list of matching  
50 skulls, matched according to minimum multidimensional geometric distance.

The metric data for the Oakridge cranium is listed in **Table S2**. The data marked as 'estimate' could not be obtained directly as the relevant area on one side of the cranium was damaged. The data was estimated measuring from the centre line to the good side and doubling the result.

**Table S2: Metric data for the Oakridge cranium ordered by measurement reference code. The data is rounded to the nearest millimetre. Key: \* - estimates based on unilateral measurements from the centre line to the side where the landmark is present; \*\* - estimate based on projected location of prosthion.**

Code	Metric (mm)
ASB	105
AUB	118
BBH	127
BNL	96
DKB	21
EKB	91
FMB	91
FOB	27
FOL	35
FRC	103
FRS	27
GOL	169
JUB	107
MAB	61
NLB(**)	23
NLH	45

Code	Metric (mm)
NOL	166
NPH	61
OBB	38
OBH	32
OCC	92
PAC	102
PAS	23
STB	111
WCB	75
WMH	21
WNB	12
XCB	126
XFB	112
ZYB(*)	117
ZMB	86

**Table S3: Fordisc results showing primary and secondary matched groups with associated probabilities for various subsets of the measured data in Table S2.**

Measurement dataset	Reference Database	Primary match		Secondary match	
		Group	Probability	Group	Probability
all measurements included	modern forensic database	Hispanic female	0.659	African female	0.201
all measurements included	Howell's database	Zalavar (Hungary) female	0.52	20 <sup>th</sup> C white female	0.211
only ZYB measurement included	modern forensic database	Black female	0.502	Hispanic female	0.362
only ZYB measurement included	Howell's database	Zalavar (Hungary) female	0.373	Atayal (Taiwan) female	0.308
both NLB and ZYB measurements excluded	modern forensic database	Black female	0.457	Hispanic female	0.269
both NLB and ZYB measurements excluded	Howell's database	Zalavar (Hungary) female	0.448	Atayal (Taiwan) female	0.396

## Discussion

The nature of the taphonomic changes present on the posterior and right endocranial surface of the cranium, in combination with the presence of very fine silt in the orbital, nasal and alveolar regions, suggested that the cranium was recovered from a watery environment (Knüsel & Carr 1995).

Given the limited data and the relatively poor accuracy of the ageing methods available, it was only possible to provide a relatively broad estimate for the age of death of the individual. Taken in combination, the age determination features indicated that the individual was certainly not adult at the time of death, and possibly had a developmental age of around 15-18 years.

The cranial morphology was typically female, but young males may also exhibit such features prior to full expression of sexual dimorphic traits. Given the young age of the individual, and the absence of the pelvis, it was not possible to confidently determine the sex of the individual on the basis of morphological traits alone.

There was clear evidence for perimortem trauma to the frontal bone and the facial region. The fact that the cut marks only appeared after removal of residual sediment from the cranium allows excavation damage to be excluded as a cause. In addition to the oblique cut on the frontal bone, it appeared that at least two further cuts were made to inflict the injuries (**Figure 4**). The narrow nature of all these features suggested a narrow sharp bladed

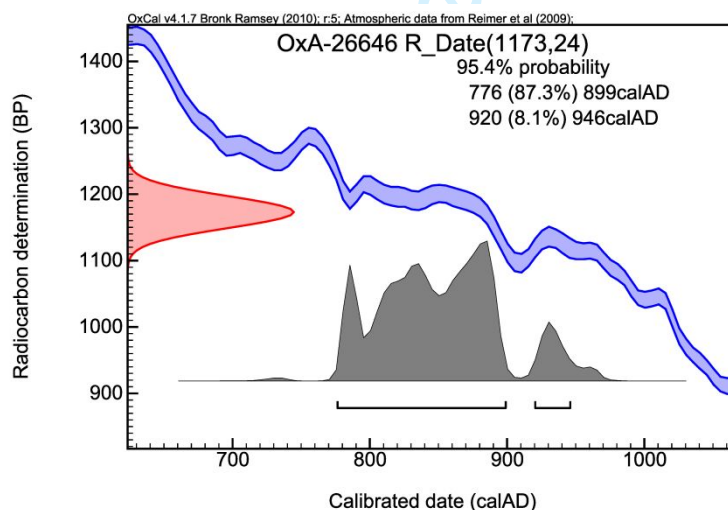
1  
2  
3 instrument, such as a knife or seax was used, rather than a sword or a broader bladed  
4 implement such as an axe (Lewis 2008). The cuts in the nasal area are consistent with a knife  
5 blade slicing through the nasal soft tissue and that of the upper lip sufficiently deeply to cut  
6 through the thin cortical bone. If the wounds were made before death, the presence of  
7 multiple wounds in the facial region suggests deliberate intent rather than fortuitous blows. In  
8 this case, it is likely that the individual was restrained in some manner. In the absence of  
9 other parts of the skeleton, it is not possible to say anything about trauma elsewhere on the  
10 body, and so we cannot determine the mode of death. The trauma may also have been  
11 inflicted, in part or in whole, after the individual had died, whilst the bone was still in fresh  
12 condition.

13  
14  
15  
16  
17  
18  
19  
20  
21 The norma frontalis view of the cranium exhibits some distinctive features – a large  
22 intra-orbital breadth, rectangular orbits and a nasal aperture very broad in relation to its  
23 height. The use of Fordisc to investigate possible ethnicity has known limitations (Ramsthaler  
24 *et al.* 2007; Elliot & Collard 2009), And the problems are more pronounced in archaeological  
25 specimens, arising from taphonomic modification of skull morphology, potential masking of  
26 reference landmarks, and post-burial shape deformation. However, the facial area of this  
27 individual was well preserved. Other areas exhibited variable surface bone loss, which will  
28 have inevitably affected measurements. The results using the forensic data show great  
29 variability of association, according to which estimated data values are used. The program  
30 also showed that most measured data values fell within one or two standard deviations below  
31 the dataset mean values. This is not surprising given the young age of the individual. The  
32 comparisons with Howell's dataset (Howells 1973, 1989) were more consistent, preferring an  
33 association with the Zalavar (Hungary) female throughout. However, with one exception, the  
34 probability associated with the primary preference was around 0.5 or less. These results do  
35 not permit any statement about potential ethnic origin to be made with any confidence. The  
36 genetic analysis discussed below offers a more definitive answer to this question.

## 2. RADIOCARBON DATING

A powdered sample was extracted from the inner table of the occipital bone in order to determine a radiocarbon date for the specimen. Sub-sampling was carried out by Tom Higham at the Oxford Radiocarbon Laboratory. The surface of approximately 1cm square of the inner table was cleaned using 5µm aluminium oxide abrasive powder in an environmental cabinet. A high speed drill was then used to extract around 100mg of bone powder. This was processed using the standard Oxford Laboratory protocol (Bronk Ramsey *et al.* 2002, 2004a, 2004b).

The sample was assigned dating code OxA-26646 and the uncalibrated date was determined to be 1173 BP with an error of  $\pm 24$  years. This date was calibrated using OxCal (ver. 4.1.7; Bronk Ramsey 2017) and the most recent calibration curve, IntCal 13 (Reimer *et al.* 2013). The calibrated date was determined to be between AD 776-899 (87.3%) and 920-946 (8.1%) at  $2\sigma$  (95.4%) (**Figure S2**). The mean date was AD 846 and the median date was AD 843. Stable isotopic evidence (see below) suggested that there was no significant marine component to the diet of this individual, and, therefore, the date did not require a marine correction.



**Figure S2. Calibrated radiocarbon dates for the Oakridge individual based on an uncalibrated date of  $1173 \pm 24$  years bp.**

Although the date of late eighth to ninth century AD (between cal. AD 776 and 946) encompasses the documented Battle of Basing, which occurred between Danes and local Saxons on the 22nd of January AD 871 (King & Cole 2016), there is nothing to suggest that

1  
2  
3  
4  
5  
6  
7  
8  
9  
10  
11  
12  
13  
14  
15  
16  
17  
18  
19  
20  
21  
22  
23  
24  
25  
26  
27  
28  
29  
30  
31  
32  
33  
34  
35  
36  
37  
38  
39  
40  
41  
42  
43  
44  
45  
46  
47  
48  
49  
50  
51  
52  
53  
54  
55  
56  
57  
58  
59  
60

this isolated burial is related to that event.

For Peer Review

### 3. STABLE ISOTOPIC ANALYSIS

The left maxillary first molar was selected for carbon (C), nitrogen (N), oxygen (O) and strontium (Sr) stable isotopic analyses at the Research Laboratory for Archaeology at the University of Oxford (England).

#### Dental enamel strontium measurement

The tooth crown was cleaned in an ultrasonic bath of deionised water for three minutes. The area selected for enamel sampling was then surface abraded with 5 $\mu$ m aluminium oxide powder using a compressed air abrasive system. 20mg of enamel powder was extracted from the buccal surface using a diamond impregnated dental burr. Sample dissolutions were performed following the method of Cohen *et al.* (1988). Samples were dissolved in PFA (polyfluoroalkoxy) beakers on a hot plate (*c.* 150°C, 24 hours) in a 7:3 mixture of 29M HF and 14M HNO<sub>3</sub>. Samples were repeatedly evaporated to dryness and the residue re-dissolved in 14M HNO<sub>3</sub>. Strontium was separated by the method described by Míková & Denková (2007), which is a development of the method described by Pin *et al.* (1994). This is a variation of the standard ion exchange method, in this case using Sr. Spec ion exchange resins obtained from Eichrom Environment (Bruz, France) (see Míková & Denková 2007 for details). All Sr isotopic analyses were performed on a Nu Instruments NuPlasma HR in the AEON EarthLAB, housed in the Department of Geological Sciences, University of Cape Town, Rondebosch, South Africa. Extracted Sr samples were analysed as 200ppb in 0.2% HNO<sub>3</sub> solution, using NIST SRM987 as a reference standard (mean value of 0.710302, *n* = 8, and 2 sigma = 0.000027, where the internationally agreed reference value equals 0.710255). All Sr isotope data were corrected for rubidium (Rb) interference using the measured signal for <sup>85</sup>Rb and the natural <sup>85</sup>Rb/<sup>87</sup>Rb ratio. Instrumental mass fractionation was corrected for using the exponential law and an <sup>86</sup>Sr/<sup>88</sup>Sr value of 0.1194.

#### Dental enamel oxygen and carbon measurements

Two milligrams of the untreated enamel from the tooth was used for oxygen stable isotopic analysis. This was pre-treated with 1M CH<sub>3</sub>COOH solution for three hours at room temperature to remove any secondary carbonates and then rinsed to neutrality with deionised water and freeze dried prior to isotopic analysis. The sample was analysed for  $\delta^{13}\text{C}$  and  $\delta^{18}\text{O}$  using a VG Isogas Prism II mass spectrometer with an on-line VG Isocarb common acid bath preparation system, where it was reacted with purified phosphoric acid (H<sub>3</sub>PO<sub>4</sub>) at 90°C. The

1  
2  
3 evolved CO<sub>2</sub> was pre-concentrated using a cold finger apparatus prior to admission to the  
4 dual inlet system on the mass spectrometer. Calibration to V-PDB standard was via NBS-19  
5 using the Oxford *in-house* (NOCZ) Carrara marble standard. The replicate values for the *in-*  
6 *house* standards run with the sample in this study gave a mean value of 2.96‰ for δ<sup>13</sup>C with  
7 a standard deviation of 0.022, and a mean value of -1.91‰ for δ<sup>18</sup>O with a standard deviation  
8 of 0.026 (n = 8). Expected values for the *in-house* standard were 2.307‰ for δ<sup>13</sup>C and -  
9 1.906‰ for δ<sup>18</sup>O relative to V-PDB.

10  
11  
12  
13  
14  
15  
16 Mammalian tooth enamel contains up to 2% carbonate anions substituted for phosphate  
17 anions within the hydroxyapatite matrix of the enamel. The carbon and oxygen isotopic  
18 values of tooth enamel carbonate (referred to as δ<sup>13</sup>Cc and δ<sup>18</sup>Oc, respectively) were  
19 measured to try to determine the location at which the Oakridge individual was living at the  
20 time the enamel was being formed. The value of δ<sup>18</sup>Oc will be related to the oxygen isotopic  
21 value of the local drinking water (referred to as δ<sup>18</sup>Ow) (Pollard & Heron 2008: 371) and this,  
22 in turn, is thought to reflect the oxygen isotopic value of local rainfall (although significant  
23 use of ground water as a drinking water source will modify this signal somewhat). The tooth  
24 enamel carbonate carbon isotopic value (δ<sup>13</sup>Cc) will be related to the blood bicarbonate  
25 reservoir and, as such, reflects total diet.

26  
27  
28  
29  
30  
31  
32  
33  
34 The δ<sup>13</sup>Cc and δ<sup>18</sup>Oc values were measured relative to the international standard V-  
35 PDB scale. However, to arrive at a likely oxygen isotopic composition for drinking water,  
36 several transformations had to be made. Firstly, the δ<sup>18</sup>Oc values were converted from the V-  
37 PDB scale to the SMOW-SLAP (Standard Mean Ocean Water- Standard Light Antarctic  
38 Precipitation) scale using the equation of Kim *et al.* (2015):

$$\delta^{18}\text{O (SMOW)} = 1.03091 \times \delta^{18}\text{O (V-PDB)} + 30.91$$

39  
40  
41  
42  
43  
44  
45  
46 The δ<sup>18</sup>Oc values measured in carbonate were then converted into an estimated value  
47 phosphate fraction equivalent, δ<sup>18</sup>Op for comparison with published values, using the  
48 equation of Bryant *et al.* (1996):

$$\delta^{18}\text{Op} = (\delta^{18}\text{Oc} - 8.3)/1.02\text{‰}$$

49  
50  
51  
52  
53  
54 Finally, a theoretical value for the oxygen isotopic composition of the drinking water  
55 available at the time of tooth enamel mineralisation, δ<sup>18</sup>Ow, usually assumed to be equivalent  
56 to local rain water values, was calculated using the equation of Levinson *et al.* (1987):  
57  
58  
59  
60

$$\delta^{18}\text{O}_w = (\delta^{18}\text{O}_p - 19.4)/0.46$$

### Dietary stable isotope analysis

Collagen for carbon and nitrogen stable isotopic analysis was prepared from the dentine of the tooth crown. The sample was demineralised using 10ml aliquots of 0.5M HCl solution at 4°C. The acid was changed at 48 hour intervals until no further reaction was seen. The sample was then rinsed three times with milli- $\mu$  ultra-pure water and placed in 10ml of pH3 water at 75°C for 48 hours. The sample was filtered using an Eezee™ filter, and the supernatant liquid decanted into a Nalgene™ tube with a temporary Parafilm™ cover. The sample was pre frozen at -40°C prior to freeze drying in a Zirbus VaCo5 freeze drier fitted with an oil free vacuum system for 72 hours.

The resulting purified collagen was weighed out for analysis using *c.* 1mg aliquots weighed into pre-cleaned tin capsules. Samples were combusted on a Sercon GSL elemental analyser system using a helium carrier gas with a flow of approximately 80ml per minute. A 2% split of the gases evolved was analysed for nitrogen and carbon stable isotopic composition using a Sercon -20/22 gas source mass spectrometer. Isotopic values, as well as elemental abundances and carbon-to-nitrogen ratios, were calibrated against an Oxford *in-house* alanine standard, which itself is routinely measured against international standards (USGS 40 and USGS 41 glutamic acid, whose values are traceable back to the V-PDB and AIR international standards for carbon and nitrogen, respectively). Further aliquots of the alanine standard were used to monitor and correct for instrumental drift. The sample was run in triplicate. Stable isotopic results were reported in delta notation relative to V-PDB for carbon and AIR for nitrogen. Replicate analysis of the alanine *in-house* standard gave the following results (n = 10 measurements): mean  $\delta^{13}\text{C} = -27.15 \pm 0.13\text{‰}$ , expected value -27.11‰; mean  $\delta^{15}\text{N} = -1.55 \pm 0.15\text{‰}$ , expected value -1.56‰. This suggests that the individual values obtained during the analyses reported here are typically accurate to better than  $\pm 0.1\text{‰}$  for both  $\delta^{13}\text{C}$  and  $\delta^{15}\text{N}$ .

### Results

The isotopic results from the sample analysed in this study are given in **Table S4**. The collagen prepared from the tooth dentine gave a C/N ratio of 3.1, suggesting that the collagen was well preserved and likely to give a good measure of the *in-vivo* dietary carbon and nitrogen stable isotopic values (van Klinken 1999). The collagen prepared from the dentine fraction of the tooth gave a  $\delta^{15}\text{N}$  value of 11.71‰ relative to AIR, and a  $\delta^{13}\text{C}$  value of -

19.03‰ relative to V-PDB, both with error of  $\pm 0.2\%$ . The tooth enamel carbonate fraction of the sample gave  $\delta^{13}\text{C}_c$  value of  $-12.78\% \pm 0.01$  and a  $\delta^{18}\text{O}_c$  value of  $-6.47 \pm 0.02$  both relative to V-PDB. Tooth enamel also gave an  $^{87/86}\text{Sr}$  ratio of  $0.710279 \pm 0.000014$ .

**Table S4: Stable isotopic data from Oakridge individual.**

Tooth sampled	Tissue type	C:N ratio	$\delta^{15}\text{N}$ (AIR)	$\delta^{13}\text{C}$ (V-PDB)	$\delta^{13}\text{C}_c$ (V-PDB)	$\delta^{18}\text{O}_c$ (V-PDB)	$\delta^{18}\text{O}_p$ (VSMOW)	$^{87/86}\text{Sr}$
ULM1	dentine	3.1	11.71	-19.03	---	---	---	---
ULM1	enamel	n/a	---	---	-12.778	-6.471	24.239	0.7103

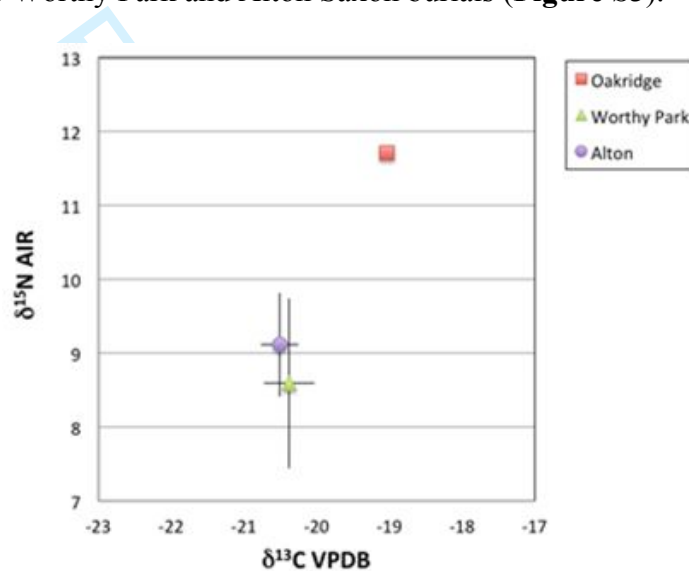
## Discussion

The calculated  $\delta^{18}\text{O}_w$  value for the tooth enamel in this study was  $-9.22\%$  SMOW, whereas modern ground water  $\delta^{18}\text{O}$  values for the area where the sample was found are around  $-7\%$  SMOW (Darling & Talbot 2003). The conversion of measured carbonate values to theoretical phosphate values, and thence to probable water values, is fraught with uncertainty regarding the factors in the equations used to make the conversions (see Pollard *et al.* 2011 for discussion). However, in this instance, there seems to be sufficient difference between the likely drinking water composition at the time of tooth mineralisation, and the modern ground water composition at the location where the sample was excavated, to suggest that this individual was probably non-local.

The strontium isotopic composition of tooth enamel is strongly influenced by the underlying geology at the time of tooth mineralisation (Bentley 2006; Chenery *et al.* 2010). The underlying bedrock geology of the site area is upper Cretaceous chalk of the Seaford Chalk Formation, with typical  $^{87/86}\text{Sr}$  ratios of between 0.708 and 0.709 (Evans *et al.* 2010). However, the site lies relatively close to the boundary of the overlying Tertiary rock of the Lambeth Group and the London Clay Formation, which have typical  $^{87/86}\text{Sr}$  ratios of between 0.709 and 0.710 (Evans *et al.* 2010). The tooth enamel  $^{87/86}\text{Sr}$  ratio value measured from the Oakridge individual was  $0.710279 \pm 0.000014$ , which falls well outside of the range for the local chalk and just outside of the range for the nearby Tertiary sediments. This also suggests that this individual was probably not local; that is, she did not spend her early years, during the time of M1 mineralisation, in the immediate area around Basingstoke.

The dentine collagen carbon and nitrogen stable isotopic results, of  $\delta^{13}\text{C}$   $-19.03\%$  (V-PDB) and  $\delta^{15}\text{N}$  of  $11.71\%$  (AIR) respectively, suggest a predominantly terrestrial diet with a minor marine protein component. However, in the absence of any associated faunal remains

from the same location, it is impossible to give an absolute indication of what these values might mean in terms of the relative amounts of plant versus terrestrial animal versus marine protein consumed. Comparable local dietary isotopic data sets are available from Worthy Park near Winchester, Hampshire (*ca.* 25 kilometres southwest of Basingstoke), and Alton, Hampshire (*ca.* 15 kilometres to the southeast) (Hull 2008). These sites have yielded mean  $\delta^{13}\text{C}$  values for adult human bone collagen of  $-20.38\text{‰}$  and  $-20.51\text{‰}$ , with a standard deviation of 0.35 ( $n = 26$ ) and 0.26 ( $n = 25$ ) respectively, and mean  $\delta^{15}\text{N}$  values of  $8.59\text{‰}$  and  $9.11\text{‰}$ , with a standard deviation of 1.15 ( $n = 26$ ) and 0.70 ( $n = 25$ ) respectively. By comparison, the values for the Oakridge individual are higher in both  $\delta^{13}\text{C}$  and  $\delta^{15}\text{N}$  than the means reported for the Worthy Park and Alton Saxon burials (**Figure S3**).



**Figure S3. Oakridge collagen stable isotopic composition compared to two other inland human assemblages from Hampshire (Hull 2008).**

This suggests that the diet of the Oakridge individual was slightly anomalous compared to the average diet that might be expected for inland Hampshire in middle Saxon times, with the less negative value for  $\delta^{13}\text{C}$  and the more positive value for  $\delta^{15}\text{N}$  suggesting more of a marine component in the Oakridge diet than usual for inland Hampshire. Taken alongside the strontium and oxygen isotopic data, the dietary stable isotopic information is also compatible with a probable non-local origin for this individual.

#### 4. ANCIENT DNA ANALYSIS

##### Sampling and extraction

The same left maxillary first molar that had been selected for the stable isotopic analyses was also sampled for ancient DNA. Sample processing was done at the Ancient DNA Facility of the University of Huddersfield (England) under dedicated clean-room conditions supplied by a positive air pressure system. Full body suits, hairnets, gloves and face masks were worn throughout the sampling, extraction and library preparation processes. All tools and surfaces were constantly cleaned with bleach, LookOut® DNA Erase (SIGMA Life Sciences), as well as with ethanol and long exposures to UV light.

The surface of the tooth root was decontaminated by UV radiation for 30 minutes on each side, followed by cleaning with 5µm aluminium oxide powder using a compressed air abrasive system. The root was removed using a diamond-tipped cutting saw attached to a hobby drill, and this was then shaken with a steel ball inside a metal shaker in a Mixer Mill (Retsch MM400) for 30 seconds at 30Hz frequency. DNA was extracted from approximately 150mg of the sample tooth root powder produced, following the protocol by Yang *et al.* (1998) with modifications by MacHugh *et al.* (2000). Blank controls were included throughout the sampling procedure, extraction and library preparation to allow for estimation of possible modern DNA contamination.

##### Library preparation

Next-generation sequencing libraries were constructed from DNA extracts using the methods by Meyer & Kircher (2010) and Kircher *et al.* (2012), with modifications outlined in Gamba *et al.* (2014) and Martiniano *et al.* (2014). All DNA purification steps were performed using the QIAQuick MinElute purification kit (Qiagen) following the manufacturers protocol, with the modification of adding 0.05% Tween 20 (Fisher BioReagents) to the Elution Buffer. Three dual-indexed libraries were prepared for this sample as follows.

After treatment with USER (Uracil-Specific Excision Reagent) enzyme (NEB) for 3 hours at 37°C, the sample DNA underwent blunt-end repair step using NEBNext® End Repair Module (NEB) for 15 minutes at 25°C followed by 5 minutes at 12°C. The sample was cleaned using a QIAQuick MinElute PCR purification kit (Qiagen), and then adapter ligation was performed using T4 DNA polymerase buffer (Thermo Scientific) at 22°C for 30

1  
2  
3 minutes. After another QIAQuick purification step, the adapter fill-in step involved *Bst* DNA  
4 Polymerase (NEB) at 37°C for 30 minutes, followed by heat inactivation of 20 minutes at  
5 80°C. Dual-indexing amplifications were set up using AmpliTaq Gold (5U/μl), Thermopol  
6 reaction buffer (10x), dNTPs (10mM each), both indexing primers (10μM each) and 10μl  
7 DNA sample library. The following thermal cycling steps were used for amplification: 12  
8 minutes at 95°C, followed by 10 cycles of 20 seconds at 95°C, 30 seconds at 60°C and 40  
9 seconds at 72°C, and then a final extension step of 5 min at 72°C. The amplification product  
10 was purified using the QIAQuick kit.  
11  
12

13  
14  
15 For the second amplification round, Accuprime *Pfx* Supermix (Life Technology) was  
16 used, together with primers IS5 (10μM), IS6 (10μM) and 2.5μl of sample library.  
17 Amplification took place under the following thermal cycling conditions: 30 seconds at 98°C,  
18 followed by 10 cycles of 20 seconds at 98°C, 30 seconds at 60°C and 40 seconds at 72°C,  
19 and then a final extension of 5 minutes at 72°C. The amplification products were purified as  
20 described above, and quantified using a Qubit 3.0 Fluorometer, before quantifying the  
21 libraries using an Agilent 2100 Bioanalyzer High Sensitivity DNA kit in order to pool them  
22 together in an equimolar solution. NGS libraries were sequenced on an Illumina HiSeq2500  
23 (1x100bp) by NBAF Liverpool.  
24  
25  
26  
27  
28  
29  
30  
31  
32

### 33 **Data processing and read mapping**

34  
35 The NGS reads were trimmed using cutadapt (v.1.13; Martin 2011), allowing a minimum  
36 overlap of 1 base pair (bp) between read and adapter (adapter sequence:  
37 AGATCGGAAGAGCACACGTCTGAACTCCAGTCAC), and discarding reads shorter than  
38 30bp. BWA aln (v. 0.7.12-r1039; Li & Durbin 2009) was used to map reads to both the  
39 human mitochondrial genome (rCRS) and the human reference genome (UCSC hg19),  
40 filtering by base quality 15, and disabling seed length as recommended for ancient DNA data  
41 (Schubert *et al.* 2012). Samtools (v.1.3) was used to sort and filter reads, and to remove  
42 amplification duplicates.  
43  
44  
45  
46  
47  
48  
49

### 50 **Ancient DNA authenticity**

51  
52 To assess the anti-contamination measures described above, negative controls were  
53 introduced during each stage of sample processing. An air control and a water control were  
54 included at the drilling and powdering stage. The air control consisted of an empty 1.5ml  
55 Eppendorf tube, which was placed for one hour with an open lid in the cleaned work area  
56  
57  
58  
59  
60

1  
2  
3 between sample processing. For the water control, 2ml of ddH<sub>2</sub>O was shaken with a steel ball  
4 inside a metal shaker in a Mixer Mill (Retsch MM400). 1ml of the water control was then  
5 taken through the complete extraction protocol. Controls introduced during the extraction  
6 process were quantified using a Qubit 3.0 Fluorometer. Negative controls from the extraction,  
7 the USER treatment, and the amplification step (x2) were sequenced alongside the three  
8 sample libraries on an Illumina HiSeq2500, using 100bp single-end reads.  
9  
10  
11  
12  
13

14 The two main patterns of typical ancient DNA post-mortem degradation – over-  
15 representation of C to T changes at the end of reads, and short sequence length – were  
16 assessed using mapDamage 2.0 (Jónsson *et al.* 2013) and bamdamage (Malaspinas *et al.*  
17 2014). Reads were only taken into account if they had a minimum mapping quality of 30.  
18  
19  
20

### 21 **Genetic sexing and mitochondrial haplotype calling**

22  
23 To determine the sex of the analysed ancient sample, a software was used that calculates the  
24 ratio of reads aligning to the X and Y chromosome reads from the whole genome dataset  
25 (Skoglund *et al.* 2013). The mitochondrial haplotype was determined by aligning the  
26 sequence reads to the revised Cambridge Reference Sequence (rCRS, NC\_012920; Andrews  
27 *et al.* 1999), using BWA aln filtering (with -b and -q 30) and removal of duplicate reads. The  
28 mtDNA consensus sequence was called using Samtools mpileup, as in Martiniano *et al.*  
29 (2016). Haplofind (Vianello *et al.* 2013) was used to identify haplogroup defining mutations  
30 and assign the haplogroup of the sample. The mtDNA coverage was estimated using EAGER  
31 (Peltzer *et al.* 2016).  
32  
33  
34  
35  
36  
37  
38  
39

### 40 **Results**

41  
42 The DNA content of all the controls introduced during the extraction process was too low to  
43 be measured. Amplification reactions were quantified using a Qubit 3.0 Fluorometer (**Table**  
44 **S5**).  
45  
46  
47  
48  
49  
50  
51  
52  
53  
54  
55  
56  
57  
58  
59  
60

**Table S5. Qubit measurements of the sequencing libraries.**

ID	DNA concentration (ng/μl)
USER blank	1.40
Sample Library 1	6.74
Sample Library 2	14.00
Sample Library 3	4.73
Amplification blank	0.88
Negative control library	0.99
Amplification blank	0.81

The contamination of all control samples was estimated to be lower than 0.5% (Gamba *et al.* 2014). The program *schmutzi* (Renaud *et al.* 2015) was used to detect introduction of modern mitochondrial contamination in the sample, with estimates ranging from 0.12% to 0.17%, which is very low. The two main patterns of post-mortem degradation were assessed and the reads from the sample showed an increase in C to T and G to A transitions towards the 5' and 3' ends, which are characteristic changes of ancient molecules (Briggs *et al.* 2007; Brotherton *et al.* 2007). Although many sequences had a length of 100bp, this was inflated as the sample was sequenced using 100bp single-end sequencing. Sequences greater than 100bp were truncated but, in keeping with the DNA being from an ancient source, the average sequence length was less than 100bp. The NGS sequencing results are displayed in **Table S6**.

**Table S6. Next-generation sequencing results for the Oakridge individual.**

Genome coverage	1.0143x
Contamination estimate	0.145% (0.12-0.17)
Mean mapping quality	12.029
GC content in %	45.61
Number of mapped reads	65,698,100
Number of mapped bases	3,260,000,000
Duplication rate	2.67%

The endogenous DNA content retrieved from the sample was calculated to be 70.08%. The ratio of reads aligning to the X and Y chromosome allowed an unambiguous classification of the sample as genetically female (XX) (**Table S7**).

**Table S7. Molecular sex assignment of the Oakridge individual.**

Ry	Standard error	95% confidence interval	Assignment
0.0023	0	0.0022-0.0024	female

The coverage of the mitochondrial genome was over 42x, and the individual was found to have all the defining mutations of haplogroup H3g1a (**Table S8**).

**Table S8. Mitochondrial haplogroup and haplotype for the Oakridge individual.**

Coverage	Haplogroup	Haplotype
42.29x	H3g1a	152C 263G 750G 1438G 2523Y 3992T 4135C 4418C 4769G 6776C 8251A 8860G 10754C 15326G 15377G 16519C

## Discussion

As morphological indicators were unable to identify the sex of the Oakridge individual (mainly due to partial remains and young age of the individual), the sex was determined genetically. From extracting and analysing the DNA, the person was found to be female.

She had a mitochondrial haplotype of H3g1a. Today, over 40% of all maternal lineages in Europe belong to haplogroup H. H3 has high frequency in modern-day Spain (Achilli *et al.* 2004) and in the Western Isles of Scotland (Brotherton *et al.* 2013), and is also present in the middle Neolithic period (including at Orkney) and the Bell Beaker culture in Europe (Brotherton *et al.* 2013; Olalde *et al.* 2018). H3g1 is generally seen in modern-day north-western European people, with the root comprising solely of people from Denmark (data not shown), although English, Scottish, Welsh, German and Dutch people also group within the H3g1 clade. Unfortunately, nothing can be said about the origin of the female based on her maternal lineage. Looking at the nuclear DNA, the Oakridge specimen falls within the pattern of genetic variation seen amongst other post-Roman and Anglo-Saxon individuals that have been analysed from elsewhere in Britain. There is no evidence of African genetic input in this individual.

## 5. LITERATURE CITED

- Achilli A., Rengo C., Magri C., Battaglia V., Olivieri A., Scozzari R., Cruciani F., Zeviani M., Briem E., Carelli V., Moral P., Dugoujon J.M., Roostalu U., Loogväli E.L., Kivisild T., Bandelt H.-J., Richards M., Villems R., Santachiara-Benerecetti A.S., Semino O. & Torroni A. (2004) The molecular dissection of mtDNA haplogroup H confirms that the Franco-Cantabrian glacial refuge was a major source for the European gene pool. *American Journal of Human Genetics* **75**, 910-918.
- Al Qahtani S.J. (2008) *Atlas of Tooth Development and Eruption*. London: Queen Mary University of London.
- Al Qahtani S.J., Hector M.P. & Liversidge H.M. (2014) Accuracy of dental age estimation charts: Schour and Massler, Ubelaker and the London Atlas. *American Journal of Physical Anthropology* **154**, 70-78.
- Alhazmi, A., Vargas E., Palomo J.M., Hans M., Latimer B. & Simpson S. (2017) Timing and rate of spheno-occipital synchondrosis closure and its relationship to puberty *PloS One* **12**, e0183305–e0183305.
- Andrews R.M., Kubacka I., Chinnery P.F., Lightowlers R.N., Turnbull D.M. & Howell N. (1999) Reanalysis and revision of the Cambridge reference sequence for human mitochondrial DNA. *Nature Genetics* **23**, 147.
- Bentley R.A. (2006) Strontium isotopes from the earth to the archaeological skeleton: a review. *Journal of Archaeological Method and Theory* **13**, 135-187.
- Briggs A.W., Stenzel U., Johnson P.L., Green R.E., Kelso J., Prüfer K., Meyer M., Krause J., Ronan M.T., Lachmann M. & Pääbo S. (2007) Patterns of damage in genomic DNA sequences from a Neandertal. *Proceedings of the National Academy of Sciences USA* **104**, 14616-14621.
- Broca P. (1868) On the crania and bones of Les Eyzies, Dordogne. *Transactions of the International Congress of Prehistoric Archaeology* **3** 168-175.
- Bronk Ramsey C. (2017) Methods for summarizing radiocarbon datasets. *Radiocarbon* **59**, 1809-1833.

- 1  
2  
3 Bronk Ramsey C., Higham T.G.F., Owen D.C., Pike A.W.G. & Hedges R.E.M. (2002)  
4 Radiocarbon dates from the Oxford AMS System: Archaeometry Datelist 31.  
5 *Archaeometry* **44** (Supplement 1), 1-150.  
6  
7  
8  
9 Bronk Ramsey C., Higham T. & Leach P. (2004a) Towards high-precision AMS: progress  
10 and limitations. *Radiocarbon* **46**, 17-24.  
11  
12  
13 Bronk Ramsey C., Higham T., Bowles A. & Hedges R. (2004b) Improvements to the  
14 pretreatment of bone at Oxford. *Radiocarbon* **46**, 155-163.  
15  
16  
17 Brotherton P., Endicott P., Sanchez J.J., Beaumont M., Barnett R., Austin J. & Cooper A.  
18 (2007) Novel high-resolution characterization of ancient DNA reveals C > U-type base  
19 modification events as the sole cause of post mortem miscoding lesions. *Nucleic Acids*  
20 *Research* **35**, 5717-5728.  
21  
22  
23  
24 Brotherton P., Haak W., Templeton J., Brandt G., Soubrier J., Jane Adler C., Richards S.M.,  
25 Der Sarkissian C., Ganslmeier R., Friederich S., Dresely V., van Oven M., Kenyon R.,  
26 Van der Hoek M.B., Korfach J., Luong K., Ho S.Y.W., Quintana-Murci L., Behar  
27 D.M., Meller H., Alt K.W., Cooper A. & Genographic Consortium (2013) Neolithic  
28 mitochondrial haplogroup H genomes and the genetic origins of Europeans. *Nature*  
29 *Communications* **4**, 1764.  
30  
31  
32  
33  
34  
35 Bryant J.D., Koch P.L., Froelich P.N., Showers W.J., Genna B.J. (1996) Oxygen isotope  
36 partitioning between phosphate and carbonate in mammalian apatite. *Geochimica et*  
37 *Cosmochim Acta* **60**, 5145-5148.  
38  
39  
40  
41 Buikstra J.E. & Ubelaker D.H. (1994) *Standards for Data Collection from Human Skeletal*  
42 *Remains*. Fayetteville, Arkansas: Arkansas Archaeological Society.  
43  
44  
45 Chenery C., Müldner G., Evans J., Eckardt H. & Lewis M. (2010) Strontium and stable  
46 isotope evidence for diet and mobility in Roman Gloucester, UK. *Journal of*  
47 *Archaeological Science* **37**, 150-163.  
48  
49  
50  
51 Cohen A.S., Onions R.K., Siegenthaler R. & Griffin W.L. (1988) Chronology of the pressure-  
52 temperature history recorded by a granulite terrain. *Contributions to Mineralogy and*  
53 *Petrology* **98**, 303-311.  
54  
55  
56 Darling W.G. & Talbot J.C. (2003) The O & H stable isotopic composition of fresh waters in  
57 the British Isles. 1. Rainfall. *Hydrology and Earth System Sciences B* **7**, 163-181.  
58  
59  
60

- 1  
2  
3 Elliott M. & Collard M. (2009) Fordisc and the determination of ancestry from cranial  
4 measurements. *Biology Letters* **5**, 849-52.  
5  
6  
7 Evans J.A., Montgomery J., Wildman G. & Boulton N. (2010) Spatial variations in biosphere  
8  $^{87}\text{Sr}/^{86}\text{Sr}$  in Britain. *Journal of the Geological Society* **167**, 1-4.  
9  
10  
11 Gamba C., Jones E.R., Teasdale M.D., McLaughlin R.L., Gonzalez-Fortes G., Mattiangeli V.,  
12 Domboróczki L., Kóvári I., Pap I., Anders A., Whittle A., Dani J., Raczky P., Higham  
13 T.F.G., Hofreiter M., Bradley D.G. & Pinhasi R. (2014) Genome flux and stasis in a  
14 five millennium transect of European prehistory. *Nature Communications* **5**, 5257.  
15  
16  
17  
18 Howells, W.W. 1973. *Cranial variation in man. A study by multivariate analysis of patterns*  
19 *of difference among recent human populations*. Cambridge, Massachusetts: Harvard  
20 University.  
21  
22  
23  
24 Howells, W.W. 1989. *Skull shapes and the map. Craniometric analyses in the dispersion of*  
25 *modern Homo*. Cambridge, Massachusetts: Harvard University.  
26  
27  
28 Hull B.D. (2008) *Social Differentiation and Diet in Early Anglo-Saxon England: Stable*  
29 *Isotope Analysis of Archaeological Human and Animal Remains*. Unpublished D.Phil.  
30 thesis. Oxford: University of Oxford, p.364.  
31  
32  
33  
34 Jantz R.L. & Ousley S.D. (2005) *FORDISC 3: computerized forensic discriminant functions*  
35 (version 3.1). Knoxville: University of Tennessee.  
36  
37  
38 Jónsson H. Ginolhac A., Schubert M., Johnson P.L. & Orlando L. (2013) MapDamage2.0:  
39 Fast approximate Bayesian estimates of ancient DNA damage parameters.  
40 *Bioinformatics* **29**, 1682-1684.  
41  
42  
43  
44 Kim S.-T., Coplen T.B., & Horita J. (2015) Normalization of stable isotope data for  
45 carbonate minerals: Implementation of IUPAC guidelines. *Geochimica et*  
46 *Cosmochimica Acta* **158**, 276-289.  
47  
48  
49 King J. & Cole G. (2016) The Radiocarbon Dating of Human Remains from Seven Sites in  
50 North Hampshire, with Special Reference to the Results from Old Basing. *Proceedings*  
51 *of the Hampshire Field Club and Archaeological Society* **71**, 76-88.  
52  
53  
54  
55 Kircher M., Sawyer S. & Meyer M. (2012) Double indexing overcomes inaccuracies in  
56 multiplex sequencing on the Illumina platform. *Nucleic Acids Research* **40**, e3  
57  
58  
59  
60

- 1  
2  
3 Knüsel C.J. & Carr G.C. (1995) On the significance of the crania from the River Thames and  
4 its tributaries with comment by Richard Bradley. *Antiquity* **69**, 162.  
5  
6  
7 Levinson A.A., Luz B. & Kolodny Y. (1987) Variations in oxygen isotopic compositions of  
8 human teeth and urinary stones. *Applied Geochemistry Frontiers in Analytical*  
9 *Geochemistry-an IGC 2004 Perspective* **2**, 367-371.  
10  
11  
12  
13 Lewis J.E. (2008) Identifying sword marks on bone: criteria for distinguishing between cut  
14 marks made by different classes of bladed weapons. *Journal of Archaeological Science*  
15 **35**, 2001-2008.  
16  
17  
18  
19 Li H. & Durbin R. (2009) Fast and accurate short read alignment with Burrows-Wheeler  
20 transform. *Bioinformatics* **25**, 1754-1760.  
21  
22  
23 MacHugh D.E., Edwards C.J., Bailey J.F., Bancroft D.R. & Bradley D.G. (2000) The  
24 extraction and analysis of ancient DNA from bone and teeth: a survey of current  
25 methodologies. *Ancient Biomolecules* **3**, 81-102.  
26  
27  
28 Malaspinas A.S., Tange O., Moreno-Mayar J.V., Rasmussen M., DeGiorgio M., Wang Y.,  
29 Valdiosera C.E., Politis G., Willerslev E. & Nielsen R. (2014) bammds: a tool for  
30 assessing the ancestry of low-depth whole genome data using multidimensional scaling  
31 (MDS). *Bioinformatics* **30**, 2962-2964.  
32  
33  
34  
35 Martin M. (2011) Cutadapt removes adapter sequences from high-throughput sequencing  
36 reads. *EMBnet.journal* **17**, 10.  
37  
38  
39  
40 Martiniano R., Coelho C., Ferreira M.T., Neves M.J., Pinhasi R. & Bradley D.G. (2014)  
41 Genetic evidence of African slavery at the beginning of the trans-Atlantic slave trade.  
42 *Scientific Reports* **4**, 5994.  
43  
44  
45 Martiniano R., Caffell A., Holst M., Hunter-Mann K., Montgomery J., Müldner G.,  
46 McLaughlin R.L., Teasdale M.D., van Rheezen W., Veldink J.H., van den Berg L.H.,  
47 Hardiman O., Carroll M., Roskams S., Oxley J., Morgan C., Thomas M.G., Barnes I.,  
48 McDonnell C., Collins M.J. & Bradley D.G. (2016) Genomic signals of migration and  
49 continuity in Britain before the Anglo-Saxons. *Nature Communications* **7**, 10326.  
50  
51  
52  
53 Meyer M. & Kircher M. (2010) Illumina sequencing library preparation for highly  
54 multiplexed target capture and sequencing. *Cold Spring Harbor Protocols* **6**, 5448.  
55  
56  
57  
58 Míková J. & Denková P. (2007) Modified chromatographic separation scheme for Sr and Nd  
59 isotope analysis in geological silicate samples. *Journal of Geosciences* **52**, 221-226.  
60

- 1  
2  
3 Miles A.E.W. (1962) Assessment of the ages of a population of Anglo-Saxons from their  
4 dentition. *Proceedings of the Royal Society of Medicine* **55**, 881-886.  
5  
6  
7 Moorrees C.F.A., Fanning E.A. & Hunt Jr. E.E. (1963) Age variation of formation stages for  
8 ten permanent teeth. *Journal of Dental Research* **42**, 1490-1502.  
9  
10  
11 Olalde I., Brace S., Allentoft M.E., Armit I., Kristiansen K., Booth T., Rohland N., Mallick  
12 S., Szécsényi-Nagy A., Mittnik A., Altena E., Lipson M., Lazaridis I., Harper T.K.,  
13 Patterson N., Broomandkoshbacht N., Diekmann Y., Faltyskova Z., Fernandes D.,  
14 Ferry M., Harney E., de Knijff P., Michel M., Oppenheimer J., Stewardson K., Barclay  
15 A., Alt K.W., Liesau C., Ríos P., Blasco C., Miguel J.V., García R.M., Fernández A.A.,  
16 Bánffy E., Bernabò-Brea M., Billoin D., Bonsall C., Bonsall L., Allen T., Büster L.,  
17 Carver S., Navarro L.C., Craig O.E., Cook G.T., Cunliffe B., Denaire A., Dinwiddy  
18 K.E., Dodwell N., Ernée M., Evans C., Kuchařik M., Farré J.F., Fowler C., Gazenbeek  
19 M., Pena R.G., Haber-Uriarte M., Haduch E., Hey G., Jowett N., Knowles T., Massy K.  
20 Pfrengle S., Lefranc P., Lemercier O., Lefebvre A., Martínez C.H., Olmo V.G.,  
21 Ramírez A.B., Maurandi J.L., Majó T., McKinley J.I., McSweeney K., Mende B.G.,  
22 Modi A., Kulcsár G., Kiss V., Czene A., Patay R., Endródi A., Köhler K., Hajdu T.,  
23 Szeniczey T., Dani J., Bernert Z., Hoole M., Cheronet O., Keating D., Velemínský P.,  
24 Dobeš M., Candilio F., Brown F., Fernández R.F., Herrero-Corral A.M., Tusa S.,  
25 Carnieri E., Lentini L., Valenti A., Zanini A., Waddington C., Delibes G., Guerra-Doce  
26 E., Neil B., Brittain M., Luke M., Mortimer R., Desideri J., Besse M., Brücken G.,  
27 Furmanek M., Hałuszko A., Mackiewicz M., Rapiński A., Leach S., Soriano I., Lillios  
28 K.T., Cardoso J.L., Pearson M.P., Włodarczak P., Price T.D., Prieto P., Rey P.J., Risch  
29 R., Rojo Guerra M.A., Schmitt A., Serralongue J., Silva A.M., Smrčka V., Vergnaud  
30 L., Zilhão J., Caramelli D., Higham T., Thomas M.G., Kennett D.J., Fokkens H., Heyd  
31 V., Sheridan A., Sjögren K.G., Stockhammer P.W., Krause J., Pinhasi R., Haak W.,  
32 Barnes I., Lalueza-Fox C. & Reich D. (2018) The Beaker phenomenon and the genomic  
33 transformation of northwest Europe. *Nature* **555**, 190-196.  
34  
35  
36  
37  
38  
39  
40  
41  
42  
43  
44  
45  
46  
47  
48  
49  
50  
51 Peltzer A., Jäger G., Herbig A., Seitz A., Kniep C., Krause J. & Nieselt K. (2016) EAGER:  
52 efficient ancient genome reconstruction. *Genome Biology* **17**, 60.  
53  
54  
55  
56  
57  
58  
59  
60  
Pin C., Briot D., Bassin C. & Poitrasson F. (1994) Concomitant separation of strontium and  
samarium-neodymium for isotopic analysis in silicate samples, based on specific  
extraction chromatography. *Analytica Chimica Acta* **298**, 209-217.

- 1  
2  
3 Pollard A.M. & Heron C. (2008) *Archaeological Chemistry*. 2nd edition. Cambridge: Royal  
4 Society of Chemistry.  
5  
6  
7 Pollard A.M., Pellegrini M. & Lee-Thorp J.A. (2011) Technical note: Some observations on  
8 the conversion of dental enamel  $\delta^{18}\text{O}(\text{p})$  values to  $\delta^{18}\text{O}(\text{w})$  to determine human  
9 mobility. *American Journal of Physical Anthropology* **145**, 499-504.  
10  
11  
12 Ramsthaler F., Kreutz K. & Verhoff M. (2007) Accuracy of metric sex analysis of skeletal  
13 remains using Fordisc® based on a recent skull collection *International Journal of*  
14 *Legal Medicine* **121**, 477-482.  
15  
16  
17  
18 Reimer P.J., Bard E., Bayliss A., Beck J.W., Blackwell P.G., Bronk Ramsey C., Buck C.E.,  
19 Cheng H., Edwards R.L., Friedrich M., Grootes P.M., Guilderson T.P., Haflidason H.,  
20 Hajdas I., Hatté C., Heaton T.J., Hoffmann D.L., Hogg A.G., Hughen K.A., Kaiser  
21 K.F., Kromer B., Manning S.W., Niu M., Reimer R.W., Richards D.A., Scott E.M.,  
22 Southon J.R., Staff R.A., Turney C.S.M. & van der Plicht J. (2013) IntCal13 and  
23 Marine13 radiocarbon age calibration curves 0-50,000 years cal BP. *Radiocarbon* **55**,  
24 1869-1887.  
25  
26  
27  
28  
29  
30  
31 Renaud G., Slon V., Duggan A.T. & Kelso J. (2015) Schmutzi: estimation of contamination  
32 and endogenous mitochondrial consensus calling for ancient DNA. *Genome Biology*  
33 **16**, 224.  
34  
35  
36  
37 Saunders, S., DeVito C., Herring A., Southern R. & Hoppa R. (1993) Accuracy tests of tooth  
38 formation age estimations for human skeletal remains. *American Journal of Physical*  
39 *Anthropology* **92**, 173-188.  
40  
41  
42 Schubert M., Ginolhac A., Lindgreen S., Thompson J.F., Al-Rasheid K.A.S., Willerslev E.,  
43 Krogh A. & Orlando L. (2012) Improving ancient DNA read mapping against modern  
44 reference genomes. *BMC Genomics* **13**, 178.  
45  
46  
47  
48 Skoglund P. Storå J., Götherström A. & Jakobsson M. (2013) Accurate sex identification of  
49 ancient human remains using DNA shotgun sequencing. *Journal of Archaeological*  
50 *Science* **40**, 4477-4482.  
51  
52  
53  
54 van Klinken G.J. (1999) Bone collagen quality indicators for palaeodietary and radio carbon  
55 measurements. *Journal of Archaeological Science* **26**, 687-695.  
56  
57  
58  
59  
60

1  
2  
3 Vianello D., Sevini F., Castellani G., Lomartire L., Capri M. & Franceschi C. (2013)

4 HAPLOFIND: A new method for high-throughput mtDNA haplogroup assignment.

5  
6 *Human Mutation* **34**, 1189-1194.

7  
8  
9 WEA (1980) Recommendations for age and sex diagnoses of skeletons. *Journal of Human*

10 *Evolution* **9**, 517-549.

11  
12  
13 Yang D.Y., Eng B., Wayne J.S., Dudar J.C. & Saunders S.R. (1998) Technical note: improved

14 DNA extraction from ancient bones using silica-based spin columns. *American Journal*

15 *of Physical Anthropology* **105**, 539-543.