

A case of osteomyelitis variolosa from Roman Britain, and the introduction of smallpox to the Roman world

Haoyue Zhao¹ and Andrew Wilson² 

¹Macquarie University <haoyue.zhao@students.mq.edu.au>

²University of Oxford <andrew.wilson@arch.ox.ac.uk>

Abstract: This article presents a case of osteomyelitis variolosa from a skeleton excavated in the Western Cemetery at Cirencester (Corinium) in Britain, dated to the 3rd or 4th c. CE. This osteological condition is caused by the variola virus, the causative agent of smallpox, and is found in some individuals who have survived a childhood smallpox infection, the condition manifesting many years later. The significance of this discovery is that it indicates that smallpox had been introduced into the Roman world, and to Britain in particular, by the late 3rd or 4th c. CE. Rather than postulating a separate and unrecorded introduction of smallpox into the Roman empire, we suggest that this discovery strengthens the case for seeing the 2nd-c. Antonine Plague as an early form of smallpox.

Keywords: osteomyelitis variolosa, smallpox, Roman Britain, Cirencester, Antonine Plague, skeletal pathologies

Introduction

Osteomyelitis variolosa is an osteological condition caused by the variola virus (the causative agent of smallpox) and is found in some individuals who have contracted smallpox in childhood but survived. There may be both short-term and long-term osteological effects, and some of these may appear only some years or decades after the initial smallpox infection. Here we present a case of osteomyelitis variolosa identified in a skeleton from the Western Cemetery at Cirencester (Corinium) in Britain, dated to the 3rd or 4th c. CE. Its significance is that it makes a contribution to the current debate over the antiquity of smallpox, as it shows that smallpox was present in late 3rd- or 4th-c. Britain. The findings have implications also for our understanding of the 2nd-c. Antonine Plague, whose identification as smallpox has been hotly contested in recent years.

Identification of osteomyelitis variolosa in osteology

Viral infections are typically acute, often leaving insufficient time for the development of macroscopically discernible changes in bone before the resolution of the disease by recovery or the death of the victim.¹ However, smallpox (variola) stands out as one of the few viral diseases recognizable in the archaeological record through skeletal remains. Despite the fact that smallpox was declared in 1980 by the World Health Organization to have been eradicated after a worldwide vaccination campaign in the 1970s, adults who survived a childhood infection of smallpox continue to present at clinics in India and China with skeletal abnormalities.² This kind of bone involvement is called

¹ Grauer and Roberts 2019, 450.

² Khurana et al. 2019, 813; Tang et al. 2021.

osteomyelitis variolosa and occurs mainly in people who have had a smallpox infection in childhood – cases arising from a smallpox infection in adulthood are not unknown, but are very rare. The smallpox virus may directly infect bone marrow cells, disrupting the processes of bone growth and resorption (loss of bone cells that are absorbed back into the circulatory system) especially in its acute stage, or it may induce an autoimmune response that triggers inflammation, similar to the mechanisms observed in other viral arthritis.³ During smallpox epidemics in the 20th c., approximately 2–5% of affected children, or 0.25–0.5% of all patients, exhibited osteoarticular manifestations, most frequently affecting the elbows, wrists, ankles, hands, and feet.⁴ These osteoarticular complications typically appear between the first and fourth week of illness, initially presenting as gradual swelling around the joints and eventually affecting the adjacent long bones.⁵ It is thought that the reason children are affected is that their bones have not stopped growing, and the virus attacks the skeleton particularly through the physal growth plate, an area of cartilage towards the end of the long bones where longitudinal growth takes place.⁶ This would explain why the joints are particularly affected, and why those who contract smallpox in adulthood rarely show osteological damage, since the cartilage growth plate has been replaced by an ossified plate once growth stops. The resulting deformities from the osteoarticular complications may arise from reparative ossification and distortion, including the cessation of longitudinal bone growth, possibly due to the destruction of the physal growth plate.⁷ In those who survive a childhood infection, further complications may arise in adult life, continuing to progress into old age.

In the archaeological record, 11 individuals with potential smallpox bone involvement have been identified thus far. They come from France, England, Canada, Portugal, Peru, and the United States, and date between the 10th and 19th c. CE (Table 1).⁸ No individual before the 10th c. CE has previously been identified as having osteomyelitis variolosa.

Short-term and long-term sequelae of smallpox

Short-term consequences, or “sequelae”, of smallpox, such as skeletal involvement, typically manifest between one and six weeks following the onset of infection. During the incubation of smallpox, the virus may infect the bone marrow and cause inflammation and swelling of the soft tissue around joints, resulting in painful and restricted movement.⁹ The skeletal effects are typically but not always bilateral (affecting both the left and the right limbs), and characterized by nonsuppurative osteomyelitis with necrosis, suppurative (pus-producing) arthritis as a result of a secondary infection, and multifocal nonsuppurative arthritis.¹⁰ Five

³ Resnick and Niwayama 1995, 2529; Grauer and Roberts 2019, 450; Drago et al. 2020, 2; Oliveira et al. 2020, 8; Resnick and Niwayama 1995, 2529.

⁴ Cockshott and MacGregor 1958, 377; Cockshott and MacGregor 1959; Khurana et al. 2019.

⁵ Khurana et al. 2019, 813.

⁶ Cockshott and MacGregor 1958, 384–85; cf. Crawford et al. 2024, 68.

⁷ Singh 2010, 1001; Mugalur et al. 2015, 116.

⁸ Crawford et al. 2024, 67. They also cite a 12th case from North Shields, England (1711–1857), but in fact this is interpreted by the original study (Roberts et al. 2016) as a case of “phossy jaw,” caused by phosphorus poisoning, with smallpox considered and rejected as an alternative diagnosis.

⁹ Cockshott and MacGregor 1959, 58–59; Davidson and Palmer 1963, 688.

¹⁰ Cockshott and MacGregor 1959, 59; Davidson and Palmer 1963, 687; Plesca et al. 2013, 167; Shah et al. 2013.

A case of osteomyelitis variolosa from Roman Britain

Table 1.

Identified cases of osteomyelitis variolosa in medieval and early modern populations (after Crawford et al. 2024, 67, table 1, with additions and modifications).

No.	Location	Date	Age at death	Reference
1	Soham, Cambridgeshire, England	10th c.	5–6	Hall and Ponce 2019
2	Pont-sur-Seine, Aube, France	1022–1155	15–17	Darton et al. 2013
3	Aubeterre-sur-Dronne, Charente, France	11th–19th c.	N/A	Coqueugniot et al. 2022
4	Convent of Jacobins of Rennes, France	14th–18th c.	20–49	Colleter 2021
5	Sarilhos Grandes, Portugal	14th–19th c.	30–49	Magalhães et al. 2021
6	Serta, Portugal	15th–19th c.	unknown	Magalhães et al. 2021
7	Huanchaco, Peru (IG-493)	1540	1.5	Tschinkel et al. 2024
8	Huanchaco, Peru (IG-124)	1540	1.5	Tschinkel et al. 2024
9	Grimsby Cemetery, Ontario, Canada	1640–1650	young adult	Jackes 1983
10	Mummy Caves, Kagamil Island, Alaska	pre-1750	12	Ortner 2007
11	St Marylebone Old Church, London, England	1750–1851	4	Miles et al. 2008

archaeologically identified individuals, all under the age of 13, exhibit bone alterations indicative of these short-term effects, suggesting they did not survive long enough for more prolonged impacts of the disease to develop (Table 1, nos. 1, 7, 8, 10, 11).

Long-term manifestations are seen in individuals who survived the original smallpox infection longer. They include joint instability, diminished function, and restricted mobility. Additionally, necrosis in fusing joints may lead to epiphyseal fusion, resulting in bone distortion, malformation, and ankylosis (joint stiffness and rigidity).¹¹ These late-stage conditions are typically observed in individuals more than a decade after the smallpox infection, and may continue to progress and deteriorate for many years, until the individual's death.¹²

The primary distinction lies in the immediacy and type of skeletal involvement, with short-term effects being more reversible and less severe than the often irreversible, debilitating long-term conditions that emerge years after the initial disease episode. Skeletal evidence of short-term sequelae in adults is exceedingly rare, but smallpox should still be considered among the differential diagnoses when such lesions are observed.¹³ This is particularly relevant in the archaeological record, especially for periods when smallpox was less likely to have been endemic, as its impact on adults may have been less rare than suggested in the clinical literature.¹⁴ While later-stage lesions generally present bilaterally, some older clinical reports show that secondary pyogenic (suppurative or pus-producing) infections may occur unilaterally.¹⁵ Where lesions do present bilaterally, they are not necessarily precisely symmetrical.

¹¹ Cockshott and MacGregor 1959, 59; Davidson and Palmer 1963, 687; Crawford et al. 2024, 70.

¹² Cockshott and MacGregor 1959, 61; Margolis et al. 1978, 262; Purandarnath and Douraiswami 2011, 125; Nema et al. 2012, 3426; Khurana et al. 2019, 813; Tang et al. 2021, 6.

¹³ Crawford et al. 2024, 70.

¹⁴ Crawford et al. 2024, 70.

¹⁵ Cockshott and MacGregor 1958, 378; Cockshott and MacGregor 1959, 61; Crawford et al. 2024, 70.

Lesion distribution

The most clearly diagnostic skeletal indicator of osteomyelitis variolosa is involvement of the arms, and particularly the bilateral involvement of the elbow joints.¹⁶ As the key work on the archaeological identification of osteomyelitis variolosa, by Crawford et al., puts it: “Elbow involvement was documented in 80% of smallpox patients displaying bone involvement, and bilaterality was a key feature, which Cockshott and Macgregor (1958) stated was present on radiographs even when the condition was presenting unilaterally externally.”¹⁷ In all published archaeological cases of osteomyelitis variolosa, lesions are recorded on both elbows unless only one has been preserved.¹⁸ An additional characteristic feature of this condition is that it affects all three bones of the arm – the humerus, radius, and ulna – where the pathology often initially manifests in the proximal radius and ulna.¹⁹

Lower limb involvement is also observed and may develop independently of the upper limb pathology.²⁰ In both acute and chronic stages, pathological alterations affect the joints, with chronic cases frequently exhibiting periosteal involucrum, a hallmark of persistent osteomyelitis. Osseous changes in the lower limbs include periosteal involucrum, a thickened layer of viable bone that forms in response to osteomyelitic inflammation, which has been recorded surrounding the epiphyses (the enlarged wide ends of long bones that articulate with the joints) of the tibia and fibula.²¹ Skeletal lesions have also been identified in the tibiae, fibulae, and femora of individuals who died of smallpox.²² Crawford et al. note: “The joints may also be affected, with ankle abnormalities seen in 18% of paediatric patients with bone involvement (Cockshott and MacGregor, 1959) and 50% of adults with typical late smallpox manifestations (Tang et al., 2021). In adult individuals with osteomyelitis variolosa, distortion of the calcaneus (such as flattening and shortening) is a commonly reported symptom, potentially due to long-term changes in mobility and weight bearing.”²³

Pathological involvement is not confined to the long bones but also affects the small bones of the hands and feet, where destruction of the epiphyses and arrested growth can occur.²⁴ Initially, the involvement of these bones is characterized by inflammatory lytic lesions – areas of bone resorption that create pitted defects on the bone surface.²⁴ Chronic cases may result in stunted, shortened digits; these too are typically bilateral.²⁵

Despite the extensive skeletal manifestations of osteomyelitis variolosa, certain regions remain largely unaffected. The ribs, spine, and pelvis are not involved,²⁶ and cranial

¹⁶ Cockshott and MacGregor 1959, 61; Davidson and Palmer 1963, 688; Ortner 2008, 212; Khurana et al. 2019, 813; Crawford et al. 2024, 72.

¹⁷ Crawford et al. 2024, 72.

¹⁸ Crawford et al. 2024, 72.

¹⁹ Crawford et al. 2024, 72.

²⁰ Cockshott and MacGregor 1958, 378; Cockshott and MacGregor 1959; Crawford et al. 2024, 72.

²¹ Cockshott and MacGregor 1959, 61; Crawford et al. 2024, 72, 74.

²² Crawford et al. 2024, 74.

²³ Crawford et al. 2024, 74.

²⁴ Crawford et al. 2024, 74.

²⁵ Ortner 2003, 355; Singh 2010, 1002; Crawford et al. 2024, 74.

²⁶ Crawford et al. 2024, 74.

manifestations are rare – to date, only a single clinical case of skull involvement has been documented, occurring in an eight-year-old girl, and three cases in archaeology, including two 1.5-year-old infants from Peru, and one 12-year-old child from Alaska.²⁷

Individual sk847 from Cirencester

The Western Cemetery of Roman Cirencester is situated at the former site of Bridges Garage on the western edge of modern Cirencester, approximately 130 m outside the town walls of Roman Corinium (Fig. 1). Excavations conducted by Cotswold Archaeology from September 2011 to February 2015 revealed a total of 118 inhumations and 8 cremation burials. Stratigraphic analysis identified two principal phases of use: Period 1, from the late 1st to early 3rd c. CE, and Period 2, from the late 3rd to 4th c. CE, although some burials defy precise chronological assignment.²⁸

Individual B1187, catalogued as sk847 in the Corinium Museum collection, was interred in a grave designated as 848, assigned stratigraphically to Period 2. The grave is sub-rectangular, with vertical sides and a flat base. The deceased was laid supine, with the right arm draped over the pelvis and the left arm across the abdomen, the body oriented northwest to southeast (Fig. 2). Archaeological finds within the grave included 14 iron coffin nails and 85 iron hobnails, which from their position at the skeleton's feet must derive from footwear, suggesting that the deceased was buried with shoes or sandals on, and probably other clothes too.²⁹ Ten residual sherds of Dorset Black-burnished ware from the grave fill date from the mid-3rd to 4th c. CE.³⁰ The grave cut two earlier burials (B1192, whose fill contained late 3rd- to 4th-c. pottery, and B1194, undated), and its fill was cut by another burial, B1189, whose fill contained residual material from the 2nd to 4th c. CE.³¹ Burial B1187 seems to date, therefore, to the later 3rd or to the 4th c. CE. Both the grave and associated finds were similar to other burials in the cemetery, and in the absence of isotopic studies, we cannot say whether this individual was born in Britain or migrated there later in life.

The skeleton is approximately 90% complete, with most elements at least partially preserved, and the bones are in very good condition. It is identified as a male aged between 41 and 50 years and displays a variety of lesions attributable to multiple etiologies.³² Osteophytes (bone spurs) on the thoracic vertebrae, left-hand phalanx, right wrists, and the glenoid cavity of the right scapula probably result from advanced age and repetitive joint use throughout the individual's lifetime. The remaining lesions observed are, we argue, caused by osteomyelitis variolosa, as sequelae of a smallpox infection in childhood.

²⁷ Cockshott and MacGregor 1959, 60; Ortner 2003, 335; Ortner 2007, 105; Tschinkel et al. 2024, 37.

²⁸ Holbrook et al. 2017.

²⁹ Wright et al. 2017, 39, listed under "grave goods". See Weekes 2019, 764.

³⁰ Wright et al. 2017, 39; the designation "TF74" for the pottery refers to fabric 74 of the Cirencester series, which is Dorset Black-burnished ware: McSloy in Holbrook et al. 2017, 92 and 93, Table 4.4.

³¹ Wright et al. 2017, 39, 41.

³² Geber 2017b, 26.

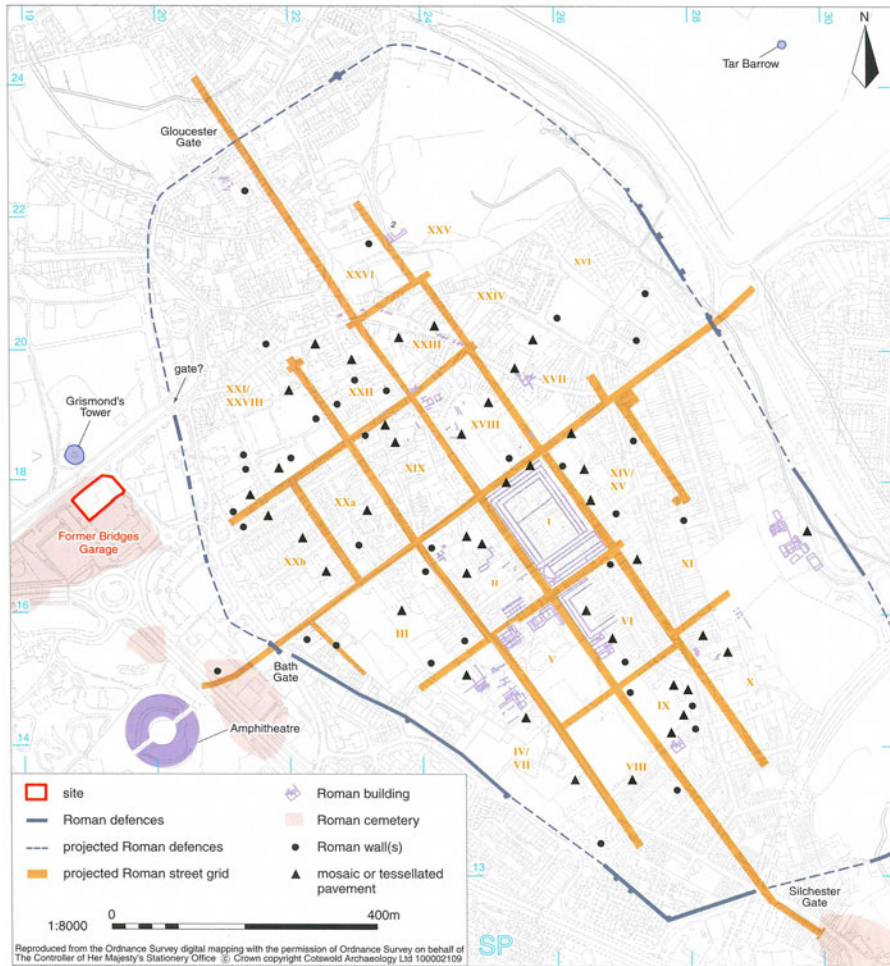


Fig. 1. Plan of Roman Corinium, and the location of the Western Cemetery, at the site of the former Bridges Garage. (Holbrook et al. 2017, 2, fig. 1.1, courtesy of Cotswold Archaeology.)

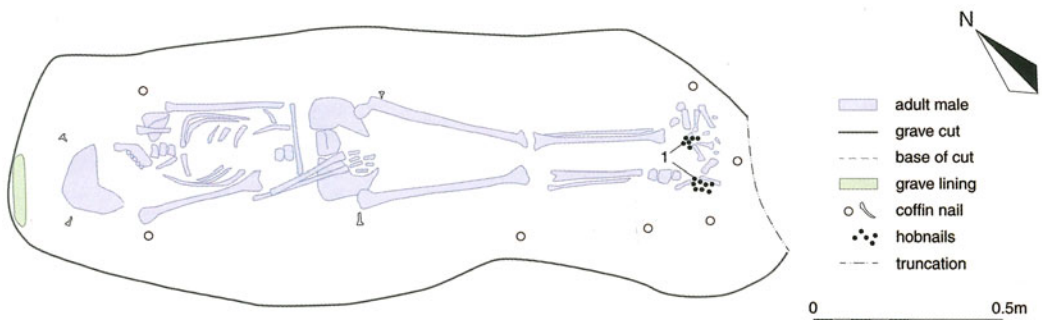


Fig. 2. Plan of burial B1187 at Cirencester, showing position of the skeleton sk847 and associated artifacts. Note the flexed left arm laid across the abdomen. (Wright et al. 2017, 38, fig. 3.44, courtesy of Cotswold Archaeology.)

During a comprehensive survey, undertaken by the first author, of skeletal pathologies across 209 cemeteries from Roman Britain, this burial was identified as being of particular interest, given the suggestion in the excavation report by the osteologist, Jonny Geber, that

the osteomyelitic infection of the left elbow joint might indicate smallpox, although he concluded that direct trauma was a more likely cause.³³ The most effective method of differentiating between the alternative hypotheses of osteomyelitis variolosa associated with smallpox and osteomyelitis as a result of direct trauma involves examining the distribution of the lesions across the skeleton, with particular emphasis on the presence of bilateral pathological changes in the elbows. Osteomyelitis variolosa frequently (but not always) presents bilaterally, especially in the elbows, while if osteomyelitic infection resulted from direct trauma one would expect it to be present in one elbow only. Permission was therefore sought and obtained from the Corinium Museum to study the bones at first hand, with the aim of resolving the question. A visit to the museum was undertaken on April 12, 2024, during which the pathology of the entire skeleton was thoroughly reassessed, with a particular emphasis on the right arm, for which less detail had been given in the excavation report.

Description of pathology

Multiple lesions and pathologies have been identified in individual sk847. Some pathologies present as degenerative changes, which are readily discernible, whereas others require more nuanced interpretation.

Lesions to be interpreted: elbows

The most noticeable pathological change on this individual is the badly deformed left arm, which was carefully documented by Geber. His report is worth quoting here (we have added numbers in square brackets, referring to Figure 3 in order to illustrate the technical terminology used):³⁴

Severe osteomyelitic infection of the left elbow joint, resulting in a 90° flexed ankylosis. The distal humerus is displaying sclerotic porotic new bone across the entire anterior and posterior surface of the epiphysis [1] and metaphysis [2], with nodular new bone on the interosseus margin [3]. The entire fossa [4] and condyle [5] is destroyed, and a 14×11 mm large cloaca [6] is present on the medial surface of the original location of the tubercle [7], and an abscess [8] would have been present transverse across the interior of the bone onto the lateral portion of the epiphysis. Considerable damage and infection are also evident of the entire olecranon³⁵ of the ulna, where a more lytic appearance is observed superior of the radial head articulation and a continuation of the abscess into the olecranon. The head of the radius does also display this lytic abscess, at the medial aspect (10×14 mm) [Fig. 4d]. The full extent of the osteomyelitic abscess, positioned within the elbow joint, would have been approximately 35×35 mm. The infection may indicate smallpox.

The left elbow joint thus exhibited complete destruction as a result of infection, with all three constituent bones – radius, ulna, and humerus – significantly affected (Figs. 3–4). The infection probably reached its most severe or acute stage within the marrow of the distal humerus, where the accumulation of pus started. As this accumulation of necrotic debris expanded, it compromised the structural integrity of the bone's cortex, leading to thinning of the cortex and the eventual formation of a cloaca – an opening through the

³³ Geber 2017a, 116; Geber 2017b, 26.

³⁴ Geber 2017b, 26.

³⁵ The proximal articular portion of the ulna, the tip of the elbow.

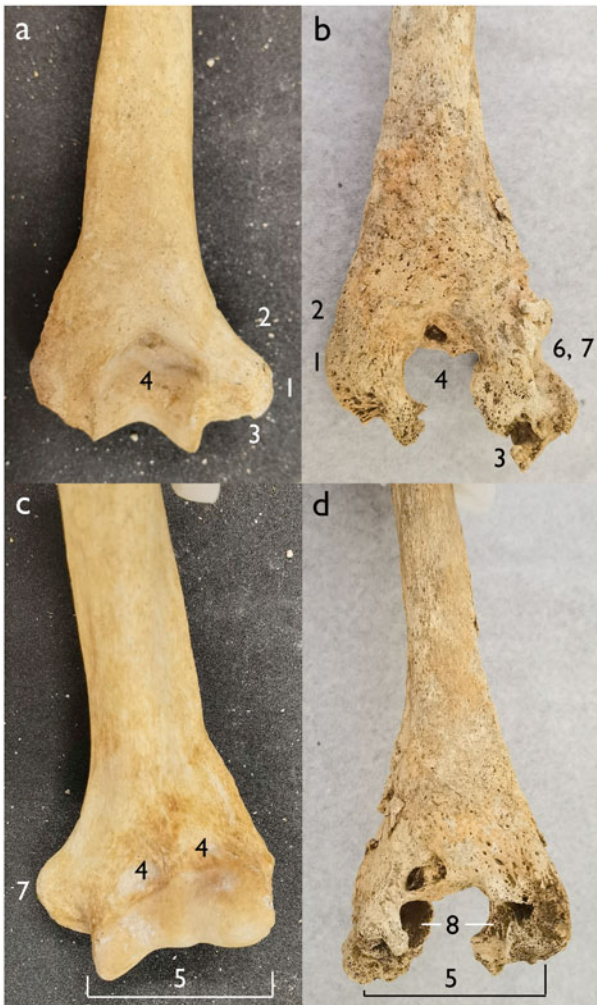


Fig. 3. Comparison between a normal left humerus, from a male adult 1040 from the Late Roman cemetery at Little Keep, Dorchester, dated to the 4th c. CE, and the left humerus of sk847 from Cirencester. (a) Posterior view of a normal left humerus. (b) Posterior view of the left humerus of sk847. (c) Anterior view of a normal left humerus. (d) Anterior view of the left humerus of sk847. Features mentioned in Geber's description are numbered as follows: 1. Epiphysis; 2. Metaphysis; 3. Nodular new bone on the interosseus margin; 4. Fossa; 5. Condyle; 6. Cloaca; 7. Tubercle (of the medial epicondyle). 8. Bone eaten away by abscess. (Photos: H. Zhao; montage: A. Wilson.)

cortex that facilitated the drainage of pus out of the bone (Fig. 3, no. 6; Fig. 4a). The bone damage here is also indicative of the effects typically associated with suppurative arthritis. In addition to these changes, bowing and bending of the radius and ulna are also evident (Fig. 4).

The left elbow joint also shows woven and lamellar bone formations, representing layers of new bone superimposed upon the original structure. These indicate a chronic alteration subsequent to the initial osteomyelitic infection, which resulted in the fusion of the humerus, radius, and ulna. Such skeletal changes categorically point to chronic osteomyelitis, a condition that probably beset the individual persistently throughout their lifetime. Chronic osteomyelitis commonly ensues from unresolved bone infections after attempts at intervention.³⁶ Particularly in pre-modern contexts, where pus may not have been thoroughly evacuated through a significant cloaca, the condition could be perpetuated by incompletely healed openings through the skin and the bone that facilitated subsequent secondary infections.³⁷ The pus drained out of the bone through the cloaca in the distal humerus mentioned above would have accumulated in the overlying tissue, causing inflammation and swelling; if this swelling either burst or was delib-

erately lanced, the site could easily have become infected. The multiple stages of bone destruction and new bone formation represented by the woven and lamellar bones and the destructive lesions suggest that this osteomyelitic transformation would probably

³⁶ Howard-Jones and Isaacs 2010, 737.

³⁷ Panteli and Giannoudis 2016, 132

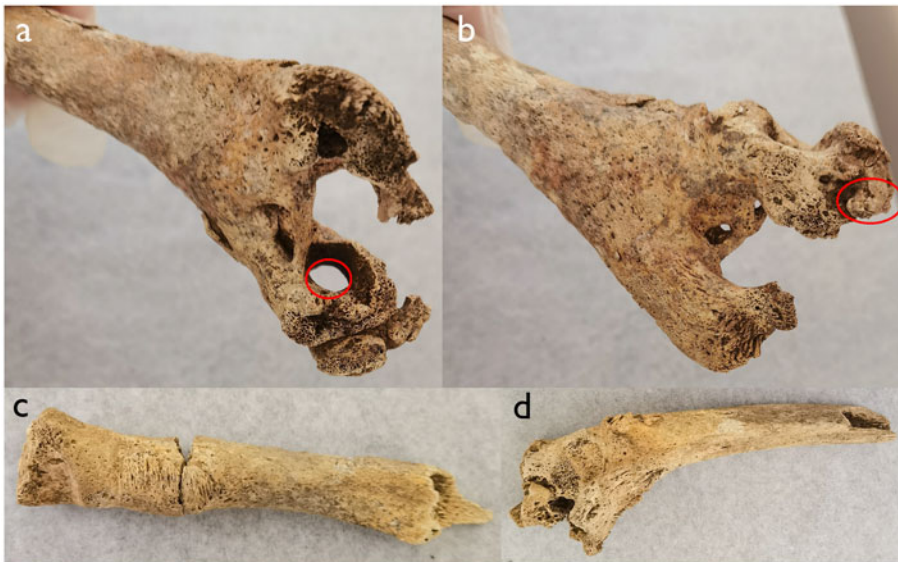


Fig. 4. The left elbow bones of sk847 from Cirencester. (a) Anterior view of humerus, showing the cloaca (circled). (b) Posterior view of humerus, showing the nodular new bone on the interosseus margin (circled). (c) Anterior view of radius. (d) Anterior view of left ulna. (Photos: H. Zhao; montage: A. Wilson.)

have manifested in intermittently active phases, corresponding with any decline in immune function over the years – a phenomenon still observed in contemporary clinical practices.³⁸

The pathology of the right elbow, which is not discussed in Geber's report, is detailed here for the first time (Figs. 5–8). Pitting and porosity are observed throughout the right distal humerus (Fig. 5), with the medial [1] and lateral [2] epicondyles being particularly affected. The distal humerus displays a bony outgrowth and thickening on the coronoid fossa [3]. The trochlea [4] is notably flattened, and the local surface of the bone appears uneven. In particular, the lateral part of the humerus, especially the lateral epicondyle, shows an area of lytic damage surrounded by porous reactive bone formation that extends approximately 32 mm towards the shaft's anterior surface near the capitulum [5]. The medial epicondyle exhibits bone growth and enlargement. The proximal side of the olecranon fossa [6] is uneven. Pathological changes on the coronoid fossa, the olecranon fossa, and the trochlea suggest degenerative changes, while the rest clearly indicate infections.

The right proximal ulna exhibits notable deformation and slight bending (Fig. 6a–d). The shaft displays flecks of darker coloration attributable to periostitis, that is, non-specific infection on bones. Both the olecranon [1] and coronoid process [2] are abnormally widened and thickened. Below the coronoid process, sclerotic porotic new bone growth extends beyond the original ulnar tuberosity [3], which has been destroyed by lesions. The trochlear notch [4] is rendered shallow and uneven, with bony growths or enthesophytes [5] measuring 9 × 2 mm in the center. Around and below the radial notch [6], pronounced bone thickening is evident.

³⁸ Panteli and Giannoudis 2016, 128.

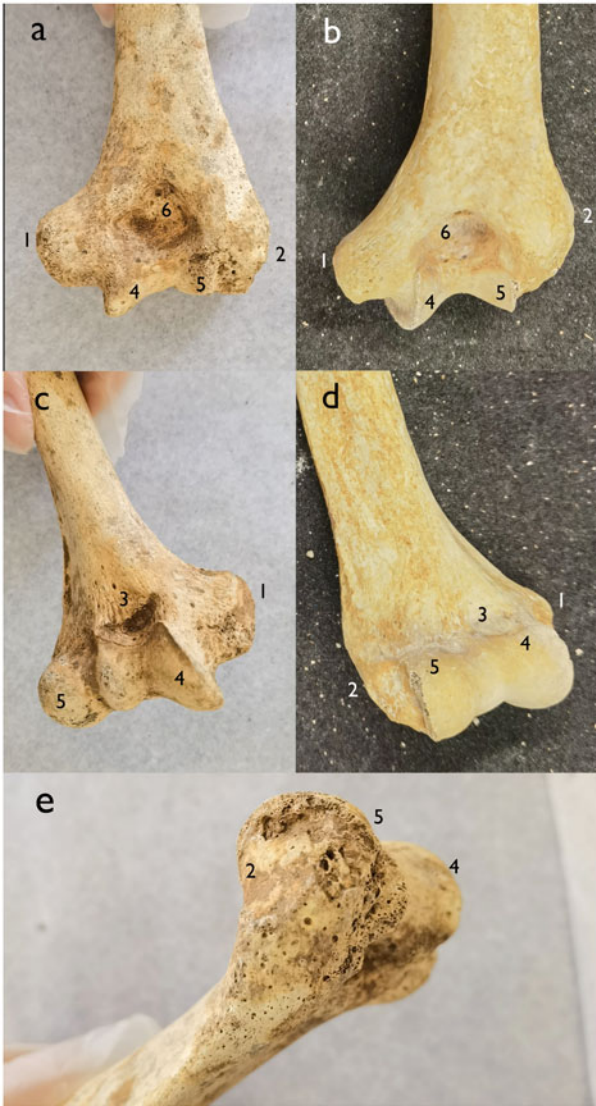


Fig. 5. Comparison between the right humerus from sk847 and a normal humerus. (a) Posterior view of humerus of sk847. (b) Posterior view of humerus of male adult 1040 from Little Keep. (c) Anterior view of humerus of sk847. (d) Anterior view of humerus of male adult 1040 from Little Keep. (e) Lateral epicondyle of individual sk847 showing the pathological changes. Features mentioned in the text discussing the right humerus are numbered as follows: 1. Medial epicondyle; 2. Lateral epicondyle; 3. Coronoid fossa; 4. Trochlea; 5. Capitulum; 6. Olecranon fossa. (Photos: H. Zhao; montage: A. Wilson.)

fection, the individual experienced difficulties adapting to the deformed arms. Ongoing secondary alterations – attributable either to chronic osteomyelitis, as observed in the left

The proximal section of the right radius also shows slight bending, with pitting and porosity along the remaining radius (Fig. 7). Periostitis resulting from infection is widespread along the shaft, particularly on the lateral side. The radial head features a bony outgrowth or enthesophyte centered on the surface, approximately 1 mm in diameter. The distal end of the radius is slightly enlarged with an uneven articular surface, suggestive of degenerative changes.

The enthesophytes on the radial head and trochlear notch may be attributed to repeated use.³⁹ The flexed ankylosis of the left elbow, locking the joint at a 90° angle, meant that the individual would probably have become increasingly unable to use his left arm and relied heavily on the right arm, resulting in greater labor stress on the bones of that arm. The general changes in the shape of the right radius and ulna, along with the bony growth below the radial notch, may suggest a dislocation of the radius and ulna. Although dislocations are challenging to observe directly in osteology due to the disturbance of bones, similar pathological changes indicative of dislocations have been noted in other case studies.⁴⁰

In summary, the right elbow and its associated structures show significant damage and indications of infection. Following the initial infec-

³⁹ Esposito et al. 2006, 855.

⁴⁰ E.g. Nikitovic et al. 2012.

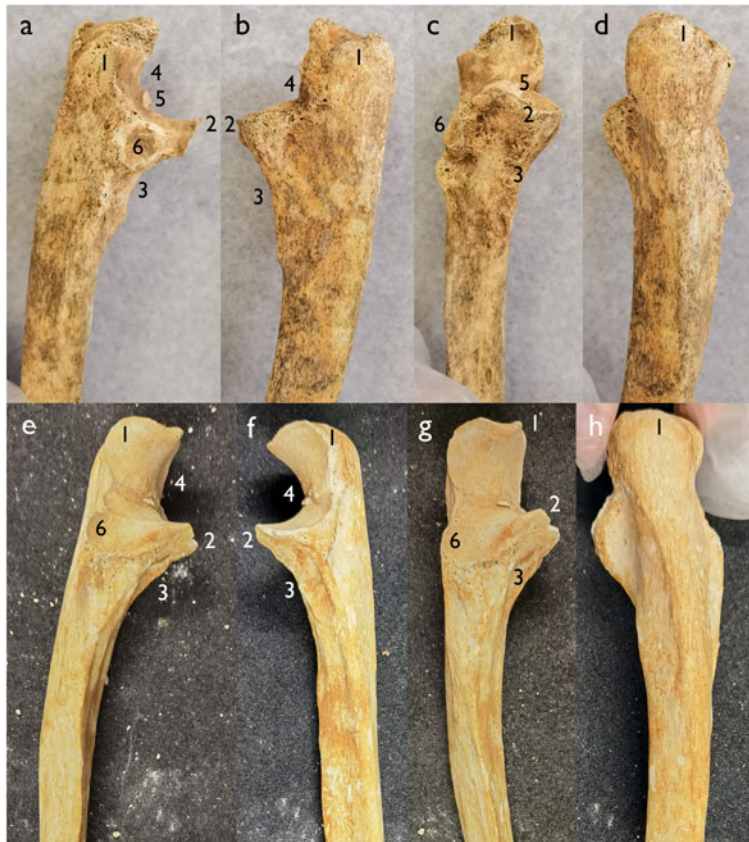

Fig. 6. Comparison between the right ulna from sk847 and a normal right ulna. (a)–(d) Right ulna of sk847. (e)–(h) Right ulna of male adult 1040 from Little Keep. Features mentioned in the text discussing the right ulna are numbered as follows: 1. Olecranon; 2. Coronoid process; 3. Ulnar tuberosity; 4. Trochlear notch; 5. Enthesophytes; 6. Radial notch. (Photos: H. Zhao; montage: A. Wilson.)

arm, or to repetitive biomechanical stress, as noted in the right arm – persisted throughout the individual’s life. Consequently, the normal architecture of the bilateral elbow joints was supplanted by deformities as time progressed, more severe on the left side than on the right (Fig. 8).

Lesions to be interpreted: feet and maxilla

Pathologies on the feet have been thoroughly documented by Geber although the distal tibiae and fibulae are badly preserved.⁴¹ Arthropathies (joint diseases) affecting both feet exhibit degenerative changes and the formation of bony lumps, or osteophytes, on multiple articular surfaces (the calcanei are shown in Figs. 9 and 10). The left foot shows irregular marginal osteophytes along joints near the ankle and the heel, including the calcaneo-talar facets, cuboid articulation, and navicular bone.⁴² Erosive lesions are found on the first metatarsal and its proximal phalanx (Fig. 11 [1, 4]).⁴³ The right foot displays marginal

⁴¹ Geber 2017b, 26.

⁴² Geber 2017b, 26.

⁴³ Geber 2017b, 26.

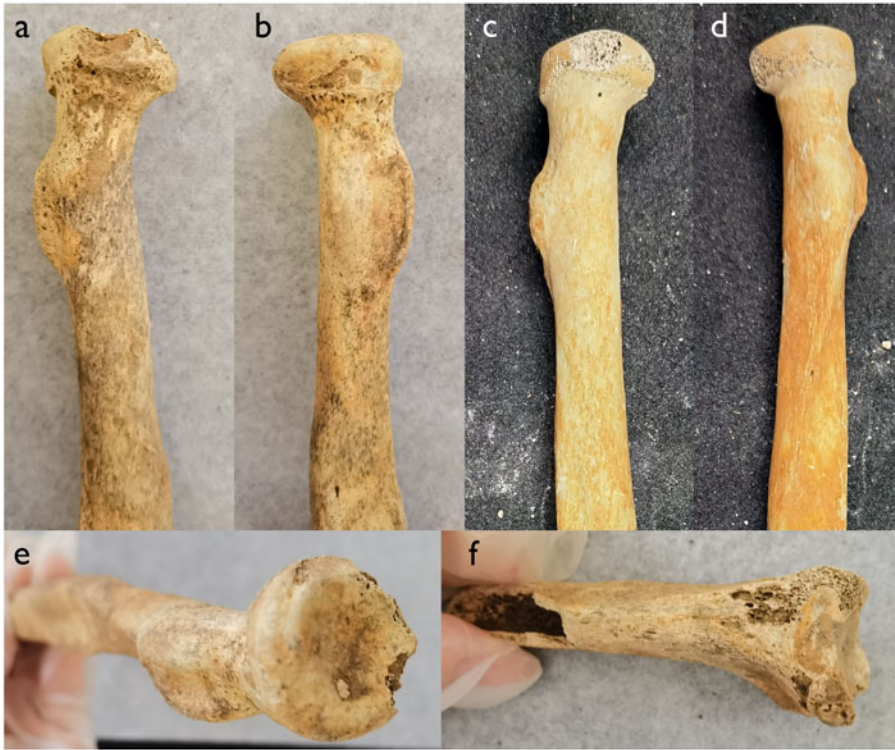


Fig. 7. Comparison between the right radius from sk847 and a normal right radius. (a), (b) Proximal right radius of sk847. (c), (d) Proximal right radius of male adult 1040 from Little Keep. (e) Proximal right radius of sk847; (f) Distal right radius of sk847. (Photos: H. Zhao; montage: A. Wilson.)

osteophytes on the talar and medial articulations of the calcaneus (the surface between two heel bones), and degenerative lesions along the articular surfaces in front of the heel, including the first cuneiform and navicular bones.⁴⁴ Additionally, erosive arthropathies affect the joint surface of the proximal phalanx of the right foot (Fig. 11 [2]).⁴⁵ An erosive lesion on the proximal side of the right first metatarsal is also evident (Fig. 11 [3]).⁴⁶

Although Geber categorizes the pathologies observed on both feet mostly as “degenerative changes”,⁴⁷ the evidence suggests a more complex condition, particularly affecting the calcanei, tali, first metatarsals, and their proximal phalanges. The presence of erosive lesions and extensive bone destruction transcends typical degenerative changes. In particular, both calcanei exhibit significant deformation and shortening relative to normal specimens (Fig. 10). Moreover, the subtalar joint is an uncommon site for the development of osteoarthritis, probably because of the greater thickness of its articular cartilage and different metabolic activities compared to other joints.⁴⁸ Attributing the foot lesions solely to degenerative changes therefore seems inadequate.

⁴⁴ Geber 2017b, 26.

⁴⁵ Geber 2017b, 26.

⁴⁶ This lesion is not mentioned by Geber.

⁴⁷ Geber 2017b, 26.

⁴⁸ Waldron 2019, 728.

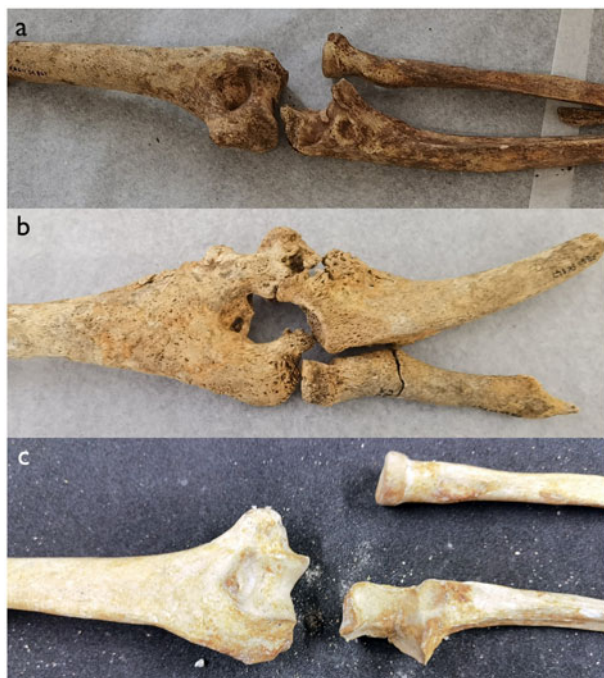

Fig. 8. The elbows of sk847 compared to a normal elbow. (a) Right elbow of sk847. (b) Left elbow of sk847; (c) Right elbow of male adult 1040 from Little Keep. The photos aim to show pathologies on the bones, not their original positions in human bodies. (Photos: H. Zhao; montage: A. Wilson.)

The dense sclerosis observed in the right maxillary sinus of SK847, which Geber attributes to maxillary sinusitis,⁴⁹ may either be linked to the same pathological process affecting the elbows and feet or represent a co-morbidity (discussed below in the section in differential diagnosis).

Degenerative changes

Degenerative alterations are predominantly observed in the spine, wrist, shoulder, and thigh – details meticulously documented by Geber. Notably, osteophytes are present on the right shoulder (the glenoid cavity of the right scapula), the right wrist (along the articular surfaces of the scaphoid, lunate, and capitate), and at vertebrae T7–8 in the spine.⁵⁰ These are probably associated with repetitive movement and labor during the individual's lifetime. The ossification of the ligamentum




Fig. 9. Calcanei of sk847 and a normal calcaneus. (a) Left calcaneus of sk847. (b) Right calcaneus of sk847. (c) Left calcaneus of male adult 1040 from Little Keep. (Photos: H. Zhao; montage: A. Wilson.)

⁴⁹ Geber 2017b, 26.

⁵⁰ Geber 2017b, 26.




Fig. 10. Calcanei of sk847 and a normal calcaneus; the red line shows the shortening of the calcanei of individual sk847 compared to individual 1040 from Little Keep. (a) Medial view of left calcaneus of 1040 from Little Keep. (b) Medial view of left calcaneus of individual sk847. (c) Medial view of right calcaneus of individual sk847. (Photos: H. Zhao; montage: A. Wilson.)

flavum (ligament in spine) in vertebrae T4 to T10 may be explained by mechanical stress.⁵¹ In particular, the abnormalities on the right scapula and right wrist may be explicable by the individual having had to rely increasingly on the right arm as the left elbow was inflamed and swollen and the joint ankylosed at a 90° angle. Possibly this asymmetrical reliance on the right arm, coupled with the effects on his gait of the degradation of his heel bones, may also have created stresses on his spine that could explain the pathology on the vertebrae too.

Additionally, an active patch of periosteal new bone formation was observed on the medial surface of the neck of the left femur, near the lesser trochanter, where the psoas major and iliacus muscles attach to the thighbone.⁵² This strongly suggests that it resulted from atypical muscle use during the individual's lifetime, lameness caused by the observed damage to the feet, rather than directly from infectious disease.

Differential diagnosis

This individual exhibits alterations in multiple joints, with the most severe manifestations observed in the elbows, and the talo-calcaneal and metatarso-phalangeal joints in the feet. Although these lesions are not perfectly symmetrical, they tend to be bilateral. Evidence of infection is clear, particularly in the suppurative arthritis observed in the left elbow and the widespread periostitis in the right elbow. The erosive lesions on the feet may also have

⁵¹ Geber 2017b, 26; Nakabachi et al. 2023, 638.

⁵² Geber 2017b, 26.

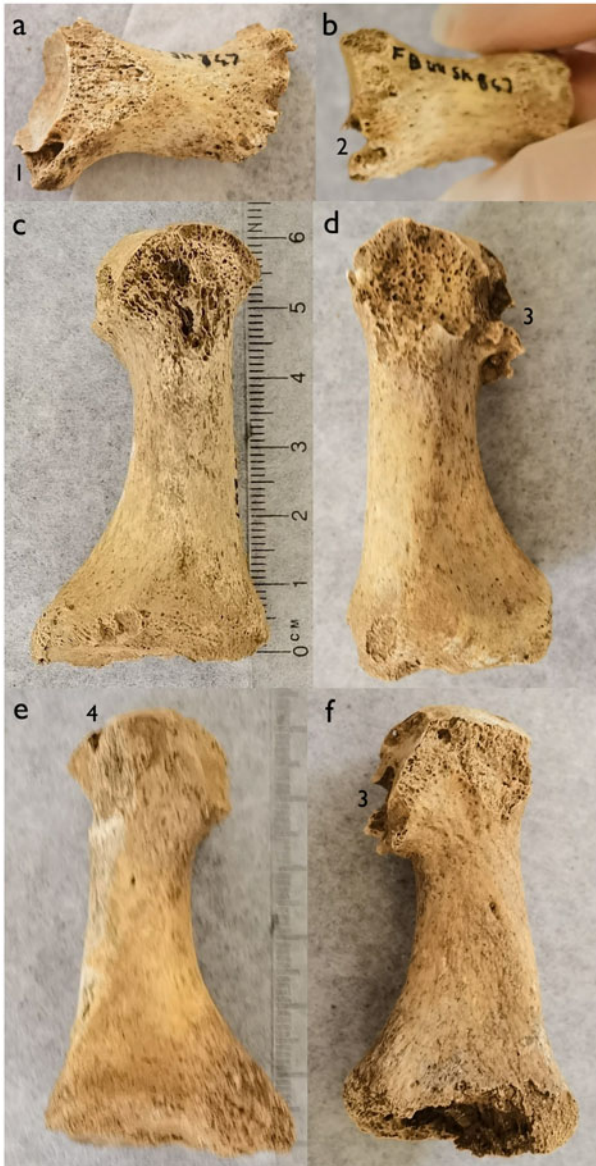

Fig. 11. First proximal phalanges and first metatarsals of individual sk847. (a) Left first proximal phalanx. (b) Right first proximal phalanx. (c) Left first metatarsal (top view). (d) Right first metatarsal (top view). (e) Left first metatarsal (bottom view). (f) Right first metatarsal (bottom view). Features mentioned in the text discussing the feet are numbered as follows: 1. Erosive lesion on left first proximal phalanx; 2. Erosive lesion on right first proximal phalanx; 3. Erosive lesion on right first metatarsal; 4. Possible erosive lesion on left first metatarsal. (Photos: H. Zhao; montage: A. Wilson.)

resulted from infection. Following these infections, secondary chronic changes are evident, including chronic osteomyelitis in the left elbow and enthesophytes in the right ulna and radius.

The systemic and bilateral nature of the joint afflictions across the body from elbows to feet makes the interpretation of the pathologies exhibited by individual sk847 challenging, as a few known diseases affect the joints in such a manner. Consequently, differential diagnosis is crucial to ascertain the most plausible explanation for these pathologies (Table 2).

The hypothesis that trauma could account for the osteomyelitic changes observed in the left elbow joint of individual sk847 is now considered unlikely. The simultaneous occurrence of severe infections in both elbows and both feet without any accompanying fractures diminishes the plausibility of trauma-induced pathology. The lesions evident on individual sk847, including bilateral (though not symmetrical) lytic lesions on both elbows, more aptly correspond with typical smallpox sequelae, offering a comprehensive explanation for the observed abnormalities across the elbows and feet.

Potential alternative diagnoses include tuberculosis, leprosy, treponematoses (syphilis, yaws, bejel, and pinta), rheumatoid arthritis, mycosis, degenerative arthritis, and septic arthritis (Table 2).⁵³ Tuberculosis, mycosis, and septic arthritis represent infections that

⁵³ Khurana et al. 2019, 814; Crawford et al. 2024, 73; Lefort and Bennike 2007, 342.

Table 2.
Differential diagnosis of observed pathologies.

<i>Possible diseases</i>	<i>Causes</i>	<i>Major characteristics</i>	<i>Location</i>	<i>References</i>
Osteomyelitis variolosa	Smallpox (variola) virus; acute infection	Vary greatly. Early manifestations: nonsuppurative osteomyelitis with necrosis, suppurative (pus-producing) arthritis as a result of a secondary infection, and multifocal nonsuppurative arthritis. Late manifestations: ankylosis, dislocation, subluxation, shortening and deformity of long and short tubular bones, flared metaphyses and precocious osteoarthritis.	Bilaterality a key feature, 80% including elbows. May also affect wrists, hands, feet, ankles, knees etc., with the axial bones rarely involved.	Cockshott and MacGregor 1958; Cockshott and MacGregor 1959; Davidson and Palmer 1963; Tang et al. 2021; Crawford et al. 2024
Treponematosi	Various species of Treponema or their distinct variants; chronic infection	Bilateral abnormal bending (as in yaws and bejel) and nongummatous/ gummatous periostitis (a soft, non-cancerous growth).	Predominantly the cranium, tibiae and fibulae; can affect other bones.	Ortner 2003; Lefort and Bennike 2007; Walker et al. 2015; Salmon 2022; Oumarou Hama et al. 2023
Leprosy	Mycobacterium leprae or Mycobacterium lepromatosis; chronic infection	Severe destructive remodeling, reduced diaphyses, periostitis, bone porosity, tooth loss, enlargement of nasal aperture, nasal structure resorption.	Primarily affects facial bones, including nasal spine and alveolar processes.	Møller-Christensen 1961; Møller-Christensen 1978; Andersen and Manchester 1992; Roberts and Buikstra 2019
Tuberculosis	Mycobacterium tuberculosis complex; chronic infection	Resorptive lesions including joint surface erosion, central sequestrum formation, endosteal destruction, minimal periosteal bone formation.	Multifocal involvement is very rare and with tightly clustered foci, affecting joints including the elbow but not recorded in feet. Elbow-specific changes: deeper excavation of the ulna's trochlear notch, elongation of the coronoid process.	Murray and Jacobson 1977; Aufderheide et al. 1998; Ortner 2003; Pigrau-Serrallach and Rodríguez-Pardo 2013; Roberts and Buikstra 2019

Rheumatoid arthritis	Auto-immune disorder	Inflammation and the progressive destruction of joint cartilage, typically manifesting in multiple and symmetrical joint involvement.	Typically starts in small joints like phalanges and wrists, often leading to eburnation and ankylosis.	Ortner 2003; Lefort and Bennike 2007
Mycosis	Fungal infection; rarely seen	Lytic lesions and porous reactive bone formation.	Predominantly affects the axial skeleton; not documented in the tali and calcanei.	Ortner 2003
Bony sequelae of trauma	Traumatic injury to bone or joint	Complications include infection, tissue necrosis, loss of innervation, inadequate fracture healing, bone deformity, traumatic arthritis, joint fusion, and traumatic myositis ossifications.	Can occur anywhere.	Redfern and Roberts 2019
Degenerative arthritis	Primary: biomechanical stress, aging; Secondary: trauma, other diseases	Eburnation, marginal osteophytes, new bone on joint surface, pitting, altered joint contour.	Not very common in elbows; when occurs, mostly affects radio-humeral joint. Other joints affected vary by cause and individual history; in foot, first metatarso-phalangeal joint most commonly involved. Bilateral occurrences common.	Waldron 2019
Septic arthritis	Bacterial infection entering via bloodstream, adjacent tissues, or direct introduction; acute infection	Acute cases cannot be detected in osteology. Chronic cases may show bony ankylosis, reactive bone formation, and hypervascularity.	Asymmetrical involvement common. Multifocal cases (n > 3) rare, except for gonococcal arthritis, which tends to be multiarticular. Gonococcal arthritis frequently affects the dorsum of hand and wrist, ankles.	Craig et al. 2003; Roberts 2019

typically exhibit non-systemic characteristics. Tuberculosis manifests osteologically primarily through extensive bone destruction, as opposed to the bone growth or deformation observed in the case under examination. While mycosis and septic arthritis exhibit certain similarities with the presented case, their pathologies are not congruent with simultaneous afflictions of both the elbow and the feet.

Conversely, diseases such as treponematosi s, leprosy, and rheumatoid arthritis are more frequently associated with the involvement of multiple joints. None of these conditions, however, can adequately account for the lesions observed in our case. Both treponematosi s and leprosy typically commence with the cranium or facial bones, exhibiting destructive lesions such as caries sicca in treponematosi s or extensive bone remodeling in leprosy. The sole pathology in the skull observed in our case is the dense sclerosis in the right maxillary sinus, which does not correspond with the typical manifestations of treponematosi s or leprosy. Rheumatoid arthritis predominantly affects smaller joints such as those in the fingers, characterized by greater destruction and eburnation of the articulating surfaces rather than bone proliferation. Additionally, as an autoimmune disorder, rheumatoid arthritis fails to account for the infectious markers (periostiti s) noted on the elbows.

Some traits possibly suggestive of degenerative joint disease are present in specific regions of the right elbow. These must be distinguished, however, from changes observed along the entirety of the affected area. The lesions extending along the shafts of the bones, distinct from the joint surfaces where degenerative changes typically manifest, cannot be reconciled with any known patterns of degenerative joint disease. Such extensive periostiti s across all three bones, humerus, radius, and ulna, predominantly indicates an infectious etiology rather than degenerative alterations. Moreover, the extensive periostiti s on all three bones is suggestive of infection, not degenerative changes.

Considering the locations of the lesions and their skeletal representations, osteomyelitis variolosa appears to be the most fitting diagnosis for all observed pathologies. The bilateral involvement of both elbows, including all three arm bones (humerus, radius, and ulna) with initial prominence in the proximal radius and ulna, aligns with known patterns of osteomyelitis variolosa.⁵⁴ Ankles and feet, which are also commonly affected sites, account for 18% of the diagnosed patients in the 19th–early 20th c.,⁵⁵ or 50% in clinical reports in the 21st c.⁵⁶ The distribution of lesions in cases of modern smallpox thus correlates with the lesions observed on the individual studied.

Given the rarity of osteomyelitis variolosa in both archaeological findings and modern clinical practice, it is important to compare the lesions of individual sk847 with other identified cases in the modern clinical literature to ensure the accuracy of the diagnosis.

Identification of osteomyelitis variolosa and lesion comparison

During 20th-c. smallpox epidemics, approximately 0.25–0.5% of all patients and 2–5% of affected children exhibited osteoarticular manifestations.⁵⁷ This suggests that osteomyelitis variolosa developed during the childhood of the individual in question. The majority

⁵⁴ Crawford et al. 2024, 72.

⁵⁵ Cockshott and MacGregor 1959, 57.

⁵⁶ Tang et al. 2021, 6.

⁵⁷ Cockshott and MacGregor 1958, 377; Cockshott and MacGregor 1959; Khurana et al. 2019.

of archaeologically identified cases of osteomyelitis variolosa in Table 1 involve children or juveniles, with only two older adults noted (Table 1, nos. 4 and 5), and just one report (Table 1, no. 4) providing photographic evidence of affected elbows. This underscores the importance of using modern medical records to enhance the diagnostic accuracy in archaeological cases where osteomyelitis variolosa is suspected in adult skeletons.

In contrast to juveniles and younger adults, older adults who have survived a smallpox attack often present with skeletal deformities and joint pain (arthralgia), attributable to superimposed degenerative changes.⁵⁸ Modern clinical reports corroborate this pattern; many patients experience severe pain and increasingly restricted movement in the joints affected by osteomyelitis variolosa decades after the initial infection. A notable case reported by Tang et al. involved a 70-year-old woman who, although infected in her childhood, began experiencing exacerbated limited movement and pain in her knees only a year prior to the report.⁵⁹ Another diagnosis of osteomyelitis variolosa also concerned a woman who was 70 years old at the time of presentation, who had experienced pain in her right knee for five years.⁶⁰ A case reported by Purandarnath and Douraiswami describes a 65-year-old woman who had endured pain and stiffness in both elbows and in joints of her feet for 30 years.⁶¹ All three women had had smallpox in childhood. These clinical observations underscore the fact that while osteomyelitis variolosa is initially an acute infection of the bone, it continues to evolve into secondary arthritis and degenerative changes over decades. This progression is also evident in the case under discussion, where both infection and degenerative changes coexist. To refine the diagnosis of osteomyelitis variolosa, a comparative analysis with similarly diagnosed older adults is recommended, enhancing the accuracy of differential diagnoses and underscoring the chronic nature of the disease's impact on skeletal health.

Comparative analysis of elbow and ankle lesions, as depicted in Figs. 12 and 13, provides further insight. Notably, bilateral changes in osteomyelitis variolosa do not always manifest symmetrically, and asymmetrical changes in the elbows have been documented in several cases identified in the 21st c. (Fig. 12).⁶² This observation is particularly significant given that only 11 cases of osteomyelitis variolosa have been reported in the 21st c.⁶³ This asymmetry aligns with the unpredictable nature of infectious diseases; for example, periostitis caused by bacterial infection may vary in severity across affected sites in the body.⁶⁴ Historical data support this observation of asymmetry. According to Cockshott and MacGregor,⁶⁵ among 124 cases, 97 exhibited elbow involvement, with 19 exclusively unilateral, indicating a significant probability (approximately 20%) of asymmetrical manifestations among those affected. This variability in lesion symmetry is also evidenced by the skeletal findings illustrated in Figure 12.

⁵⁸ Margolis et al. 1978, 262.

⁵⁹ Tang et al. 2021, 2.

⁶⁰ Douraiswami 2011.

⁶¹ Purandarnath and Douraiswami 2011, 124.

⁶² Arora et al. 2008; Douraiswami 2011; Khurana et al. 2019.

⁶³ For a summary of reported cases, see Tang et al. 2021, 5.

⁶⁴ Roberts 2019, 295.

⁶⁵ Cockshott and MacGregor 1958.

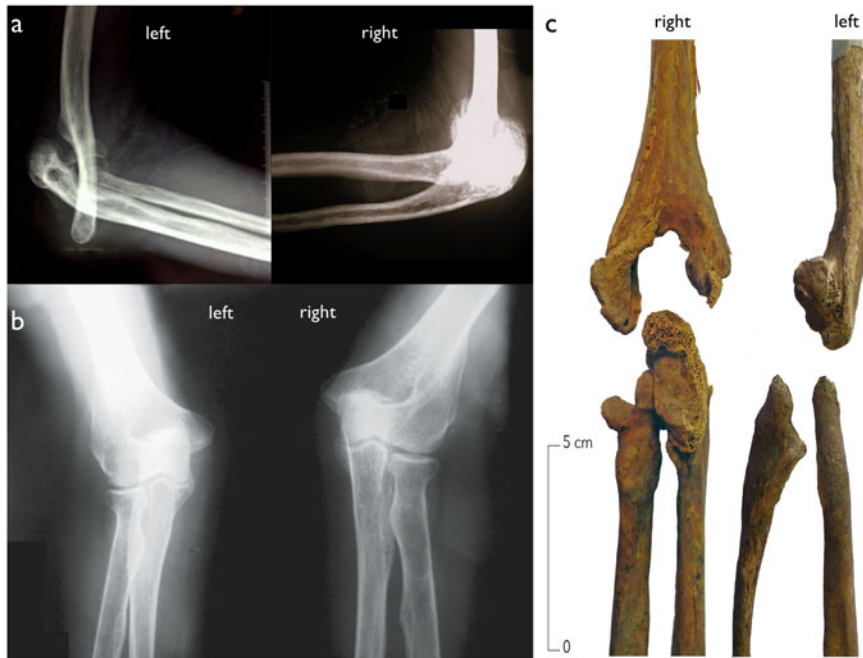


Fig. 12. Comparison of elbows affected bilaterally by osteomyelitis variolosa. (a) Radiograph of elbows of a 56-year-old man (Khurana et al. 2019, figs. 3 and 4, details). (b) Radiograph of elbows of a 65-year-old woman (Purandarnath and Douraiswami 2011, fig. 4). (c) Photograph of the elbow bones of a medieval or early modern skeleton identified as of a woman aged between 20 and 49, from the convent of the Jacobins at Rennes, France (Colleter 2021, fig. 2, detail, courtesy of R. Colleter).

Margolis et al. and Tang et al. have concluded that the pathological changes in residual osteoarticular lesions of smallpox are non-specific and that no diagnostic radiographic image exists for osteomyelitis variolosa.⁶⁶ This variability in pathological representation should therefore be considered a characteristic trait of osteomyelitis variolosa.

The comparative analysis of the elbow lesions in individual sk847 reveals that the right elbow aligns closely with the radiograph of a diagnosed case of osteomyelitis variolosa shown in Figure 12b, where the pathological changes on the elbows are nonsuppurative. The left elbow of sk847 is more severely destroyed than the examples in Figure 12, as a result of suppurative arthritis. It is widely recognized that smallpox can lead to pyogenic, or suppurative, arthritis, although this complication has become less frequent after the 20th c.⁶⁷ Given these observations, we can confidently assert that the lesions on both elbows in individual sk847 may be attributed to smallpox and its chronic sequelae.

Regarding the foot lesions, there is a close degree of congruence with known cases (Figs. 9, 10, and 13). Distortions of the calcaneus, such as flattening and shortening, are commonly reported symptoms in adults with osteomyelitis variolosa due to long-term changes in mobility and weight-bearing.⁶⁸ The case of individual sk847 exhibits bilateral shortening

⁶⁶ Margolis et al. 1978, 262; Tang et al. 2021, 6.

⁶⁷ Cockshott and MacGregor 1958, 375; Margolis et al. 1978, 262; Resnick and Niwayama 1995, 2529.

⁶⁸ Arora et al. 2008, 358; Nema et al. 2012, 3426.

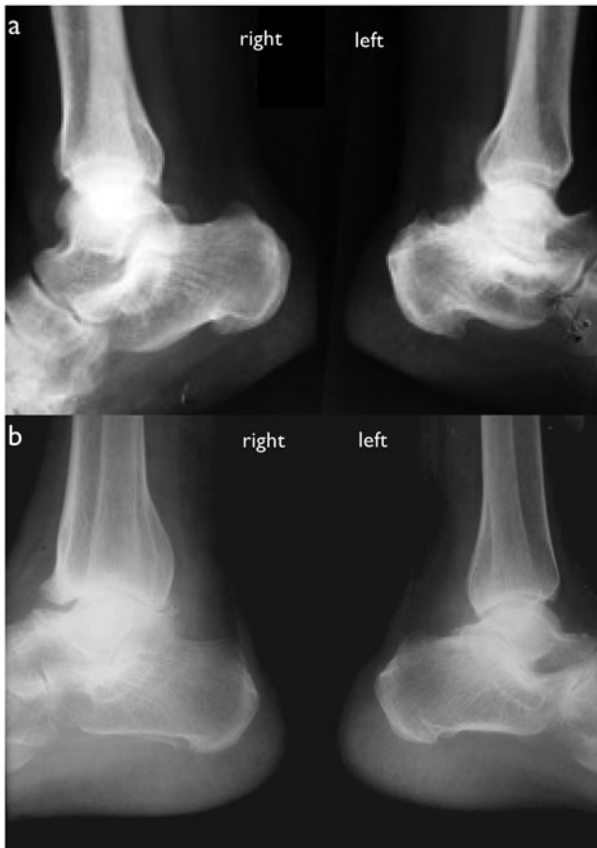

Fig. 13. Comparison of ankles affected bilaterally by osteomyelitis variolosa. (a) Radiograph of feet of a 64-year-old man, with the left foot more severely affected, showing shortening of the left calcaneum (Arora et al. 2008). (b) Radiograph of feet of a 65-year-old woman (Purandarnath and Douraiswami 2011, figs. 2 and 3, details).

of the calcanei, resembling the findings reported in Arora et al., although in their report the alteration was unilateral.⁶⁹ Additionally, although not fully ankylosed, the tarsal bones, first metatarsals, and first proximal phalanges in individual sk847 show severe deformities. These findings closely parallel those reported in Nema et al.⁷⁰

The dense sclerosis observed in the right maxillary sinus of sk847, which Geber suggested was caused by maxillary sinusitis,⁷¹ may also perhaps be attributable to smallpox, although other explanations are possible too. Cockshott and MacGregor described a case involving an 8-year-old girl where “the lateral wall and the floor of the right antrum showed much bony thickening in the radiograph.”⁷² Although no radiograph was published, the description closely aligns with the pathology observed in sk847, which exhibits similar dense sclerosis across the entire floor and lateral wall of the right maxillary sinus (also called “maxillary antrum”). In the absence of preserved soft tissue,

however, we cannot determine whether this lesion was a result of smallpox or an independent episode of maxillary sinusitis.

The collective findings from the differential diagnosis and comparison with known cases strongly support the hypothesis that osteomyelitis variolosa is the most probable cause for the observed lesions on individual sk847's elbows and feet. While it is possible to find separate explanations for each individual lesion, the holistic explanation provided by osteomyelitis variolosa, encompassing all observed symptoms, presents the most coherent and likely diagnosis.

The corollary is that individual sk847 was a survivor of an earlier smallpox infection. This person died in the late 3rd or the 4th c. CE at the age of between 40 and 50, having

⁶⁹ Arora et al. 2008.

⁷⁰ Nema et al. 2012.

⁷¹ Geber 2017b, 26.

⁷² Cockshott and MacGregor 1959, 60 and fig. 9.

contracted smallpox almost certainly in childhood, some 25–50 years previously. The bone involvement began acutely as suppurative osteomyelitis in the tubular bones,⁷³ notably leading to the destruction of the left elbow through the formation of pus. The initial alteration in joint structures probably commenced at the elbows, with subsequent involvement of the feet and maxilla occurring within 1–2 days.⁷⁴ The progression to nonsuppurative arthritis, occurring within 1–4 weeks of the onset, then severely compromised both bone growth and joint function at these sites.⁷⁵ Throughout this pathological progression, individual sk847 would have experienced significant pain and swelling around the affected joints, endured prolonged periods of low fever, and suffered from increasingly restricted joint mobility.⁷⁶ The left arm became virtually unusable, with loss of movement and the joint locked in a 90° angle; there would probably also have been some loss of movement and function in the right arm. Later, in adulthood, the individual experienced chronic complications surrounding all the previously infected joints. The acute infection in the left elbow transitioned to a chronic state, marked by cycles of new bone formation and repair during periods when the individual was stronger and healthier, and exacerbations of the infection during times of weakened health. Concurrently, degenerative changes intensified in the right elbow and feet, exacerbated by the underlying deformities. The damage to both feet, including heels and toes, caused deformities and the individual would certainly have had difficulty walking. The immobility of his flexed left elbow meant that when he was laid out for burial in his coffin, the left forearm had to be laid over his abdomen.

Genetic evolution of smallpox and historical implications

Genetic evolution of smallpox

Osteomyelitis variolosa, a specific skeletal manifestation of smallpox, is directly linked to infection by the variola virus (VARV), the causative agent of smallpox. The antiquity of smallpox as a human-specific disease is a matter of current debate, and the Cirencester skeleton bears on this debate.

Variola virus is one of several related poxviridae which have evolved from a common ancestor, a more generalized orthopoxvirus, to target specific species: its closest relatives are camelpox, affecting camels, and taterapox, affecting gerbils. Cowpox, monkeypox, and vaccinia virus affect several host species with different degrees of severity.⁷⁷ There is no agreement about when an ancestral strain of VARV diverged from a more general orthopoxvirus, capable of infecting various species, to become a human-specific variola virus causing smallpox.

Ancient DNA studies have identified two extinct clades of variola virus. One is known as modern VARV (mVARV), which can be traced back at least to a 17th-c. CE ancestor of strains of the modern smallpox declared eradicated in 1980. The other clade is known as ancient VARV (aVARV), and has been found in Viking-age or earlier burials dating between the 7th and 11th c. CE, but seems to have become extinct thereafter; it is a sister clade, not a

⁷³ Resnick and Niwayama 1995, 2529.

⁷⁴ Cockshott and MacGregor 1958, 378.

⁷⁵ Resnick and Niwayama 1995, 2529.

⁷⁶ Cockshott and MacGregor 1958, 378; Resnick and Niwayama 1995, 2529.

⁷⁷ Hendrickson et al. 2010; Mühlemann et al. 2020.

direct ancestor, of mVARV.⁷⁸ The modern smallpox of the mVARV clade that was eradicated in the 1970s existed in two strains – variola major, with case fatality rates of 20–30%, and variola minor or alastrim, with far lower case fatality rates, of 1–5%. The aVARV clade is more distantly related, and its symptoms and case fatality rates are unknown, leading Timothy Newfield et al. to deny that it was smallpox at all, and to argue that we only know that the mVARV clade is capable of instigating smallpox.⁷⁹ As Monica Green has put it, such “reductive nominalism” is unhelpful, and there are actually indications that the symptomatology of variola virus in the Middle Ages shared a number of key elements with modern smallpox. These indications include a discussion of *judarī* (the Arabic word for smallpox used up to the 1970s) by the Persian medical author Rhazes, writing in 10th-c. Baghdad, which mentions excruciating pain in the limbs (from the bone infection), and facial scarring caused by *judarī* mentioned in 11th-c. Arabic poetry from Sicily.⁸⁰ Given the trading connections between Viking Scandinavia and the medieval Arab world, the medieval smallpox these sources describe could well be closely related to the aVARV in Viking burials. Medieval skeletons exhibiting osteomyelitis variolosa, from 10th-c. Cambridgeshire and 11th-c. France (Table 1, nos. 1 and 2), also confirm that a version of VARV circulating at the time caused pathological sequelae like those of modern smallpox.

The interpretation of the VARV genetic data is contentious. Three separate issues are at stake, two chronological and one of disease identification. The first is that widely varying dates have been calculated by different research groups for the time to most recent common ancestor. These disparities were apparently caused by variations in methods of molecular clock calculation, or the parameters and modelling assumptions used. The most recent common ancestor of the ancient and modern VARV clades was calculated by Barbara Mühlemann et al. in 2020 to have existed between 2,200 and 1,400 years ago (at 95% confidence), meaning that aVARV and mVARV diverged from each other after that; that is, sometime between around 200 BCE and 600 CE.⁸¹ A more recent study, by Igor Babkin et al. in 2022, narrows that range somewhat to between ca. 160 CE and 500 CE.⁸²

Babkin et al. calculated that the emergence of VARV from a generalized orthopoxvirus occurred not very long before that, between 13 and 494 CE (95% highest priority density interval).⁸³ In 2023, however, Diego Forni et al. calculated a radically different and much older set of results. They factored into their molecular clock analyses a new model that posits a power-law decay in the rate of change over time, based on observations that the longer the period of observation, the slower the apparent overall rate of change in viral evolution – the so-called time-dependent rate phenomenon.⁸⁴ Forni et al. calculated that the VARV lineage diverged from an orthopoxvirus between about 8,000 and 4,000 years ago, and that aVARV and mVARV diverged from a common ancestor between 3,790 and

⁷⁸ Mühlemann et al. 2020, 3; Forni et al. 2023, 5.

⁷⁹ Newfield et al. 2022.

⁸⁰ Green 2024, 355–56, citing the Sicilian poet Muḥammad ibn al-Ḥasan ibn al-Ṭūbī (d. after 1060).

⁸¹ Mühlemann et al. 2020, 3; Forni et al. 2023.

⁸² Babkin et al. 2022, 6 (1,505 to 1,862 years ago, 95% HPD).

⁸³ Babkin et al. 2022, 10.

⁸⁴ Ghafari et al. 2021.

4,351 years ago (95% highest priority density interval), that is, 2329–1768 BCE,⁸⁵ suggesting the existence of human-infecting smallpox after this period. All three of these different studies use radiocarbon dates that fail to account for the marine reservoir effect, which makes radiocarbon dates appear older than they should be. The earliest date for an archaeological aVARV specimen is from a Sámi burial at Lødingen in Norway, radiocarbon dated to between 603 and 653 cal. CE at two standard deviations (95.4% confidence), but uncorrected for marine reservoir effects, which may mean that the burial could be several hundred years younger.⁸⁶

The studies of Mühlemann et al. and Babkin et al. allow for the emergence of smallpox in the Roman era (after 200 BCE or after 160 CE, on their different calculations), while Forni et al.'s study requires that it emerged well before the Roman period. Distinctive skin lesions, which may possibly be from smallpox, have been observed on Egyptian mummies dating from between 1580 BCE and 1100 BCE,⁸⁷ and this would be consistent with Forni et al.'s dating, but no aDNA studies have been undertaken on these mummies, and the suggestion that they might exhibit smallpox remains speculative. But Forni et al.'s method does not account for the likelihood that during a pandemic, or even during large epidemics, the mutation rate may increase because the viral population has grown by orders of magnitude, and so there is a statistical likelihood of more mutations. (We have seen this recently with the very rapid mutation rates of Covid-19 between 2020 and 2022.) If the early evolution of smallpox from a generalized orthopox virus infecting multiple host species to a human-obligate pathogen involved a zoonosis and subsequent pandemic as a new disease rampaged through immunologically naïve populations,⁸⁸ we might expect a very high initial rate of change, rather than a consistent power-law decay rate. The effect would be that the time to most recent common ancestor might be not nearly as long as Forni et al. estimate.

The second problem is the tendency of some authors to focus on the midpoint of the date range calculated for the emergence of a particular clade and to draw over-precise conclusions from that. Thus Mühlemann et al. reported their calculation of the time to most recent common ancestor for aVARV and mVARV as “1.7 thousand years ago (kya) [95% highest priority density interval (HPD95): 2.2 to 1.4 kya]”; this was interpreted by Newfield et al. as implying that a VARV strain capable of instigating smallpox did not materialize before the 4th c. CE.⁸⁹ Clearly, that is not a legitimate conclusion. Rather, we should be dealing with the 95% probability that the event could have occurred *at any time in the range calculated*, between ca. 200 BCE and 600 CE – or, according to Babkin et al.'s calculation, between ca. 160 CE and 500 CE.⁹⁰

⁸⁵ Forni et al. 2023, 5 (calculating from a present of 2022, as they evidently did).

⁸⁶ Mühlemann et al. 2020, Table 1, sample VK388, and Supplementary Materials, p. 5.

⁸⁷ McCollum et al. 2014, 180; Thèves et al. 2016, 5; Mühlemann et al. 2020, 1. These include the mummy of Ramesses V, who died in 1145 BCE.

⁸⁸ Cf. Green 2024, 353–54.

⁸⁹ Mühlemann et al. 2020; Newfield et al. 2022, 905. Cf. Forni et al. 2023, 5, where Table 2 gives only median dates rather than the full range.

⁹⁰ Babkin et al. 2022, 6. A subsidiary source of confusion, unhelpful when dealing with historical reconstruction, is the practice of calculating ages as so many “years ago,” without being clear on what year is being used as the present to calculate back from – 1950, as with radiocarbon dating? 2000, as a round number? The date of composition of the article (which is not always the same as the date of publication)?

Thirdly, there is the problem of the relationship between the different strains identified genomically, and the nature of the disease, in terms of its symptoms, pathology, infectivity, case fatality rates, etc. As noted above, some have denied that aVARV should be considered smallpox at all and have suggested we abandon the use of the term “smallpox” altogether when talking about the ancient world.⁹¹ Until we can equate particular genes with specific disease effects, the symptoms and epidemiology of medieval and earlier smallpox must remain shadowy; but the cases of osteomyelitis variolosa identified in medieval skeletons (Table 1) *do* show the existence of a pre-modern disease that caused the same long-term sequelae as smallpox. The evidence of the Persian medical writer Rhazes and Sicilian Arabic poetry mentioned above also show that medieval smallpox shared features with modern smallpox. The diagnosis of osteomyelitis variolosa in individual sk847 from Cirencester is important in this context because it shows the presence of a disease active in Roman Britain in the 3rd or 4th c. CE that also caused the same osteological sequelae as smallpox. Because no aDNA analysis has been performed on the Roman or Viking-age skeletons with osteomyelitis variolosa (and in any case the virus might not persist in the bones of someone who had survived a smallpox infection), we do not know whether these cases were caused by the aVARV or the mVARV clade; either is possible, as we have seen from the discussion above of the date after which they split from their most recent common ancestor. The Cirencester skeleton represents the earliest evidence yet identified in Europe of smallpox, or of a disease so like smallpox that it was capable of causing the same sequelae.

Smallpox and the Antonine Plague

The question of the antiquity of smallpox is bound up with the current debate over the identification of the Antonine Plague of the later 2nd c. CE. The symptoms of the plague described by the ancient physician Galen have as their most distinguishing feature a rash or exanthema, which was black from putrefied blood within the blisters; this was accompanied by diarrhea, often with black excrement (resulting from internal bleeding), stomach upset and sometimes vomiting, a sensation of fever internally but little outward sign of it, and fetid breath.⁹² The possible identification of the disease as smallpox was first suggested in 1845, and argued for strongly by Littman and Littman in 1973.⁹³ By the time of a conference on the impact of the Antonine Plague in 2012, the retrospective diagnosis of smallpox had become widely accepted and was being used to try to understand the demographic impact, based on the case fatality rates of modern smallpox.⁹⁴ Already in 2005, however, Danielle Gourevitch had pointed out that Galen does not mention the permanent scarring caused by smallpox, and had suggested, therefore, that the Antonine Plague was one of the poxviridae, an ancestor of smallpox, but sufficiently different not to leave scarring.⁹⁵ This argument was developed by Rebecca Flemming, and has recently been accepted also by Colin Elliott who, in his book on the Antonine Plague, rejects the

⁹¹ Newfield et al. 2022.

⁹² Gal. *Methodus medendi* 5.12; Gal. *De atrabile*, ed. Kühn vol. 5, 115 = *Corp. Med. Graec.*, V, 4, 1, 1, p. 76; Gal. *De praesagitione ex pulsibus* 3.4, ed. Kühn vol. 9, 357. See Littman and Littman 1973, 246–52.

⁹³ Haeser 1845, 251; Haeser 1882, 24–33; Littman and Littman 1973.

⁹⁴ See many of the papers in Lo Cascio 2012, and especially Harris 2012; Livi Bacci 2012; Zelener 2012. On the mortality rate, see also Littman and Littman 1973, 252–55.

⁹⁵ Gourevitch 2005, 65.

diagnosis of smallpox.⁹⁶ The argument from silence, however, is not strong: we are at the mercy both of the haphazard survival of ancient sources (and there are many fewer from the late 2nd c., for example, than from the 1st c. CE), and of the conventions of their genres. Even ancient medical writings often do not mention the kinds of things a modern medical writer might be interested in, and as Littman and Littman already pointed out, the scarring often did not appear until some days or weeks after the disease had passed, while Galen's focus was on the disease in its critical stages.⁹⁷ Moreover, Galen was not trying to write a complete symptomatology of the Antonine Plague; he mentions the plague in passing when one or more of its symptoms are relevant to other phenomena he is discussing. Since, if scarring did occur, he would have been unable to cure or prevent it, he may have been disinclined to mention it at all. Little can be concluded from the absence of references to scarring in either Galen's work or other literature. Similarly, the lack of pock-marked portrait statues could be explained easily by the idealizing conventions of Roman art. A stronger challenge to the straightforward identification as smallpox seemed to be mounted by the aDNA research discussed above showing that a number of aVARV strains of variola virus were circulating in the Middle Ages that differed in several respects from modern VARV. Doubts about the congruence of ancient and modern variola variants have even led some to call for abandoning the term "smallpox" in reference to diseases of antiquity.⁹⁸

Certainly, we should not uncritically assume that the symptoms, transmission rates, case fatality rates, etc. of ancient smallpox or an ancestor of modern smallpox were necessarily the same as for modern smallpox – not least because modern smallpox itself could have very variable case fatality rates, depending on whether the variola major or the alastrim strains were involved. Several points, however, stand. First, even if the aVARV clade produced symptoms substantially different from modern smallpox (and we do not know this for certain), molecular clock calculations of the time to most recent common ancestor of the aVARV and mVARV clades put the divergence of those clades at some time between the third millennium BCE and 600 CE, depending on whose calculations one believes. Even on the later ranges calculated by different teams, 200 BCE–600 CE, or 160 CE–500 CE, an mVARV clade could have appeared as a result of this divergence before or around the time of the Antonine Plague in the 160s CE. Second, the common ancestor of aVARV and mVARV had already diverged from a more generalized orthopoxvirus to become a human-specific virus at some date before that, and certainly either by or during the Roman Imperial period on anybody's calculation. Third, Galen describes a disease with such strong resemblances to smallpox that even if it was genetically somewhat different, it produced most of the same symptoms as modern smallpox. Fourth, archaeologically attested cases of osteomyelitis variolosa show the antiquity of a form of variola virus capable of causing the same osteological sequelae in survivors as did modern smallpox.

It is in this context that the skeletal remains of individual sk847 from Cirencester have a bearing on the argument. Although they date more than a century later than the Antonine Plague, they show that the variola virus had been introduced into the Roman world by the

⁹⁶ Flemming 2019, 233–34; Elliott 2024, 90–93, and 235 n. 90.

⁹⁷ Littman and Littman 1973, 251 n. 22.

⁹⁸ Newfield et al. 2022. *Contra* Green 2024, 353–54.

late 3rd or the 4th c. CE at the very latest, and probably before that. Indeed, it may well have become endemic by then; individual sk847 from Cirencester survived a childhood infection of smallpox, and this would be entirely consistent with endemic disease. The Antonine Plague, a devastating pandemic, with symptoms comparable to smallpox and a high mortality rate compatible with the first exposure of a naïve population to variola virus, is the obvious context for that original introduction of the disease into the Roman world, probably by troops returning from Lucius Verus's Parthian campaign in 165 or 166 CE. (The Plague of Cyprian is not a likely contender here; no account of its symptoms includes the characteristic exanthema of smallpox, and a viral hemorrhagic fever is more likely.⁹⁹) Those who had caught the disease and survived would have gained lifelong immunity to further infection, and the repeated waves of the Antonine Plague between the mid 160s and the 180s may reflect the behavior of the disease before enough people had gained immunity for it to become endemic, thereafter typically infecting mainly children who had not yet been exposed to it. The apparent disappearance of the Antonine Plague from our classical sources in the late 2nd c. may well reflect the fact that it became endemic. Periodic epidemics might also have occurred through reintroduction to regions where the disease had not manifested for a while and a non-immune population had grown up. As Monica Green points out, Gregory of Tours may describe smallpox in the 6th c. CE,¹⁰⁰ and there are various mentions either explicitly of smallpox or of a disease behaving very like smallpox from the 4th c. onwards in China,¹⁰¹ and from the 7th

⁹⁹ Harper 2015, 241–48.

¹⁰⁰ Gregory of Tours: see McCormick 2021, 55–60 for discussion and n. 87, pp. 55–56 for a list of passages in his works describing a disease with pustules in the 6th c., including permanent scarring on the face (*Vitae Patrum* 8.1; the event is before 558 CE), and an epidemic in 582 CE (*Historia Francorum* 6.14).

¹⁰¹ In particular, in the *Zhouhou Beijifang* (*Handbook of Prescriptions of Emergency Treatments*) by the Chinese physician Ge Hong (283–343 CE), revised and expanded by Tao Hongjing in 500 CE. Book 2 ch. 13, “Treatments of headaches and high fevers,” (sections 81–82) refers to an outbreak in the 4th c. (with an addition by Tao Hongjing referring also to a 4th-c. or 5th-c. epidemic): “[81] There was an outbreak of a plague. It caused poxes to erupt on the face and head, which then spread to the rest of the body. They spread across the body extremely fast. Their shapes resembled severe acne, all containing pustules. They would reappear after breaking open. If not treated immediately, those seriously infected would die. After being cured, the sores would leave purple and black scars, which would take years to fade. This condition was caused by poisonous *Qi* [vital energy] residing within the body. Others say that in the fourth year of Yonghui, the pox disease spread from west to east, and eventually appeared throughout the country. Boiled Kuicai [*Malva verticillata* var. *crispa*], along with mashed garlic, can cure the disease. [82] People should take the medicine as soon as they become infected. It is more effective when they eat less food. This disease was first introduced in the year of Jianwu, after defeating the enemy at Nanyang, and it is still called ‘Lu Chuang’ (Pox of the enemy)” (translation by Haoyue Zhao). For the problems of the dates referred to in the text, see Needham and Lu 2000, 124–27. “The fourth year of Yonghui” comes from Tao Hongjing’s additions but must be a later scribal error for either “the fourth year of Yongjia” (310 CE) or “the fourth year of Yuanhui” (476 CE). The phrase *Jianwu zhong* that Needham and Lu translate as “the mid Jianwu” can also simply mean “the time of Jianwu”; on historical grounds, it is most likely to refer to 317/318 CE, when there were campaigns around Nanyang in the northern provinces, rather than to the other Jianwu eras of 25–56 CE, when there were no significant rebellions in the north under the Han dynasty, 304 CE, when the Jin dynasty still maintained control over the north, or 335–348 CE, an era named after a northern empire established by a nomadic tribe, since Ge Hong was residing in the southern part of China, under the jurisdiction of the

c. onwards in the Eastern Mediterranean and western Asia. These suggest a basic continuity in the main outlines of the symptoms of the disease, even if there were doubtless a number of genetic variations of different strains.¹⁰²

If we wished instead to believe that the Antonine Plague was not caused by variola virus, we would need to assume not only that it was a different disease, which may have since become extinct, but also that the variola virus that caused the osteomyelitis variolosa in the Cirencester skeleton arrived in the Roman world unheralded in our surviving sources before the end of the 3rd c. That is not entirely impossible, and certainty cannot be achieved without ancient DNA analyses of victims of the Antonine Plague, but Occam's razor would argue against it. Meanwhile, we hope that the identification of osteomyelitis variolosa presented here may assist recognition of other cases in the archaeological record.

Acknowledgments: We are deeply grateful to Caroline Morris from the Corinium Museum and Elizabeth Selby from the Dorset Museum for their gracious hospitality and continuous assistance during Haoyue Zhao's visits to their collections. Their generosity in allowing access to their resources and permission to use photographs from their collections enabled and significantly enriched this research. We thank Wadham College, Oxford, for a travel grant to Haoyue Zhao that facilitated these visits. We also thank Dr Qiang Shen (MD), Dr Tong Zhao (MD), and Dr Mengjun Wang (MD, PhD), consultant radiologists at Beijing Shijitan Hospital, Capital Medical University, for their advice. Comments by the journal's two anonymous reviewers have helped us strengthen our argument, and we are grateful to them, and also to Dr Rosie Crawford for comments and corrections.

Competing interests: The author(s) declare none.

References

- Andersen, Johs G., and Keith Manchester. 1992. "The rhinomaxillary syndrome in leprosy: A clinical, radiological and palaeopathological study." *International Journal of Osteoarchaeology* 2, no. 2: 121–29.
- Arora, Anil, A. Agarwal, and Santhu Kumar. 2008. "Osteomyelitis variolosa: A report of two cases." *Journal of Orthopaedic Surgery* 16, no. 3: 355–58.
- Aufderheide, Arthur C., Conrado Rodriguez-Martin, and Odin Langsjoen. 1998. *The Cambridge Encyclopedia of Human Paleopathology*. Cambridge and New York: Cambridge University Press.
- Babkin, Igor V., Irina N. Babkina, and Nina V. Tikunova. 2022. "An update of orthopoxvirus molecular evolution." *Viruses* 14, no. 2: 388. <https://doi.org/10.3390/v14020388>.
- Cockshott, Peter, and Malcolm MacGregor. 1958. "Osteomyelitis variolosa." *The Quarterly Journal of Medicine* 27, no. 3: 369–87.
- Cockshott, Peter, and Malcolm MacGregor. 1959. "The natural history of osteomyelitis variolosa." *The Journal of the Faculty of Radiologists* 10, no. 2: 57–63.
- Colleter, Rozenn. 2021. "Archéologie du handicap et inégalités sociales au couvent des Jacobins de Rennes (xiiiè–xviiiè siècles)." *Les Nouvelles de l'archéologie* 165: 56–61.
- Coqueugniot, Hélène, Coralie Demangeot, David Peressinotto, and Olivier Dutour. 2022. "Microarchitectural and 3D analysis of a new paleopathological case of smallpox (Aubeterre-Sur-Dronne, Charente, 11th–19th centuries)." In *23rd Paleopathology Association European Meeting, Vilnius, Lithuania. Abstract Book*, 56. Vilnius: Vilnius University Press, 2022. <https://epublications.vu.lt/object/elaba:139500033/139500033.pdf>.
- Craig, Joseph G., Marnix Van Holsbeeck, and Magaly Alva. 2003. "Gonococcal arthritis of the shoulder and septic extensor tenosynovitis of the wrist: Sonographic appearances." *Journal of Ultrasound in Medicine* 22, no. 2: 221–24.

Eastern Jin Empire, which utilized different annual designations. In any case, the text shows that smallpox was known in China by the 340s at the latest.

¹⁰² Green 2018; Green 2024, 352–57.

A case of osteomyelitis variolosa from Roman Britain

- Crawford, Rosie R., Claire M. Hodson, and David Errickson. 2024. "Guidance for the identification of bony lesions related to smallpox." *International Journal of Paleopathology* 44: 65–77.
- Darton, Yves, Isabelle Richard, and Marie-Cécile Truc. 2013. "Osteomyelitis variolosa: A probable mediæval case combined with unilateral sacroiliitis." *International Journal of Paleopathology* 3, no. 4: 288–93.
- Davidson, James C., and P. E. S. Palmer. 1963. "Osteomyelitis variolosa." *The Journal of Bone and Joint Surgery. British Volume* 45, no. 4: 687–93.
- Douraiswami, Balaji. 2011. "Osteomyelitis variolosa: A case report." *Journal of Orthopaedic Surgery* 19, no. 1: 120–22.
- Drago, Lorenzo, Carlo L. Romanò, Ilaria Morelli, and Thani Benzakour. 2020. "Viral bone infection: A neglected disease?" *Microorganisms* 8, no. 6: 797. <https://doi.org/10.3390/microorganisms8060797>.
- Elliott, Colin P. 2024. *Pox Romana: The Plague That Shook the Roman World*. Turning Points in Ancient History. Princeton: Princeton University Press.
- Esposito, A., S. C. L. Souto, O. A. Catalano, A. S. Doria, P. B. S. Trigo, and D. Resnick. 2006. "Pattern of osteophytes and enthesophytes in the proximal ulna: An anatomic, paleopathologic, and radiologic study." *Skeletal Radiology* 35, no. 11: 847–56.
- Flemming, Rebecca. 2019. "Galen and the plague." In *Galen's Treatise Περὶ Ἀλυπίας (De indolentia) in Context*, ed. Caroline Petit, 219–44. Studies in Ancient Medicine 52. Leiden: Brill.
- Forni, Diego, Cristian Molteni, Rachele Cagliani, Mario Clerici, and Manuela Sironi. 2023. "Analysis of variola virus molecular evolution suggests an old origin of the virus consistent with historical records." *Microbial Genomics* 9, no. 1. <https://doi.org/10.1099/mgen.0.000932>.
- Geber, Jonny. 2017a. "Human remains." In *The Western Cemetery of Roman Cirencester. Excavations at the Former Bridges Garage, Tetbury Road, Cirencester, 2011–2015*, ed. Neil Holbrook, James Wright, E. R. McSloy, and Jonny Geber, 98–118. Cirencester Excavations 7. Cirencester: Cotswold Archaeology.
- Geber, Jonny. 2017b. "Osteological catalogue." In *The Western Cemetery of Roman Cirencester: Excavations at the Former Bridges Garage, Tetbury Road, Cirencester, 2011–2015*, ed. Neil Holbrook, James Wright, E. R. McSloy, and Jonny Geber. Cirencester Excavations 7. Online catalogue. <https://cotswoldarchaeology.co.uk/wp-content/uploads/2017/09/Cirencester-western-cemetery-osteological-online-catalogue.pdf>.
- Ghafari, Mahan, Peter Simmonds, Oliver G. Pybus, and Aris Katzourakis. 2021. "A mechanistic evolutionary model explains the time-dependent pattern of substitution rates in viruses." *Current Biology* 31, no. 21: 4689–96.e5.
- Gourevitch, Danielle. 2005. "The Galenic plague: A breakdown of the imperial pathocoenosis. Pathocoenosis and *longue durée*." *History and Philosophy of the Life Sciences* 27, no. 1: 57–69.
- Grauer, Anne L., and Charlotte A. Roberts. 2019. "Fungal, viral, multicelled parasitic, and protozoan infections." In *Ortner's Identification of Pathological Conditions in Human Skeletal Remains*, ed. Jane E. Buikstra, 441–78. London: Academic Press.
- Green, Monica H. 2018. "Climate and disease in medieval Eurasia." In *Oxford Research Encyclopedia of Asian History*, ed. David Ludden. New York: Oxford University Press.
- Green, Monica H. 2024. "The pandemic arc: Expanded narratives in the history of global health." *Journal of the History of Medicine and Allied Sciences* 79, no 4: 345–62.
- Haeser, Heinrich. 1845. *Lehrbuch der Geschichte der Medicin und der Volkskrankheiten*. Jena: Friedrich Mauke.
- Haeser, Heinrich. 1882. *Lehrbuch der Geschichte der Medicin und der epidemischen Krankheiten*, 3rd ed. vol. 3. Jena: Gustav Fischer.
- Hall, Amelia, and Paola Ponce. 2019. "The evidence of smallpox in the archaeological record: A case from the Saxon site of Soham, Cambridgeshire," poster, Department of Archaeology, University of York.
- Harper, Kyle. 2015. "Pandemics and passages to Late Antiquity: Rethinking the plague of c. 249–270 described by Cyprian." *JRA* 28: 223–60.
- Harris, William V. 2012. "The Great Pestilence and the complexities of the Antonine-Severan economy." In *L'impatto della peste antonina*, ed. Elio Lo Cascio, 331–38. Bari: Edipuglia.
- Hendrickson, Robert Curtis, Chunlin Wang, Eneida L. Hatcher, and Elliot J. Lefkowitz. 2010. "Orthopoxvirus genome evolution: The role of gene loss." *Viruses* 2, no. 9: 1933–67.
- Holbrook, Neil, James Wright, E. R. McSloy, and Jonny Geber. 2017. *The Western Cemetery of Roman Cirencester. Excavations at the Former Bridges Garage, Tetbury Road, Cirencester, 2011–2015*. Cirencester Excavations 7. Cirencester: Cotswold Archaeology.

- Howard-Jones, Annaliese R., and David Isaacs. 2010. "Systematic review of systemic antibiotic treatment for children with chronic and sub-acute pyogenic osteomyelitis." *Journal of Paediatrics and Child Health* 46, no. 12: 736–41.
- Jackes, Mary K. 1983. "Osteological evidence for smallpox: A possible case from seventeenth century Ontario." *American Journal of Physical Anthropology* 60, no. 1: 75–81.
- Khurana, Ankit, Anand Vardhan, and Deepak Negi. 2019. "Osteomyelitis variolosa: Forgotten complication of an eradicated disease." *Journal of Clinical Orthopaedics and Trauma* 10, no. 4: 811–15.
- Lefort, M., and Pia Bennike. 2007. "A case study of possible differential diagnoses of a medieval skeleton from Denmark: Leprosy, ergotism, treponematosi, sarcoidosis or smallpox?" *International Journal of Osteoarchaeology* 17, no. 4: 337–49.
- Littman, R. J., and M. L. Littman. 1973. "Galen and the Antonine Plague." *The American Journal of Philology* 94, no. 3: 243–55.
- Livi Bacci, M. 2012. "Note demografiche ed epidemiologiche a margine della 'Peste antonina.'" In *L'impatto della peste antonina*, ed. Elio Lo Cascio, 339–45. Bari: Edipuglia.
- Lo Cascio, Elio, ed. 2012. *L'impatto della peste antonina*. Pragmateiai 22. Bari: Edipuglia.
- Magalhães, Bruno M., Filipa T. Santos, Paula Alves Pereira, Roger Lee de Jesus, Rosa Ramos Gaspar, and Ana Luisa Santos. 2021. "Smallpox in past Portuguese populations: Three possible examples of osteomyelitis variolosa from Sarilhos Grandes (adult female) and Sertã (two ulnae)." In *The Portuguese Conference on Palaeopathology, 4–5 September 2020*, conference abstract.
- Margolis, Harold S., Kakarla Subbarao, Michael J. Pitt, and John Boyer. 1978. "Case report 58." *Skeletal Radiology* 2, no. 4: 261–63.
- McCollum, Andrea M., Yu Li, Kimberly Wilkins, Kevin L. Karem, Whitney B. Davidson, Christopher D. Paddock, Mary G. Reynolds, and Inger K. Damon. 2014. "Poxvirus viability and signatures in historical relics." *Emerging Infectious Diseases* 20, no. 2: 177–84.
- McCormick, Michael. 2021. "Gregory of Tours on sixth-century plague and other epidemics." *Speculum* 96, no. 1: 38–96.
- Miles, Adrian, Natasha Powers, and Robin Wroe-Brown. 2008. *St Marylebone Church and Burial Ground in the 18th to 19th Centuries: Excavations at St Marylebone School, 1992 and 2004–6*. MoLAS monograph 46. London: Museum of London Archaeology Service.
- Møller-Christensen, Vilhelm. 1961. *Bone Changes in Leprosy*. Transl. Julius Engelbreth-Holm. Copenhagen: Munksgaard.
- Møller-Christensen, Vilhelm. 1978. *Leprosy Changes of the Skull*. Odense: Odense University Press.
- Mugalur, Aakash, Sunil M. Shahane, Ashwin Samant, Aditya C. Pathak, and Rajeev Reddy. 2015. "Excellent functionality despite clinico-radiological deformity in osteomyelitis variolosa – A case report." *The Open Orthopaedics Journal* 9: 114–19.
- Mühlemann, Barbara, Lasse Vinner, Ashot Margaryan, Helene Wilhelmson, Constanza de la Fuente Castro, Morten E. Allentoft, Peter de Barros Damgaard, Anders Johannes Hansen, Sofie Holtsmark Nielsen, Lisa Mariann Strand, Jan Bill, Alexandra Buzhilova, Tamara Pushkina, Ceri Falys, Valeri Khartanovich, Vyacheslav Moiseyev, Marie Louise Schjellerup Jørkov, Palle Østergaard Sørensen, Yvonne Magnusson, Ingrid Gustin, Hannes Schroeder, Gerd Sutter, Geoffrey L. Smith, Christian Drosten, Ron A. M. Fouchier, Derek J. Smith, Eske Willerslev, Terry C. Jones, and Martin Sikora. 2020. "Diverse variola virus (smallpox) strains were widespread in northern Europe in the Viking Age." *Science* 369, no. 6502. <https://doi.org/10.1126/science.aaw8977>.
- Murray, Ronald O., and Harold G. Jacobson. 1977. *The Radiology of Skeletal Disorders: Exercises in Diagnosis*, 2nd ed., 4 vols. Edinburgh: Churchill Livingstone.
- Nakabachi, Kazuha, Tsutomu Endo, Masahiko Takahata, Ryo Fujita, Yoshinao Koike, Ryoto Suzuki, Yuichi Hasegawa, Toshifumi Murakami, Katsuhisa Yamada, Hideki Sudo, Mohamad Alaa Terkawi, Ken Kadoya, and Norimasa Iwasaki. 2023. "Lumbar ossification of the ligamentum flavum reflects a strong ossification tendency of the entire spinal ligament." *Scientific Reports* 13, no. 1: 638.
- Needham, Joseph, and Gwei-Djen Lu. 2000. *Science and Civilisation in China*, vol. 6. Cambridge: Cambridge University Press.
- Nema, Sandeep, G. S. Vyas, and Sunil Kukreja. 2012. "Sequelae of osteomyelitis variolosa: A case report." *Rheumatology International* 32, no. 11: 3425–27.

A case of osteomyelitis variolosa from Roman Britain

- Newfield, Timothy P., Ana T. Duggan, and Hendrick Poinar. 2022. "Smallpox's antiquity in doubt." *JRA* 35, no. 2: 897–913.
- Nikitovic, Dejana, Ivor Janković, and Sanjin Mihelić. 2012. "Juvenile elbow dislocation from the prehistoric site of Josipovac–Gravinjak, Croatia." *International Journal of Paleopathology* 2, no. 1: 36–41.
- Oliveira, Tiago Carvalho, Maria Salomé Gomes, and Ana Cordeiro Gomes. 2020. "The crossroads between infection and bone loss." *Microorganisms* 8, no. 11: 1765.
- Ortner, Donald J. ed. 2003. *Identification of Pathological Conditions in Human Skeletal Remains*, 2nd ed. San Diego: Academic Press.
- Ortner, Donald J. 2007. "Evidence of acute infectious disease in human skeletal palaeopathology." In *Peste: entre épidémies et sociétés. Plague: Epidemics and Societies*, ed. Michel Signoli, Dominique Cheve, Pascal Adalian, Gilles Boetsch, and Olivier Dutour, 103–9. Florence: Firenze University Press.
- Ortner, Donald J. 2008. "Differential diagnosis of skeletal lesions in infectious disease." In *Advances in Human Palaeopathology*, ed. Ron Pinhasi and Simon Mays, 189–214. Chichester: John Wiley & Sons.
- Oumarou Hama, Hamadou, Mahmoud A. Boualam, Anthony Levasseur, Yann Ardagna, Pascal Adalian, Annie-Claire Chaix, and Michel Drancourt. 2023. "Old world medieval *treponema pallidum* complex treponematosi: A case report." *The Journal of Infectious Diseases* 228, no. 5: 503–10.
- Panteli, Michalis, and Peter V. Giannoudis. 2016. "Chronic osteomyelitis: What the surgeon needs to know." *EFORT Open Reviews* 1, no. 5: 128–35.
- Pigrau-Serrallach, Carlos, and Dolores Rodríguez-Pardo. 2013. "Bone and joint tuberculosis." *European Spine Journal* 22 (Supplement 4): 556–66.
- Plesca, Doina Anca, Monica Luminos, Luminita Spatarui, Mihaela Stefanescu, Eliza Cinteza, and Mihaela Balgradean. 2013. "Postinfectious arthritis in pediatric practice." *Maedica* 8, no. 2: 164–69.
- Purandarnath and Balaji Douraiswami. 2011. "Osteomyelitis variolosa misdiagnosed as rheumatoid arthritis." *Journal of Clinical Orthopaedics and Trauma* 2, no. 2: 124–26.
- Redfern, Rebecca, and Charlotte A. Roberts. 2019. "Trauma." In *Ortner's Identification of Pathological Conditions in Human Skeletal Remains*, ed. Jane E. Buikstra, 211–84. London and San Diego: Academic Press.
- Resnick, Donald, and Gen Niwayama. 1995. "Osteomyelitis, septic arthritis, and soft tissue infection: Organisms." In *Diagnosis of Bone and Joint Disorders*, ed. Donald Resnick, 2448–558. Philadelphia: Saunders.
- Roberts, Charlotte A., Anwen Caffell, Kori L. Filipek-Ogden, Rebecca Gowland, and Tina Jakob. 2016. "'Til poison phosphorous brought them death': A potentially occupationally-related disease in a post-medieval skeleton from north-east England." *International Journal of Paleopathology* 13: 39–48.
- Roberts, Charlotte A. 2019. "Infectious disease: Introduction, periostosis, periostitis, osteomyelitis, and septic arthritis." In *Ortner's Identification of Pathological Conditions in Human Skeletal Remains*, ed. by Jane E. Buikstra, 285–317. London and San Diego: Academic Press.
- Roberts, Charlotte A., and Jane E. Buikstra. 2019. "Bacterial infections." In *Ortner's Identification of Pathological Conditions in Human Skeletal Remains*, ed. Jane E. Buikstra, 321–439. London and San Diego: Academic Press.
- Salmon, Marylynn. 2022. *Medieval Syphilis and Treponemal Disease*. Past Imperfect. Leeds: Arc Humanities Press.
- Shah, Kaushal Mahendra, Amol Karagir, and Shridevi Adaki. 2013. "Chronic non-suppurative osteomyelitis with proliferative periostitis or Garre's osteomyelitis." *Case Reports* 2013, no. 1: bcr2013009859–bcr59. <https://doi.org/10.1136/bcr-2013-009859>.
- Singh, Pradeep K. 2010. "Osteoarticular sequelae of smallpox: A case report." *Asian Pacific Journal of Tropical Medicine* 3, no. 12: 1001–3.
- Tang, Jinshao, Pu Shao, Te Liu, Xinggui Wen, Yeliang Wang, Chenyu Wang, Yachen Peng, Hua Yao, and Jianlin Zuo. 2021. "Osteomyelitis variolosa, an issue inherited from the past: Case report and systematic review." *Orphanet Journal of Rare Diseases* 16, no. 1: 354, 1–10.
- Thèves, Catherine, Eric Crubézy, and Philippe Biagini. 2016. "History of smallpox and its spread in human populations." *Microbiology Spectrum* 4, no. 4: 4.4.05.
- Tschinkel, Khrystyne, John Verano, and Gabriel Prieto. 2024. "Two cases of smallpox from 1540 CE circum-contact (early colonial) northern coastal Peru." *International Journal of Paleopathology* 45: 35–45.

- Waldron, Tony. 2019. "Joint disease." In *Ortner's Identification of Pathological Conditions in Human Skeletal Remains*, ed. Jane E. Buikstra 719–48. London and San Diego: Academic Press.
- Walker, Don, Natasha Powers, Brian Connell, and Rebecca C. Redfern. 2015. "Evidence of skeletal treponematosi from the medieval burial ground of St. Mary Spital, London, and implications for the origins of the disease in Europe." *American Journal of Physical Anthropology* 156, no. 1: 90–101.
- Weekes, Jake. 2019. "Archaeological evidence of social hierarchies maintained in death, and an exclusive walled cemetery at Corinium — or something else?" *JRA* 32, no. 2: 761–64.
- Wright, James, Tom Weavill, Alistair Barber, E. R. McSloy, and Jonny Geber. 2017. "Grave catalogue." In *The Western Cemetery of Roman Cirencester. Excavations at the Former Bridges Garage, Tetbury Road, Cirencester, 2011–2015*, ed. Neil Holbrook, James Wright, E. R. McSloy, and Jonny Geber, 15–75. Cirencester Excavations 7. Cirencester: Cotswold Archaeology.
- Zelener, Yan. 2012. "Genetic evidence, density dependence and epidemiological models of the 'Antonine Plague'." In *L'impatto della peste antonina*, ed. Elio Lo Cascio, 167–77. Bari: Edipuglia.