OPEN ACCESS

Clinical science

Safety and vision outcomes of subretinal gene supplementation therapy in *PDE6A*-associated retinitis pigmentosa: a non-randomised controlled trial

Felix F Reichel ,[1,2] M Dominik Fischer,[1,3] Katarina Stingl ,[1,4] Laura Kuehlewein ,[1] Immanuel Seitz ,[1,2] Tobias Peters,[1] Melanie Ziegler,[1] Barbara Wilhelm,[1] Susanne Kohl,[5] Nicole Weisschuh,[2] Peter Martus,[6] Mathias Seeliger,[2] Regine Muehlfriedel,[2] Francois Paquet-Durand,[2] Stephen H Tsang,[7] Karl Ulrich Bartz-Schmidt,[1] Marius Ueffing,[2] Eberhart Zrenner,[1] Martin Biel,[8] Bernd Wissinger,[2] Stylianos Michalakis ,[9] on behalf of the RD-Cure Consortium

► Additional supplemental material is published online only. To view, please visit the journal online (https://doi.org/10.1136/bjo-2024-326480).

For numbered affiliations see end of article.

Correspondence to
Professor Stylianos Michalakis; stylianos.michalakis@cup.uni-muenchen.deProfessor Martin Biel; martin.biel@cup.uni-muenchen.de and Professor Bernd Wissinger; bernd.wissinger@med.uni-tuebingen.de

FR, MDF and KS contributed equally.

Received 11 September 2024
Accepted 30 June 2025

Check for updates

© Author(s) (or their employer(s)) 2025. Re-use permitted under CC BY-NC. No commercial re-use. See rights and permissions. Published by BMJ Group.

To cite: Reichel FF, Fischer MD, Stingl K, *et al*. *Br J Ophthalmol* Epub ahead of print: [*please include* Day Month Year]. doi:10.1136/bjo-2024-326480

ABSTRACT

Purpose *PDE6A*-associated retinitis pigmentosa (RP) is a rare inherited retinal disease leading to severe vision loss and blindness, with no available treatment. This study assessed the safety and vision outcomes of a gene therapy using an adeno-associated virus (AAV) vector encoding PDE6A (AAV8.hPDE6A).

Methods In an open-label, non-randomised controlled phase I/IIa trial, nine patients with biallelic *PDE6A* variants received a single subretinal injection of AAV8.hPDE6A. Doses were either 1.0×10^{10} (n=6) or 5.0×10^{10} (n=3) total vector genomes. Safety was the primary endpoint, assessed via clinical examinations, laboratory analyses and optical coherence tomography imaging. Secondary outcomes included changes in visual function, such as best corrected visual acuity (BCVA), contrast sensitivity, colour perception, dark adaptation thresholds, visual fields, patient-reported outcomes and chromatic pupil campimetry over 1 year.

Results The mean patient age was 40.1 years, with baseline BCVA ranging from 40 to 82 letters (0.9–0.1 logMAR). No systemic adverse events occurred, and most ocular events resolved without treatment. Persistent adverse events included small peripheral atrophic areas (n=2), disturbed colour discrimination (n=3), cataract (n=1), slight central retinal thinning (n=5) and moderate visual acuity loss (n=2, 1 in each dose group). BCVA, full-field stimulus thresholds and other visual function measures showed statistically non-significant changes, with a trend towards worsening of retinal sensitivity in the treated eyes.

Conclusion Subretinal gene therapy with AAV8.hPDE6A did not improve visual function over 1 year and posed risks, including central retinal thinning and visual acuity decline. This is in contrast to the safety and efficacy profile established in preclinical models.

WHAT IS ALREADY KNOWN ON THIS TOPIC

⇒ *PDE6A*-associated retinitis pigmentosa (RP) is an inherited retinal disorder causing severe vision loss, with no current treatment available. Gene therapy with adeno-associated viruses (AAVs) shows promise for *PDE6A*-associated RP, as preclinical studies demonstrated safe and effective restoration of morphological and functional endpoints in small and large animal models.

WHAT THIS STUDY ADDS

⇒ This study found that subretinal gene therapy with AAV8.hPDE6A did not improve visual function in patients with advanced disease over 1 year. It further highlighted risks, including central retinal thinning and moderate visual acuity decline in some patients.

HOW THIS STUDY MIGHT AFFECT RESEARCH, PRACTICE OR POLICY

⇒ The findings warrant caution in using subretinal gene therapy for *PDE6A*-associated RP with detachment of the central macula and underscore the need for further research to understand and mitigate potential adverse effects.

INTRODUCTION

PDE6A-associated retinitis pigmentosa (RP) represents a rare form of inherited retinal disease (IRD), characterised by nyctalopia, visual field defects and significant loss of visual acuity. The disease primarily affects the rod photoreceptors, followed by secondary loss of cones.[1] Nyctalopia often presents as the initial clinical manifestation, followed by progressive concentric mid-peripheral visual field defects. Visual acuity decline typically occurs in the course of the disease due to macular oedema or foveal involvement of the atrophy.[2]

The condition is inherited in an autosomal recessive manner and is caused by biallelic disease-causing variants in *PDE6A* encoding the alpha subunit of rod-specific phosphodiesterase 6 (PDE6). The function of this protein is to hydrolyse intracellular cyclic guanosine monophosphate in response to light, an essential step of the phototransduction cascade. PDE6 is a heterotetramer incorporating the catalytic alpha (PDE6A) and beta (PDE6B) subunits and two inhibitory gamma subunits (PDE6G).[3] Biallelic disease-causing variants in the genes encoding either catalytic subunits PDE6A or PDE6B, but also the inhibitory subunit PDE6G, are associated with autosomal recessive RP.**4–6**

PDE6A-associated RP accounts for approximately 1% of patients with recessive RP,[7–12] with numerous mutations and genotypes influencing disease course and severity.[2]

Currently, no treatment is available for this debilitating disease. However, among the investigated treatment modalities for IRDs, gene supplementation therapy shows promise. This approach has been successfully employed in *RPE65*-associated IRD, leading to the approval of voretigene neparvovec, an adeno-associated virus (AAV) vector-based gene therapy administered via subretinal injection.[13]

A comparable treatment concept was developed for *PDE6A*-associated RP and tested in this trial. An AAV8-pseudotyped AAV2 vector delivering *PDE6A* cDNA (complementary deoxyribonucleic acid) under the control of a human rhodopsin (hRHO) promoter (AAV8.hPDE6A) was developed targeting rod photoreceptors with the aim to restore their function and prevent secondary cone degeneration. Preceding this clinical trial, proof of principle studies in small and large animal models have shown functional rescue and morphological preservation.[14–16] Herein, we present the safety and efficacy outcomes observed in a phase I/IIb clinical trial testing the AAV8.hPDE6A gene therapy in nine patients with *PDE6A*-associated RP.

METHODS

Study design, dosing and patients

This was an open-label, exploratory non-randomised, fellow eye-controlled phase I/II trial testing safety and vision outcomes of gene therapy vector rAAV8.hPDE6A administered by subretinal injection (ClinicalTrials.gov ID: NCT04611503). Nine patients (four men and five women) with a clinical diagnosis of PDE6A-associated RP and confirmed biallelic disease-linked variants in *PDE6A* were enrolled and received a single unilateral injection of 1.0×10^{10} (n=6 patients) or 5.0×10^{10} (n=3 patients) total vector genomes of AAV8.hPDE6A. In general, the worse-seeing eye based on the subjective judgement by the patient and clinical examination was selected as the study eye. Additional information and trial protocol can be found in the online supplemental eAppendix. See table 1 for an overview of the patient cohort.

Vector production

The vector design has been previously described.[14] In short, the vector contained a single-strand DNA genome comprising a pair of AAV2-derived inverted terminal repeats flanking a gene expression cassette with a rod photoreceptor-specific human rhodopsin promoter, the full-length human *PDE6A* cDNA, a woodchuck hepatitis virus post-transcriptional regulatory element with mutated woodchuck hepatitis virus X protein (WHX), a bovine growth hormone polyadenylation signal and was pseudotyped with an AAV8 capsid.[17] More details can be found in the online supplemental eAppendix and the study protocol.

Table 1 Clinical and ocular characteristics of included patients with *PDE6A*-associated RP treated with AAV8.PDE6A at baseline and year 1

				BCVA (EDTRS letters)		Central retinal thickness (µm)		Visual field (degree^2)		Full-field stimulus threshold (db)		Dark-adapted perimetry (db)	
Patient No.	Age at surgery	Disease causing variants	Dose, eye	Baseline	Year 1, (Delta)	Baseline	Year 1, (Delta)	Baseline	Year 1, (Delta)	Baseline	Year 1, (Delta)	Baseline	Year 1, (Delta)
1	44	c.(1926+1G>A); (63_68del); p.(?); (Lys21_Tyr23delinsAsn)	1×10^{10}, OS	50	51 (+1)	205	205 (0)	254.80	361.5 (+106.7)	NA	NA	4.78	4.89 (+0.11)
2	51	c.(2053G>A); (2053G>A); p.(Val685Met); (Val685Met)	1×10^{10}, OS	40	35 (−5)	184	177 (−7)	212.50	188.1 (−24.4)	NA	NA	1.67	1.61 (−0.06)
3	60	c.(1065+2T>A); (1705C>A); p.(?); (Gln569Lys)	1×10^{10}, OS	51	42 (−9)	208	178 (−30)	309.60	223.4 (−86.2)	NA	NA	1.61	1.53 (−0.08)
4	38	c.(1263+1G>A); (1683G>A); p.(?); (p.Trp561Ter)	5×10^{10}, OD	78	76 (−2)	254	209 (−45)	2263.80	2225.7 (−38.1)	−16.55	−14.25 (2.3)	8.86	7.17 (−1.69)
5	20	c.(998+2T>G); (1957C>T); p.(?); (p.Arg653Ter)	5×10^{10}, OS	82	83 (+1)	279	247 (−32)	1772.90	1997.6 (+224.7)	−19.21	−15.72 (3.49)	5.28	4.86 (−0.42)
6	26	c.(304C>A); (1689C>A); p.(Arg102Ser); (His563Gln)	5×10^{10}, OD	77	79 (+2)	292	234 (−58)	5634.10	5293.6 (−340.5)	−19.95	−15.95 (4)	9.78	6.03 (−3.75)
7	34	c.(304C>A); (2053G>A); p.(Arg102Ser); (Val685Met)	1×10^{10}, OS	79	80 (+1)	312	205 (−107)	30.10	14.6 (−15.5)	−24.27	−19.49 (4.78)	3.92	0.56 (−3.36)
8	35	c.(1843C>T); (2380_2382del); p.(Gln615Ter); (Glu794del)	1×10^{10}, OD	55	61 (+6)	192	184 (−8)	269.20	250.1 (−19.1)	−3.68	−4.83 (−1.15)	1.33	1.33 (0)
9	53	c.(304C>A); (1705C>A); p.(Arg102Ser); (Gln569Lys)	1×10^{10}, OD	70	60 (−10)	240	184 (−56)	326.40	364.2 (+37.8)	−12.01	−4.07 (7.94)	1.69	1.08 (−0.61)

BCVA, best corrected visual acuity; EDTRS, early treatment diabetic retinopathy study; RP, retinitis pigmentosa.

Preclinical testing

Transgene expression (immunolabelling of human PDE6A) and biological activity (electrophysiological testing, in vivo imaging and behavioural tests) were assessed in small and large animal models.[14 15] Safety was tested in a toxicology and biodistribution study (n=34, 13 weeks follow-up) in non-human primates (NHPs). No observed adverse effect level (NOAEL) was 5×10^{11} vg, while a dose of 1×10^{12} vg was associated with atrophic changes of the retina in the NHP. A 10-fold lower dose than the NOAEL was chosen as the high dose for the clinical trial (5×10^{10}). A fivefold lower dose than the high dose was chosen as the starting dose (1×10^{10}).

Surgery and concomitant medication

Following vitrectomy and the creation of a small localised subretinal prebleb with balanced salt solution, 100 µl of AAV.hPDE6A were administered through the same retinotomy into the subretinal space.[18] Postoperatively, patients were treated with body weight-adapted oral prednisolone, tapered out over a 21-day period. Details on the surgical procedure and concomitant medication can be found in the online supplemental eAppendix.

Clinical investigation

Safety as the primary endpoint was assessed by ophthalmological examination for signs of intraocular inflammation. Systemic safety parameters included vital signs, analysis of clinical blood tests (differential blood count, basic chemistry, C-reactive protein, IgM titre, IgG titre), quantitative polymerase chain reaction-based analysis of vector shedding and biodistribution and documentation of adverse events. Efficacy of the treatment as the secondary objective was explored by best corrected visual acuity (BCVA) assessed with early treatment diabetic retinopathy study charts, contrast sensitivity (Pelli-Robson charts), colour vision (Roth 28-hue panel test, total error score calculated as described by Vingrys *et al*[19]), kinetic visual field (Goldmann semiautomatic III4e isopter), scotopic visual field (Medmont DAC (dark-adapted chromatic) perimeter), full-field stimulus threshold (FST), chromatic pupil campimetry (CPC, objective measurement of pupil light responses to perimetric stimuli by infrared-video-pupillography using chromatic rod and cone protocols,[20] patient-reported outcomes (Visual Function Questionnaire 25 (VFQ-25)), as well as high-resolution retinal imaging (optic coherence tomography, OCT; 55° fundus autofluorescence, FAF) recorded at screening and throughout the follow-up period for 1 year. OCT analysis included qualitative assessment as well as quantitative assessment of central retinal thickness (CRT) (average central 1 mm thickness in high density 20° by 20° volume scans) and ellipsoid zone (EZ) line length on central horizontal B-scan.

Statistical analysis

Descriptive statistics were used for clinical and demographical data. Where appropriate, mean values are presented with SD and the change in visual function with 95% CI. The untreated fellow eye was used as the control eye (CE). Functional outcomes were assessed as the change from baseline to year 1, compared between the treated eye (TE) and CE using parametric (two-sided t-test) and non-parametric (Wilcoxon signed rank test) analyses, with a p value of <0.05 indicating statistical significance. The trial was not designed to formally test efficacy effects, and no formal sample size estimation was performed *a priori*. The small number of nine patients limits the possibility to prove relevant effects with sufficient statistical power, and no correction for multiple testing was possible.

RESULTS

Patient characteristics at baseline

The mean age of the nine patients (five female, 55%) was 40.1 years (SD 13.1; range 20–60 years). The BCVA letter score (approximate equivalent in logarithm of minimum angle of resolution, logMAR) ranged from 40 (0.9) to 82 (0.1). FST values, measured by blue and red stimuli, were cone-driven with a difference between the red and blue stimuli of <10 dB.[21] The kinetic visual field ranged from absolute concentric restriction to 5° (III4e light stimulus) to midperipheral scotomas of about 50% of the normal kinetic visual field (III4e). In the scotopic rod CPC protocol, only two patients showed residual traces of rod responses via the pupillary light reflex in the TE at baseline (online supplemental eFigure 12). The fellow eyes did not have any measurable rod CPC responses. The structure of the macula on OCT ranged from well-preserved central islands to significant atrophy of the foveal photoreceptor layers. Supplemental online supplemental eFigure 1 shows baseline and year 1 visual field data and macula morphology of all TEs.

Primary outcome

Clinical examination revealed only very mild postoperative anterior chamber (AC) and vitreous inflammation (eight patients, 0.5+ to 1+ cells), which had resolved (7/8) at day 14 under local and systemic steroid treatment. No inflammation was noted after 30 days in any of the eyes treated. See online supplemental eFigure 2 for a detailed overview of inflammatory cells at each visit. Systemic safety analysis, including vital signs and clinical laboratory analysis, showed no clinically significant effects. None of the patients showed significant vector shedding.

Ocular adverse events, deemed related to the study drug or procedure, included transient intraretinal hyper-reflective dots (HRDs) on OCT (n=1), worsening of cataract (n=1), small areas of chorioretinal atrophy (CRA) at the site of injection (n=2), disturbed colour discrimination (n=3), foveal thinning (n=5) and decline in visual acuity (n=1). One serious adverse event (SAE), a BCVA loss ≥15 letters, was deemed related to the treatment. The patient who developed HRD on OCT at day 30 (patient 06), potentially indicating a subclinical immune response, was treated with a second course of oral prednisolone, under which the HRDs resolved. In the two patients with small areas of CRA at the injection site (patients 04 and 07), a localised transient retinal pigment epithelium (RPE) detachment due to inadvertent sub-RPE injection was noted either during surgery (patient 04) or during imaging (patient 07) performed at day 2 postsurgery (see supplemental online supplemental eFigure 3). The CRA was limited to the area of inadvertent sub-RPE injection, and no CRA (monitored with 55° FAF imaging and funduscopic examination) was observed in any of the other patients.

The adverse event of foveal thinning was found in five patients (patients 04, 05, 06, 07 and 09), who were also the ones with the best-preserved foveal architecture and the largest CRT at baseline. Comparison of mean CRT showed statistically significant central retinal thinning in the TE compared with the CE. Additionally, patients with an intact EZ line at baseline displayed shortening and disruption of the horizontal EZ line in the TE compared with the CE (patients 04, 05, 06 and 07) and a reduction of the bright autofluorescence area in FAF imaging (patients 04, 06 and 07), both known markers of disease progression in *PDE6A*-associated RP[22] (see online supplemental eFigure 1 for

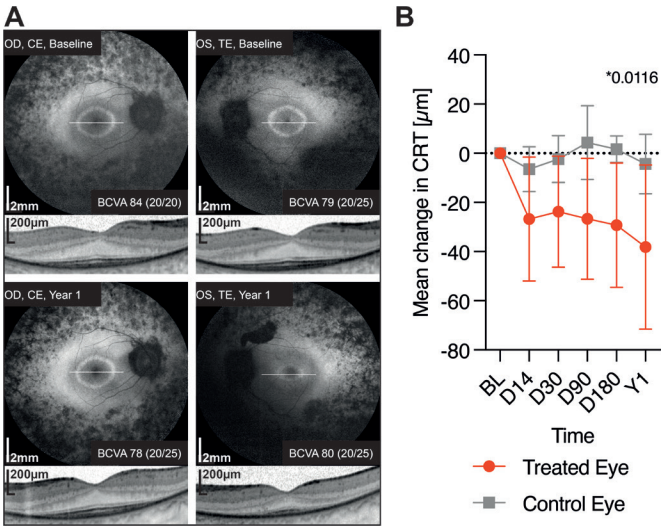

Figure 1 Patient 07, 55° fundus autofluorescence at baseline and year 1 (treated eye (TE) and fellow control eye (CE)), note the loss of ellipsoid zone (EZ) line length, central autofluorescence and central retinal thickness (CRT) in the TE. White line indicates the location of OCT section. BCVA=best corrected visual acuity as EDTRS letter score (Snellen fraction). (B) Mean change of CRT of TE and CE of all patients within the first year. Error bars indicate SD. *P value for two-sided t-test (comparison between TE and fellow eye at year 1). EDTRS, early treatment diabetic retinopathy study; OCT, optic coherence tomography.

OCT and FAF imaging at baseline and year 1). A representative case showing shortening of horizontal EZ line length, decrease of the mean CRT and reduction of bright autofluorescence area is displayed in figure 1. Of note, the reduction of CRT did not statistically correlate with a decline in BCVA at year 1 (table 1 column 6 BCVA and 8 CRT; correlation coefficients not shown).

Colour discrimination was tested throughout the study with the Roth 28 colour panel test,[23] and the majority of patients did not present significant changes in colour discrimination. However, three patients with foveal thinning (patients 06, 07 and 09) also showed a moderate increase in total error score with confusions mostly aligned with the blue–yellow axis on the Roth 28 panel test (see online supplemental eFigure 4).

Concerning visual acuity, a transient decline in BCVA was noted in seven out of nine patients. As the detachment of the fovea was part of the study procedure, this was expected and not considered an adverse event per se. In five patients, this decline was mild and temporary and had resolved at day 90. However, two patients (change Y1-BL in letters, logMAR), low-dose patient 03 (−9 to –0.3) and patient 09 (−10 to –0.2), experienced a moderate (based on recommendations of drug agencies)[24] decline in visual acuity that was not resolved by year 1. A BCVA loss of 16 letters after surgery in patient 09 was recorded as an SAE (SAE definition ≥15 letters) and recovered partially to a BCVA loss of 10 letters at the end of year 1. For a detailed overview of all adverse events, see online supplemental eTable 1-3.

Secondary outcomes

The study was not designed to formally test efficacy. However, several functional endpoints related to rod and cone vision were assessed in all patients throughout the study.

The mean changes in comparison to the CE of the most relevant functional tests are displayed in figure 2 and summarised for year 1 in table 2. Although the change in BCVA, contrast sensitivity, colour discrimination, FST and DAC perimetry suggests a slight worsening at year 1, no statistically significant difference between the TE and the CE was found for any of the functional tests.

The results from the CPC are displayed in online supplemental eFigure 12-14**eFig 12–14**. The rod CPC protocol in two patients with residual traces at baseline showed loss of responses in the TE up to year 1. Cone CPC showed worsening only in the TE, which partially recovered at year 1.

In the VFQ-25 and study-specific A6-PRO (patient-reported outcome) questionnaire, patients reported neither significant beneficial effects nor significant vision losses in daily living situations. Detailed results can be found on online supplemental eFigure 5-11.

DISCUSSION

The results from the first human phase I/IIa clinical trial assessing supplemental gene therapy for *PDE6A*-associated RP indicate that subretinal administration of AAV8.hPDE6A in patients with advanced disease could not improve or stabilise photoreceptor visual function or retinal morphology within the observed time frame of 1 year. Although the treatment was generally well tolerated with no or only minimal signs of local inflammation, the subretinal injection of AAV8.hPDE6A was associated with local adverse effects and, in some cases, moderate (based on recommendations of drug agencies)[24] deterioration of visual function in the TE compared with the untreated eye. It cannot be discerned to what extent average worsening of secondary endpoints and retinal thinning indicate loss of photoreceptor function and/or acceleration of disease progression. No clear relation between retinal thinning and BCVA or FST could be established. These findings were somewhat unexpected following the evident benefit of treatment with AAV8.hPDE6A in preclinical studies. Proof-of-principle studies in mutant mice and dog models had reported improved retinal function and morphology at comparable and higher dose levels.[14 15] In dogs, dose levels up to 5.9×10^{11} vg (ie, one log unit higher than the high dose used in the clinical trial) were well-tolerated. Similarly, in healthy NHPs, no adverse events were noted up to a dose of 5×10^{11} vg.[25] The fact that higher doses led to positive effects in the animal models begs the question of whether the dose levels chosen in the clinical trial were below the minimally effective dose. The allometric scaling across species takes into account differences in anatomical factors and the potential number of target cells in the treated area to calculate the equivalent multiplicity of infection or number of infectious particles (AAV). This poses the challenge of predicting the bleb size and position during and after surgery and predicting the cell density within the context of progressive IRD. Other potential confounding factors that could explain the discrepancy between the preclinical findings and the clinical study results include interspecies differences in terms of vector transduction efficacy, immune response and degeneration status at the time of treatment, as well as the actual rate of progression of degeneration, which is much slower in patients than in mouse and dog models of *PDE6A*-RP.

Notably, preclinical studies were carried out in animals of very young age. Studies in mice, investigating the effect of the treatment time point of retinal degeneration, have shown that early treatment in gene therapy is paramount for success.[26] In the *PDE6A*-RP animal model studies, mutant mice were injected at postnatal (PN) day 14 and dogs at week 4. In contrast to the morphological baseline findings of our trial patient cohort, which all featured advanced disease, the

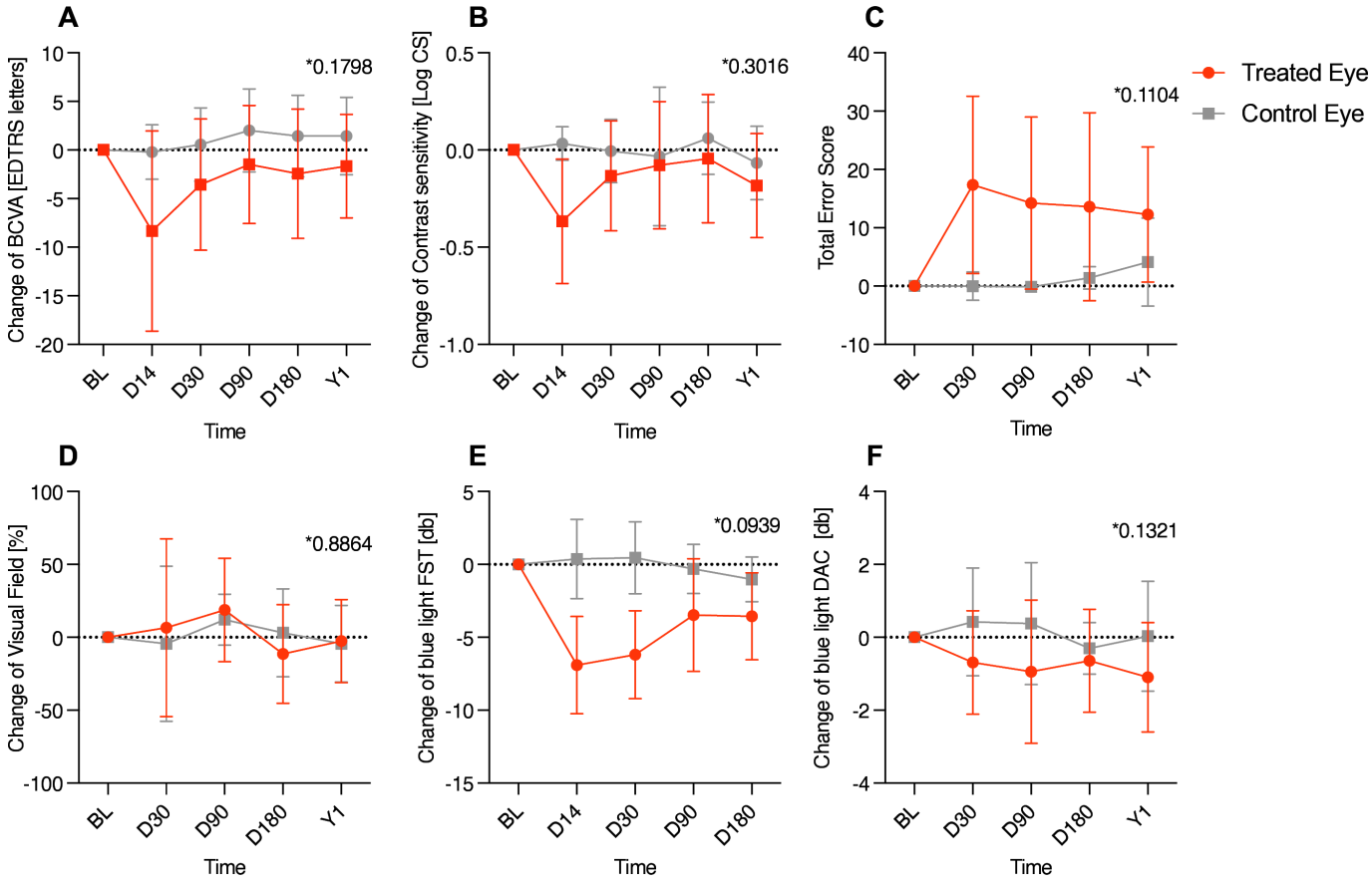

Figure 2 Mean change from baseline (BL) of best corrected visual acuity (BCVA) measured with early treatment diabetic retinopathy study (EDTRS) letter chart. (B) Mean change of Pelli-Robson Contrast Sensitivity (CS) chart results. (C) Mean change of Total Error Score in Roth 28-colour panel test (high score meaning poor performance in the test). (D) Mean change of kinetic visual field degree^2 measured with III4e light stimulus and presented as percentage of baseline visual field area. (E) Mean change of full-field stimulus threshold test with blue light stimulus. (F) Mean change of mean sensitivity in dark-adapted chromatic perimetry with blue light stimulus. Error bars indicate SD. *P value for two-sided t-test (comparison between treated eye and fellow eye at year 1). FST, field stimulus threshold.

Table 2 Baseline and year 1 functional and morphological outcomes of the treated eye and control eye

	Treated eye			Control eye			
Outcome	Baseline, mean (SD)	1 year, mean (SD)	Mean change (95% CI)	Baseline, mean (SD)	1 year, mean (SD)	Mean change (95% CI)	Parametric/non-parametric p value***
BCVA (EDTRS letters)	64.67 (15.68)	63 (17.66)	−1.67 (−5.77, 2.44)	70.11 (14.21)	71.56 (11.91)	1.44 (−1.61, 4.5)	0.22/0.25
Visual field (degree^2)	1230 (1829)	1213 (1737)	−17.2 (−134.6, 100.2)	1489 (2139)	1329 (1786)	−160.9 (−492.6, 170.8)	0.22/0.73
Blue Light FST (db)	−15.94 (7.24)	−12.38 (6.39)*	3.56 (0.42, 6.7)**	−16.88 (5.68)	−15.86 (5.16)*	−1.02 (−2.64, 0.60)**	**0.04**/0.06
Dark-adapted perimetry (db)	4.32 (3.2)	3.23 (2.49)	−1.1 (−2.25, 0.06)	4.47 (3.07)	4.49 (3.33)	0.03 (−1.13, 1.19)	**0.03**/0.05
Contrast sensitivity (Pelli-Robson Score)	1.11 (0.59)	0.93 (0.61)	−0.18 (−0.39, 0.02)	1.28 (0.47)	1.21 (0.48)	−0.07 (−0.21, 0.08)	0.38/0.59
Roth 28 colour test (Total Error Score)	20.6 (15.5)	32.89 (12.18)	12.29 (3.38, 21.2)**	21.23 (14.99)	26.9 (15.68)	4.11 (−2.21, 10.44)**	0.06/0.05
Central retinal thickness (µm)	240.7 (46.49)	202.6 (24.91)	−38.11 (-63.81, −12.42)	246.1 (52.68)	241.8 (52.51)	−4.33 (−13.64, 4.97)	**0.03/0.03**

*FST values from month 6 (FST not performed on Y1); ** positive value indicates loss of sensitivity; ***comparison of mean change in the treated eye with mean change in the control eye. (Paired student's t-test/Wilcoxon signed-rank test).
p value < 0.05 in bold
BCVA, best corrected visual acuity; EDTRS, early treatment diabetic retinopathy study; FST, field stimulus threshold.

retina of these animals at that age is only very mildly affected. The *Pde6a*:Asp670Gly mutant mice at day 14 have a slightly thinned outer nuclear layer but normal inner and outer segment length, and the dogs at week 4 display distorted but still present photoreceptor outer segments.[27 28] Although it is difficult to assess the number of remaining rods and cones in vivo, the significant thinning of the outer nuclear layer outside the central preserved region indicates that our patients likely began the trial with a substantially reduced number of rod photoreceptors at baseline. This would limit the potential of any clinical benefit, as the treatment was specifically targeted at rod photoreceptors, aiming at their functional and morphological preservation to prevent secondary degeneration of the remaining cone photoreceptor population. However, even in the only two patients with measurable rod function in the CPC at baseline, no improvement was noted, and CPC responses 1 year after treatment indicated a loss of measurable rod function.

With the potential for a treatment effect reduced *a priori*, the risk/benefit ratio quickly becomes challenging. Although there is evidence that short-lived iatrogenic detachment of healthy retina can be well-tolerated, photoreceptor degeneration is a well-known consequence of retinal detachment even in otherwise healthy eyes.[29 30] In the preclinical large animal studies, a significant loss of retinal cells was not observed, but the advanced disease stage in our patient cohort at baseline may make the retina more susceptible to additional damage and increase the risk for further cell loss due to the surgical intervention. Only one study using the same breed of *Pde6a* mutant dogs but a different AAV vector has reported the adverse event of retinal atrophy in vector TEs. Unfortunately, the study did not include a comparison with sham-injected eyes, leaving the question open to what degree the detachment of a retina with *PDE6A*-associated RP is causative for these adverse events.[16]

The postoperative loss of CRT and the transient functional impairment (first visit at week 2) with slow and incomplete resolution suggest that very early, if not immediate, effects of the surgical procedure may be the main cause of the adverse events observed. While this could be explained by an incapacity of the degenerated retina to recover from the detachment, the procedure itself was similar to other subretinal gene therapies. Therefore, undesired effects of the vector or a subclinical immune response must also be considered. Immune responses to AAV-mediated subretinal gene therapy have been described previously, though in general at doses above the high dose of this study.[31]

The findings of this study should be interpreted in light of its limitations, including the open-label, non-randomised controlled trial design, the small sample size (nine patients total) and the relatively short duration of follow-up.

In summary, subretinal gene therapy with AAV8.hPDE6A did not result in functional improvements in our patient cohort at the dose level applied. We did not observe preservation of cone photoreceptor function or functional rescue of rods, but in some patients, we recorded a decline in visual function and morphological alterations of photoreceptors that did not completely resolve over the observation period of 1 year. It is important to note that due to the slow rate of progression of *PDE6A*-RP, which typically exhibits annual BCVA decline rates of 0.015 to 0.037 logMAR,[1 2 32] a follow-up of 12 months would likely not be sufficient to detect a slowing down of disease progression. It remains open whether a different dose or an optimised vector with broader transduction efficiency and/or the capability to spread laterally beyond the bleb margins, enabling subretinal treatment without foveal detachment, would lead to more positive efficacy outcomes.

Author affiliations
[1]University Eye Hospital, Centre for Ophthalmology, University Hospital Tübingen, Tübingen, Germany
[2]Institute for Ophthalmic Research, Centre for Ophthalmology, Centre for Ophthalmology, University Hospital Tubingen, Tübingen, Germany
[3]Nuffield Department of Clinical Neurosciences, University of Oxford, Oxford, UK
[4]Centre for Rare Eye Diseases, University of Tübingen, Tübingen, Germany
[5]Molecular Genetics Laboratory, Institute for Ophthalmic Research, Centre for Ophthalmology, University Hospital Tübingen, Tübingen, Germany
[6]Institute of Clinical Epidemiology and Applied Biometrics, University of Tübingen, Tübingen, Germany
[7]Department of Ophthalmology, Columbia University, New York, NY, USA
[8]Department of Pharmacy, Center for Drug Research, LMU Munich, Munich, Germany
[9]Department of Ophthalmology, LMU University Hospital, LMU Munich, Munich, Germany

X Felix F Reichel @FFLReichel

Collaborators RD-Cure Consortium: coordination: project coordinator: Professor Dr BM, Molecular Genetics Laboratory, Institute for Ophthalmic Research, Centre for Ophthalmology; project co-coordinator: Professor Dr MB, Department of Pharmacy—Center for Drug Research, Ludwig-Maximilians-Universität München, Scientific Representative of the Tistou and Charlotte Kerstan Foundation: Professor Dr med. Dr h.c. mult. EZ, Institute for Ophthalmic Research, Centre for Ophthalmology, University of Tübingen. Further project partners: University Eye Hospital, Centre for Ophthalmology, University of Tübingen, Professor KUB-S. Professor Dr DF, Institute for Ophthalmic Research, Centre for Ophthalmology, University of Tübingen, Dr SK, Dr LK, Professor Dr FP-D, Professor Dr med. Dipl. Ing. MS, Professor Dr MU, Dr NW, PD Dr DZ, STZ eyetrial, Centre for Ophthalmology, University of Tübingen, Dr NK, Dr TP, Professor med. BW. Department of Pharmacy—Center for Drug Research, Ludwig-Maximilians-Universität München: PD Dr SM. Reviewers and advisory board: Professor JB (F.M. Kirby Center for Molecular Ophthalmology, University of Pennsylvania, Philadelphia, USA). Dr OH (Achromatopsie Selbsthilfe e.V., Dorsten, Germany), Professor PH (Smurfit Institute of Genetics, Trinity College, Dublin, Ireland), Professor RM (Dept. of Biochemistry and Molecular Biology, University of British Columbia, Vancouver, Canada) and Professor JW (Netherlands Institute for Neuroscience, Royal Netherlands Academy of Arts & Sciences, Amsterdam, The Netherlands). Funding agency: Tistou & Charlotte Kerstan Stiftung. Website: www.rd-cure.de.

Contributors Author Contributions: FR, MDF and KS contributed equally and are the guarantors of the study. Concept and design: MDF, KS, BW and MZ. Acquisition, analysis or interpretation of data: FR, MDF, KS, PM and TP. Drafting of the manuscript: FR, MDF and KS. Critical revision of the manuscript for important intellectual content: FR, MDF, KS, TP, IS, BW, SK, NW, MS, EZ, MB, BW and SM. Statistical analysis: FR, MDF, KS and PM. Obtained funding: DM, KS, SM, SHT, KUB-S, MU, EZ, MB, BW and RD-Cure Consortium. Administrative, technical or material support: BW, NW, LK, TP, MB and BW. Supervision: MDF, KS, BW, SK, TP, MU, EZ and MB.

Competing interests None declared.

Patient consent for publication Not applicable.

Ethics approval This study involves human participants and was approved by the Ethics Committee of the Medical Faculty of the University of Tübingen, Project No.: 884/2018AMG1 Paul Ehrlich Institute Study No.: RDC-PDE6A-01. Participants gave informed consent to participate in the study before taking part.

Provenance and peer review Not commissioned; externally peer reviewed.

Data availability statement Data are available upon reasonable request. The datasets generated and analysed during the current study are available from the corresponding author on request.

Supplemental material This content has been supplied by the author(s). It has not been vetted by BMJ Publishing Group Limited (BMJ) and may not have been peer-reviewed. Any opinions or recommendations discussed are solely those of the author(s) and are not endorsed by BMJ. BMJ disclaims all liability and responsibility arising from any reliance placed on the content. Where the content includes any translated material, BMJ does not warrant the accuracy and reliability of the translations (including but not limited to local regulations, clinical guidelines, terminology, drug names and drug dosages), and is not responsible for any error and/or omissions arising from translation and adaptation or otherwise.

Open access This is an open access article distributed in accordance with the Creative Commons Attribution Non Commercial (CC BY-NC 4.0) license, which permits others to distribute, remix, adapt, build upon this work non-commercially, and license their derivative works on different terms, provided the original work is

properly cited, appropriate credit is given, any changes made indicated, and the use is non-commercial. See: http://creativecommons.org/licenses/by-nc/4.0/.

ORCID iDs
Felix F Reichel http://orcid.org/0000-0001-9325-5616
Katarina Stingl http://orcid.org/0000-0002-8132-911X
Laura Kuehlewein http://orcid.org/0000-0003-1906-8681
Immanuel Seitz http://orcid.org/0000-0002-3086-6425
Stylianos Michalakis http://orcid.org/0000-0001-5092-9238

REFERENCES

1 Kuehlewein L, Zobor D, Andreasson SO, *et al*. Clinical Phenotype and Course of PDE6A-Associated Retinitis Pigmentosa Disease, Characterized in Preparation for a Gene Supplementation Trial. *JAMA Ophthalmol* 2020;138:1241–50.
2 Kuehlewein L, Straßer T, Blumenstock G, *et al*. Central Visual Function and Genotype-Phenotype Correlations in PDE6A-Associated Retinitis Pigmentosa. *Invest Ophthalmol Vis Sci* 2022;63:9.
3 Cote RH, Gupta R, Irwin MJ, *et al*. Photoreceptor Phosphodiesterase (PDE6): Structure, Regulatory Mechanisms, and Implications for Treatment of Retinal Diseases. *Adv Exp Med Biol* 2022;1371:33–59.
4 Huang SH, Pittler SJ, Huang X, *et al*. Autosomal recessive retinitis pigmentosa caused by mutations in the alpha subunit of rod cGMP phosphodiesterase. *Nat Genet* 1995;11:468–71.
5 McLaughlin ME, Sandberg MA, Berson EL, *et al*. Recessive mutations in the gene encoding the beta-subunit of rod phosphodiesterase in patients with retinitis pigmentosa. *Nat Genet* 1993;4:130–4.
6 Dvir L, Srour G, Abu-Ras R, *et al*. Autosomal-recessive early-onset retinitis pigmentosa caused by a mutation in PDE6G, the gene encoding the gamma subunit of rod cGMP phosphodiesterase. *Am J Hum Genet* 2010;87:258–64.
7 Sharon D, Ben-Yosef T, Goldenberg-Cohen N, *et al*. A nationwide genetic analysis of inherited retinal diseases in Israel as assessed by the Israeli inherited retinal disease consortium (IIRDC). *Hum Mutat* 2020;41:140–9.
8 Khateb S, Nassisi M, Bujakowska KM, *et al*. Longitudinal Clinical Follow-up and Genetic Spectrum of Patients With Rod-Cone Dystrophy Associated With Mutations in *PDE6A* and *PDE6B* . *JAMA Ophthalmol* 2019;137:669.
9 Weisschuh N, Obermaier CD, Battke F, *et al*. Genetic architecture of inherited retinal degeneration in Germany: A large cohort study from a single diagnostic center over a 9-year period. *Hum Mutat* 2020;41:1514–27.
10 Karali M, Testa F, Di Iorio V, *et al*. Genetic epidemiology of inherited retinal diseases in a large patient cohort followed at a single center in Italy. *Sci Rep* 2022;12:20815.
11 Perea-Romero I, Gordo G, Iancu IF, *et al*. Genetic landscape of 6089 inherited retinal dystrophies affected cases in Spain and their therapeutic and extended epidemiological implications. *Sci Rep* 2021;11:1526.
12 Stone EM, Andorf JL, Whitmore SS, *et al*. Clinically Focused Molecular Investigation of 1000 Consecutive Families with Inherited Retinal Disease. *Ophthalmology* 2017;124:1314–31.
13 Russell S, Bennett J, Wellman JA, *et al*. Efficacy and safety of voretigene neparvovec (AAV2-hRPE65v2) in patients with RPE65 -mediated inherited retinal dystrophy: a randomised, controlled, open-label, phase 3 trial. *The Lancet* 2017;390:849–60.
14 Schön C, Sothilingam V, Mühlfriedel R, *et al*. Gene Therapy Successfully Delays Degeneration in a Mouse Model of *PDE6A*-Linked Retinitis Pigmentosa (RP43). *Hum Gene Ther* 2017;28:1180–8.
15 Occelli LM, Schön C, Seeliger MW, *et al*. Gene Supplementation Rescues Rod Function and Preserves Photoreceptor and Retinal Morphology in Dogs, Leading the Way Toward Treating Human *PDE6A*-Retinitis Pigmentosa. *Hum Gene Ther* 2017;28:1189–201.
16 Mowat FM, Occelli LM, Bartoe JT, *et al*. Gene Therapy in a Large Animal Model of PDE6A-Retinitis Pigmentosa. *Front Neurosci* 2017;11:342.
17 Allocca M, Mussolino C, Garcia-Hoyos M, *et al*. Novel adeno-associated virus serotypes efficiently transduce murine photoreceptors. *J Virol* 2007;81:11372–80.
18 Xue K, Groppe M, Salvetti AP, *et al*. Technique of retinal gene therapy: delivery of viral vector into the subretinal space. *Eye (Lond)* 2017;31:1308–16.
19 Vingrys AJ, King-Smith PE. A quantitative scoring technique for panel tests of color vision. *Invest Ophthalmol Vis Sci* 1988;29:50–63.
20 Kelbsch C, Stingl K, Kempf M, *et al*. Objective Measurement of Local Rod and Cone Function Using Gaze-Controlled Chromatic Pupil Campimetry in Healthy Subjects. *Transl Vis Sci Technol* 2019;8:19.
21 Birch DG, Cheng P, Duncan JL, *et al*. The RUSH2A Study: Best-Corrected Visual Acuity, Full-Field Electroretinography Amplitudes, and Full-Field Stimulus Thresholds at Baseline. *Trans Vis Sci Tech* 2020;9:9.
22 Takahashi VKL, Takiuti JT, Jauregui R, *et al*. Structural disease progression in PDE6-associated autosomal recessive retinitis pigmentosa. *Ophthalmic Genet* 2018;39:610–4.
23 Roth A. Farnsworth's 28 hue test. *Bull Soc Ophtalmol Fr* 1966;66:231–8.
24 Health CAfDaTi. Clinical review report: dexamethasone (ozurdex): (allergan inc.): indication: for the treatment of adult patients with diabetic macular edema who are pseudophakic [internet]. 2018. Available: https://www.ncbi.nlm.nih.gov/books/NBK539248/
25 Seitz IP, Wozar F, Ochakovski GA, *et al*. Dose-Dependent Progression of Chorioretinal Atrophy at the Injection Site After Subretinal Injection of rAAV2/8 in Nonhuman Primates. *Ophthalmol Sci* 2024;4:100516.
26 Davis RJ, Hsu C-W, Tsai Y-T, *et al*. Therapeutic margins in a novel preclinical model of retinitis pigmentosa. *J Neurosci* 2013;33:13475–83.
27 Tuntivanich N, Pittler SJ, Fischer AJ, *et al*. Characterization of a canine model of autosomal recessive retinitis pigmentosa due to a PDE6A mutation. *Invest Ophthalmol Vis Sci* 2009;50:801–13.
28 Sakamoto K, McCluskey M, Wensel TG, *et al*. New mouse models for recessive retinitis pigmentosa caused by mutations in the Pde6a gene. *Hum Mol Genet* 2009;18:178–92.
29 Cook B, Lewis GP, Fisher SK, *et al*. Apoptotic photoreceptor degeneration in experimental retinal detachment. *Invest Ophthalmol Vis Sci* 1995;36:990–6.
30 Fisher SK, Stone J, Rex TS, *et al*. Chapter 49 Experimental retinal detachment: a paradigm for understanding the effects of induced photoreceptor degeneration. *Progress in Brain Research: Elsevier* 2001;2001:679–98.
31 Varin J, Morival C, Maillard N, *et al*. Risk Mitigation of Immunogenicity: A Key to Personalized Retinal Gene Therapy. *Int J Mol Sci* 2021;22:12818.
32 Khateb S, Nassisi M, Bujakowska KM, *et al*. Longitudinal Clinical Follow-up and Genetic Spectrum of Patients With Rod-Cone Dystrophy Associated With Mutations in PDE6A and PDE6B. *JAMA Ophthalmol* 2019;137:669–79.