







CASE REPORT

REVISED Case Report: Adult Onset Still's Disease after vaccination against Covid-19

[version 2; peer review: 2 approved]

Ujjwol Risal ¹, Anup Subedee¹, Raju Pangeni ², Rakshya Pandey²,
Suravi Pandey¹, Sudeep Adhikari ³, Buddha Basnyat ⁴

¹Internal Medicine, Hospital for Advanced Medicine and Surgery, Kathmandu, Nepal²Pulmonary and Critical Care, Hospital for Advanced Medicine and Surgery, Kathmandu, Nepal³Internal Medicine, Pyuthan Hospital, Pyuthan, Nepal⁴Oxford University Clinical Research Unit, Patan Hospital, Kathmandu, Nepal

V2 First published: 07 Dec 2021, 6:333
<https://doi.org/10.12688/wellcomeopenres.17345.1>

Latest published: 15 Aug 2022, 6:333
<https://doi.org/10.12688/wellcomeopenres.17345.2>

Abstract




Vaccination against the virus responsible for COVID-19 has become key in preventing mortality and morbidity related to the infection. Studies have shown that the benefits of vaccination outweigh the risks. However, there are concerns regarding serious adverse events of some vaccines, although they are fortunately rare. Here, we report a case of a 47-year-old female from Kathmandu who presented with high grade fever, dry cough and erythematous rash a week after exposure to the Oxford-AstraZeneca vaccine. She had hepatosplenomegaly, persistent leucocytosis, anaemia and thrombocytosis along with markedly raised inflammatory markers. Her tests for infectious causes and haematological malignancies were negative and she showed no response to multiple antibiotics. Finally, she had a dramatic response to steroids with disappearance of fever and normalization of other laboratory parameters. Hence, she was diagnosed with Adult-onset Still's Disease (AOSD). She was under methotrexate and prednisolone tapering dose and doing well as of the time of writing. The trigger for the disease was hypothesized to be the vaccine because of the strong temporal association.


Keywords

Covid-19 vaccination, AOSD

Open Peer Review

Approval Status  

	1	2
version 2 (revision) 15 Aug 2022		 view
version 1 07 Dec 2021	 view	 view

1. **Amita Aggarwal** , Sanjay GandhiPostgraduate Institute of Medical Sciences,
Lucknow, India2. **Sankha S. Chakrabarti** , Banaras Hindu
University, Varanasi, India

Any reports and responses or comments on the article can be found at the end of the article.

Corresponding author: Ujjwol Risal (ujjwolr@gmail.com)

Author roles: **Risal U:** Conceptualization, Data Curation, Resources, Writing – Original Draft Preparation, Writing – Review & Editing; **Subedee A:** Conceptualization, Resources, Supervision, Writing – Review & Editing; **Pangeni R:** Resources, Supervision, Writing – Review & Editing; **Pandey R:** Data Curation, Resources, Writing – Review & Editing; **Pandey S:** Resources, Supervision, Writing – Original Draft Preparation; **Adhikari S:** Resources, Supervision, Writing – Review & Editing; **Basnyat B:** Supervision, Writing – Review & Editing

Competing interests: No competing interests were disclosed.

Grant information: The author(s) declared that no grants were involved in supporting this work.

Copyright: © 2022 Risal U *et al.* This is an open access article distributed under the terms of the [Creative Commons Attribution License](#), which permits unrestricted use, distribution, and reproduction in any medium, provided the original work is properly cited.

How to cite this article: Risal U, Subedee A, Pangeni R *et al.* **Case Report: Adult Onset Still's Disease after vaccination against Covid-19 [version 2; peer review: 2 approved]** Wellcome Open Research 2022, 6:333 <https://doi.org/10.12688/wellcomeopenres.17345.2>

First published: 07 Dec 2021, 6:333 <https://doi.org/10.12688/wellcomeopenres.17345.1>

REVISED Amendments from Version 1

Manuscript has been revised as per the comments given by the authors. Language editing has been done. Few more details have been added for increasing clarity. Importantly, the AEFI causality form has been uploaded as supplementary file as per the reviewer's suggestion.

Any further responses from the reviewers can be found at the end of the article

Introduction

COVID-19 is a major pandemic currently affecting the whole world, and Nepal is no exception. As of 31st March 2022, a total of 978,402 people had been infected and 11951 people have already lost their lives in Nepal¹. However, various vaccines have been tested and made available which are highly effective in preventing both the morbidity and mortality associated with the disease². However, there are concerns regarding adverse events following vaccination³. Adult-onset Still's Disease (AOSD) is a multisystem auto-inflammatory disease characterized by high grade fever, inflammatory arthritis, and an evanescent rash. It is associated with profound systemic inflammation marked by high inflammatory markers, leucocytosis and high ferritin levels. The diagnosis is made clinically after ruling out other aetiologies⁴. We describe a case of AOSD following administration of the Oxford-AstraZeneca vaccine in Nepal. AOSD is a rare autoinflammatory disease and diagnosis of this case itself is a challenge, especially in a country like Nepal, where rheumatology is a budding speciality. This case follows only two other similar reported cases after vaccination against COVID-19^{5,6}.

Case presentation

A 47-year-old female from Kathmandu, Nepal, non-smoker presented in April 2021 to the out-patient department of a tertiary hospital in Kathmandu, with a history of intermittent fever and sore throat for nine days. After three days of fever, she developed itchy erythematous rashes bilaterally involving thighs, legs and hands, especially during the spiking of fever. She had received the first dose of the Oxford-AstraZeneca vaccine seven days prior to the onset of fever. She had no notable past medical and family history. When she presented to us, she was already on two antibiotics, namely levofloxacin 750 mg and azithromycin 500 mg, once daily for a couple of days from a local medical shop. Upon examination, her temperature was 38.55^o C, and had erythematous rashes over bilateral legs and hands (Figure 1). The remaining systemic examination found no further anomalies. SARS-CoV-2 polymerase chain reaction (PCR) was negative. The initial laboratory investigations (Table 1) showed anaemia with neutrophilic leucocytosis and thrombocytosis, raised C-reactive protein (CRP), markedly raised ferritin, and mild hepatitis. Ultrasound of the abdomen showed hepatosplenomegaly. She was admitted with intravenous ceftriaxone 2 g once daily and oral doxycycline 100 mg twice daily. Blood and urine cultures were performed, which later revealed no growth. Serological

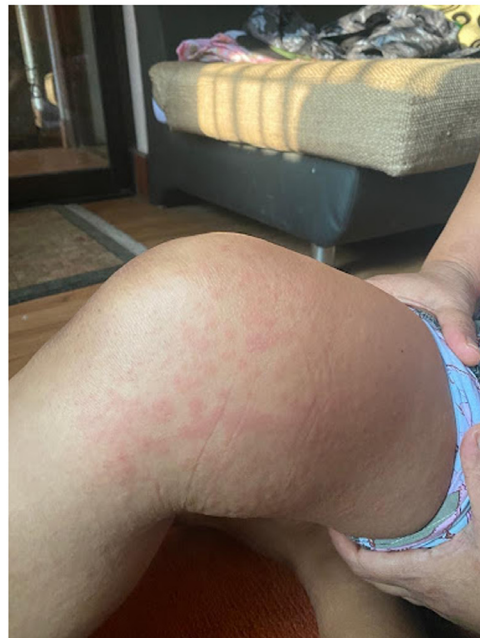

Figure 1. Erythematous macular rash involving right thigh of the patient.

tests for dengue, scrub typhus, leptospirosis and malaria were negative. There was no response to antibiotics after 72 hours. Further investigations were performed considering possible non-infectious causes of fever. Her antinuclear antibody (ANA) was weakly positive with a fine speckled pattern. Rheumatoid factor, anti-citrullinated peptide antibodies (ACPA), and anti-neutrophil cytoplasmic antibodies (ANCA) were negative. Her bone marrow cytology was normal. On the fourth day of her admission, she also developed pain and swelling of her left elbow. On examination, the elbow joint was warm and tender with restriction of movement. At this time, AOSD was considered as the most probable diagnosis since she fulfilled three major and three minor criteria as defined by Yamaguchi⁷. She was then started on prednisolone at 1 mg/kg (60 mg) once daily, with continuation of the ongoing antibiotics. After starting prednisolone, she had no further episodes of fever. Her joint pain improved, and she experienced no further rash. Thus the final diagnosis of AOSD was made based on the classification criteria and a dramatic response to the steroid⁷. Methotrexate 7.5 mg per week was started. The antibiotics were stopped on the seventh day, and she was discharged with prednisolone and methotrexate. She is under regular follow-up for her condition at the time of writing this report. During her latest follow-up in September 2021, she was afebrile and had no other symptoms. She is currently receiving prednisolone 10 mg daily and methotrexate 15 mg per week. She has not received any further dose of the vaccination.

Discussion

Vaccination against COVID-19 has become the most effective way to curb the current pandemic and its effects on activities

Table 1. Laboratory investigations of the patient.

Laboratory parameters	Normal range	2021 April 2 (day of admission)	2021 April 4 (second day of admission)	2021 April 6 (fourth day- steroid started)	2021 April 7 (one day after starting steroid)	2021 September 9 (last follow-up)
Hemoglobin (gm/dl)	12.1- 15.1	9.3	9.2	9.8	9	12.5
White cell count(/mm ³)	4500-11000	17050	18100	24300	16150	7700
Neutrophil percentage	55- 70	86	89	91	86	57
Platelets(/mm ³)	150000-450000	471000	687000	1400000	956000	213000
C-Reactive Protein(mg/dL)	0.8- 1.0	150	>150	>150	108	0.8
Serum Ferritin(ng/ml)	24- 336	2914.6				
Aspartate transaminase(IU/L)	5- 40	218				28
Alanine transaminase(IU/L)	7- 55	194				73

worldwide² As of the time of writing this report, several vaccines had undergone trials and been given approval to be rolled out in several countries. Minor side effects after vaccination are fairly common; however, there have been some concerns regarding rare but serious adverse events of some vaccines³. For example, cerebral venous sinus thrombosis has been described in some patients who have received the Ad26.COV2.S (Janssen/Johnson & Johnson) COVID-19 vaccine⁸. Likewise, several cases of thrombosis have developed following vaccination with the Oxford-AstraZeneca vaccine⁹. Autoimmune diseases themselves are rare, and those developing following vaccination are even rarer. Recently some cases of autoimmune diseases following COVID-19 vaccination have been described¹⁰⁻¹².

Adult-onset Still's disease (AOSD) is a rare auto-inflammatory disorder characterized by a high spiking fever, arthralgia (with or without synovitis), maculo-papular salmon-pink evanescent skin rash, striking leucocytosis with neutrophilia⁴. There is no definitive confirmatory test for AOSD, but there are a few sets of clinical criteria which are used in the diagnosis⁷. In one study in France, the incidence of the disease was found to be 0.16 per 100,000 in the population¹³. The aetiology of the disease is unknown. Various genetic and environmental factors have been implicated in the causation of the disease, but there is no definite evidence. The pathogenesis involves activation of the innate immune system with subsequent cytokine overproduction, especially interleukins IL-1 β , IL-18, IL-6, TNF- α , and IFN- γ ⁴. Several infectious agents have been postulated to trigger the disease in genetically predisposed individuals. It has been proposed that the interplay between host genetic factors, autoimmune mechanisms, and antigens could trigger AOSD^{4,14,15}. There have been some case reports of AOSD following a COVID-19 infection in patients who had recently recovered from the illness^{16,17}. However, only one case of AOSD has been reported following vaccination with the mRNA-1273 COVID-19 vaccine (Moderna), and one after ChAdOx1 nCoV-19 (Oxford-AstraZeneca) vaccine^{5,6}. There are two possible ways the vaccine could have triggered the

disease; one is through the release of various cytokines by the spike protein and the other is the activation of immune system by the adenovirus vector used in the vaccine. It is well-known from various studies that COVID-19 infection causes a release of various cytokines and multi-organ failure (secondary hemophagocytic lymphohistiocytosis). The main cytokines with elevated levels in this condition are IL-1 and IL-6, which are the same cytokines that are activated in AOSD, which points towards a similar mechanism of immune activation¹⁸. As in AOSD, IL-1 and IL-6 blockade has been successful in the management of patients with severe COVID-19 infection¹⁹. The Oxford-AstraZeneca vaccine is based on a replication-incompetent chimpanzee adenovirus vector that expresses the SARS-CoV-2 spike protein²⁰. Many cases of viral infections, including by adenoviruses, have been reported to trigger AOSD⁴. It is possible that the adenovirus vector used in the vaccine could have triggered the same mechanism as that triggered by the native virus. However, the level of SARS-CoV-2 anti-spike protein IgG in the serum could not be performed which could have shown some light regarding the possible pathogenesis in our patient. Whatever the pathogenesis, the strong temporal association between the vaccination and the onset of symptoms made us suspect the vaccine to be the trigger, although it could be mere coincidence. Further studies are needed to prove the causation.

Conclusions

AOSD is a rare disease that has been associated with environmental triggers in genetically susceptible hosts. Vaccination against COVID-19 could be a potential trigger for its development for which further studies are required.

Consent

Written informed consent for publication of their clinical details and/or clinical images was obtained from the patient.

Data availability

All data underlying the results are available as part of the article and no additional source data are required.

References

1. [reliefweb.int](#). [online] 2022 March 31 [cited 2022 March 31]; 2022.
2. World Health Organization: [online] 2021 Sep 15 [cited 2021 sep 15] 2021. [Reference Source](#)
3. Menni C, Klaser K, May A, *et al.*: **Vaccine side-effects and SARS-CoV-2 infection after vaccination in users of the COVID Symptom Study app in the UK: a prospective observational study.** *Lancet Infect Dis.* 2021; **21**(7): 939–949. [PubMed Abstract](#) | [Publisher Full Text](#) | [Free Full Text](#)
4. Wang MY, Jia JC, Yang CD, *et al.*: **Pathogenesis, disease course, and prognosis of adult-onset Still's disease: an update and review.** *Chin Med J (Engl).* 2019; **132**(23): 2856–2864. [PubMed Abstract](#) | [Publisher Full Text](#) | [Free Full Text](#)
5. Magliulo D, Narayan S, Ue F, *et al.*: **Adult-onset Still's disease after mRNA COVID-19 vaccine.** *Lancet Rheumatol.* 2021; **3**(10): e680–e682. [PubMed Abstract](#) | [Publisher Full Text](#) | [Free Full Text](#)
6. Leone F, Cerasuolo PG, Bosello SL, *et al.*: **Adult-onset Still's disease following COVID-19 vaccination.** *Lancet Rheumatol.* 2021; **3**(10): e678–e680. [PubMed Abstract](#) | [Publisher Full Text](#) | [Free Full Text](#)
7. Yamaguchi M, Ohta A, Tsunematsu T, *et al.*: **Preliminary criteria for classification of adult Still's disease.** *J Rheumatol.* 1992; **19**(3): 424–30. [PubMed Abstract](#)
8. See I, Su JR, Lale A, *et al.*: **US Case Reports of Cerebral Venous Sinus Thrombosis With Thrombocytopenia After Ad26.COVS.2 Vaccination, March 2 to April 21, 2021.** *JAMA.* 2021; **325**(24): 2448–2456. [PubMed Abstract](#) | [Publisher Full Text](#) | [Free Full Text](#)
9. Greinacher A, Thiele T, Warkentin TE, *et al.*: **Thrombotic thrombocytopenia after ChAdOx1 nCov-19 vaccination.** *N Engl J Med.* 2021; **384**(22): 2092–101. [PubMed Abstract](#) | [Publisher Full Text](#) | [Free Full Text](#)
10. Tarawneh O, Tarawneh H: **Immune thrombocytopenia in a 22-year-old post Covid-19 vaccine.** *Am J Hematol.* 2021; **96**(5): E133–E134. [PubMed Abstract](#) | [Publisher Full Text](#) | [Free Full Text](#)
11. Bril F, Al Diffalha S, Dean M, *et al.*: **Autoimmune hepatitis developing after coronavirus disease 2019 (COVID-19) vaccine: Causality or casualty?** *J Hepatol.* 2021; **75**(1): 222–224. [PubMed Abstract](#) | [Publisher Full Text](#) | [Free Full Text](#)
12. Baimukhamedov C, Makhmudov S, Botabekova A: **Seropositive rheumatoid arthritis after vaccination against SARS-CoV-2 infection.** *Int J Rheum Dis.* 2021; **24**(11): 1440–1441. [PubMed Abstract](#) | [Publisher Full Text](#) | [Free Full Text](#)
13. Magadur-Joly G, Billaud E, Barrier JH, *et al.*: **Epidemiology of adult Still's disease: estimate of the incidence by a retrospective study in west France.** *Ann Rheum Dis.* 1995; **54**(7): 587–90. [PubMed Abstract](#) | [Publisher Full Text](#) | [Free Full Text](#)
14. Govoni M, Bortoluzzi A, Rossi D, *et al.*: **How I treat patients with adult onset Still's disease in clinical practice.** *Autoimmun Rev.* 2017; **16**(10): 1016–23. [PubMed Abstract](#) | [Publisher Full Text](#)
15. Perez C, Artola V: **Adult Still's disease associated with Mycoplasma pneumoniae infection.** *Clin Infect Dis.* 2001; **32**(6): e105–6. [PubMed Abstract](#) | [Publisher Full Text](#)
16. Bamidis AD, Koehler P, Di Cristanziano V: **First manifestation of adult-onset Still's disease after COVID-19.** *Lancet Rheumatol.* 2021; **3**(5): e319–e321. [PubMed Abstract](#) | [Publisher Full Text](#) | [Free Full Text](#)
17. Alshablan A, Jabbar R, Tayeb S: **Diagnosis of adult onset Still's disease in a patient who has recovered from coronavirus-19.** *Clin Med Insights Case Rep.* 2021; **14**: 1179547621996306. [PubMed Abstract](#) | [Publisher Full Text](#) | [Free Full Text](#)
18. Mehta P, McAuley DF, Brown M, *et al.*: **COVID-19: consider cytokine storm syndromes and immunosuppression.** *Lancet.* 2020; **395**(10229): 1033–4. [PubMed Abstract](#) | [Publisher Full Text](#) | [Free Full Text](#)
19. Cavalli G, Larcher A, Tomelleri A: **Interleukin-1 and interleukin-6 inhibition compared with standard management in patients with COVID-19 and hyperinflammation: a cohort study.** *Lancet Rheumatol.* 2021; **3**(4): e253–e261. [PubMed Abstract](#) | [Publisher Full Text](#) | [Free Full Text](#)
20. Folegatti PM, Ewer KJ, Aley PK, *et al.*: **Safety and immunogenicity of the ChAdOx1 nCoV-19 vaccine against SARS-CoV-2: a preliminary report of a phase 1/2, single-blind, randomised controlled trial.** *Lancet.* 2020; **396**(10249): 467–78. [PubMed Abstract](#) | [Publisher Full Text](#) | [Free Full Text](#)

Open Peer Review

Current Peer Review Status:  

Version 2

Reviewer Report 22 August 2022

<https://doi.org/10.21956/wellcomeopenres.19936.r51988>

© 2022 Chakrabarti S. This is an open access peer review report distributed under the terms of the [Creative Commons Attribution License](#), which permits unrestricted use, distribution, and reproduction in any medium, provided the original work is properly cited.



Sankha S. Chakrabarti 

Department of Geriatric Medicine, Institute of Medical Sciences, Banaras Hindu University, Varanasi, Uttar Pradesh, India

Acceptable, but I could not access the supplementary file of causality assessment. Please ensure it is added.

Competing Interests: No competing interests were disclosed.

Reviewer Expertise: Geriatric pharmacovigilance, Geriatric neuropsychiatry, COVID-19 (vaccines)

I confirm that I have read this submission and believe that I have an appropriate level of expertise to confirm that it is of an acceptable scientific standard.

Version 1

Reviewer Report 21 March 2022

<https://doi.org/10.21956/wellcomeopenres.19175.r49106>

© 2022 Chakrabarti S. This is an open access peer review report distributed under the terms of the [Creative Commons Attribution License](#), which permits unrestricted use, distribution, and reproduction in any medium, provided the original work is properly cited.



Sankha S. Chakrabarti 

¹ Department of Geriatric Medicine, Institute of Medical Sciences, Banaras Hindu University, Varanasi, Uttar Pradesh, India

² Department of Geriatric Medicine, Institute of Medical Sciences, Banaras Hindu University,

Varanasi, Uttar Pradesh, India

This is an interesting and well managed case.

1. Kindly update the case and death numbers in Nepal to March 2022 figures
2. English language editing is much needed to improve clarity, in the Abstract, Introduction and Case Presentation parts.
3. Use the word hepatitis instead of transaminitis.
4. Use bone marrow cytology (or histopathological examination of bone marrow biopsy sample) whichever is suitable, instead of histopathological bone marrow examination.
5. Please mention the consideration made by the authors while starting high dose steroid. What etiology or condition did they have in mind at the time?
6. Along with the autoimmune thrombocytopenia and hepatitis referenced by the authors (refs 10,11) after COVID-19 vaccination, cases of the related condition rheumatoid arthritis after COVID-19 vaccination may also be mentioned as pathogenesis is broadly linked to Still's disease.
7. The authors discuss two main pathogenetic hypotheses. These may be split clearly in the written text for clarity (adenoviral vector induced and inflammatory cytokines induced). The direct toxicity of Spike protein or cross-reactive antibodies may be mentioned as alternative pathogenetic models. Currently, this is a bit mixed up.
8. Causality assessment file as per old version (not new version) WHO scale for adverse events following immunization must be provided as supplementary material and the causality classification done accordingly- Definite or Probable or Possible, etc.
9. Optional but would be good- If possible the authors should mention whether the patient received the second dose also, and the SARS-CoV-2 anti-Spike IgG level in serum. High levels may be linked to adverse events. Even if not done, I would advise authors to perform this on a follow-up visit for their own knowledge.

Is the background of the case's history and progression described in sufficient detail?

Yes

Are enough details provided of any physical examination and diagnostic tests, treatment given and outcomes?

Yes

Is sufficient discussion included of the importance of the findings and their relevance to future understanding of disease processes, diagnosis or treatment?

Yes

Is the case presented with sufficient detail to be useful for other practitioners?

Yes

Competing Interests: No competing interests were disclosed.

Reviewer Expertise: Geriatric pharmacovigilance, Geriatric neuropsychiatry, COVID-19 (vaccines)

I confirm that I have read this submission and believe that I have an appropriate level of expertise to confirm that it is of an acceptable scientific standard, however I have significant reservations, as outlined above.

Author Response 10 Aug 2022

Sudeep Adhikari

Dear reviewer,

Thank you for your constructive comments that have certainly helped improved the manuscript.

Below are point by point responses to your comments.

1. Kindly update the case and death numbers in Nepal to March 2022 figures
 1. Answer- Case and death numbers have been updated.
2. English language editing is much needed to improve clarity, in the Abstract, Introduction and Case Presentation parts.
 1. Answer- Revised as per the suggestion.
3. Use the word hepatitis instead of transaminitis.
 1. Answer- Hepatitis has been used.
4. Use bone marrow cytology (or histopathological examination of bone marrow biopsy sample) whichever is suitable, instead of histopathological bone marrow examination.
 1. Answer- Bone marrow cytology has been used.
5. Please mention the consideration made by the authors while starting high dose steroid. What etiology or condition did they have in mind at the time?
 1. Answer- The diagnosis of AOSD as per the Yamaguchi criteria was considered prior to giving high dose steroids.
6. Along with the autoimmune thrombocytopenia and hepatitis referenced by the authors (refs 10,11) after COVID-19 vaccination, cases of the related condition rheumatoid arthritis after COVID-19 vaccination may also be mentioned as pathogenesis is broadly linked to Still's disease.
 1. Answer- Another article describing the development of seropositive RA has been added in the reference 12.
7. The authors discuss two main pathogenetic hypotheses. These may be split clearly in the written text for clarity (adenoviral vector induced and inflammatory cytokines induced). The direct toxicity of Spike protein or cross-reactive antibodies may be mentioned as alternative pathogenetic models. Currently, this is a bit mixed up.
 1. Answer- Revised as per the suggestion.
8. Causality assessment file as per old version (not new version) WHO scale for adverse events following immunization must be provided as supplementary material and the

causality classification done accordingly- Definite or Probable or Possible, etc.

1. Answer- Causality assessment file has been added as supplementary material.

9. Optional but would be good- If possible the authors should mention whether the patient received the second dose also, and the SARS-CoV-2 anti-Spike IgG level in serum. High levels may be linked to adverse events. Even if not done, I would advise authors to perform this on a follow-up visit for their own knowledge.

1. Answer- The patient did not receive the second dose of the vaccine. And the serum level of the anti-spike protein IgG was not performed as it was unavailable.

Competing Interests: No competing interests were disclosed.

Reviewer Report 31 January 2022

<https://doi.org/10.21956/wellcomeopenres.19175.r48155>

© 2022 Aggarwal A. This is an open access peer review report distributed under the terms of the [Creative Commons Attribution License](#), which permits unrestricted use, distribution, and reproduction in any medium, provided the original work is properly cited.



Amita Aggarwal 

¹ Department of Clinical Immunology and Rheumatology, Sanjay Gandhi Postgraduate Institute of Medical Sciences, Lucknow, Uttar Pradesh, India

² Department of Clinical Immunology and Rheumatology, Sanjay Gandhi Postgraduate Institute of Medical Sciences, Lucknow, Uttar Pradesh, India

The authors describe a case of AOSD following COVID-19 vaccination. Though rheumatic disease flare is a known complication of vaccination, development of new disease is less common. AOSD has been reported earlier with COVID-19 as well as with vaccination.

This case highlights that if you have persistent fever, leucocytosis thrombocytosis rash and arthritis and no infectious agent or autoantibodies are negative AOSD should be considered.

AOSD is a diagnosis of exclusion thus it should be emphasized that common diseases must be excluded before prescribing steroids.

Is the background of the case's history and progression described in sufficient detail?

Yes

Are enough details provided of any physical examination and diagnostic tests, treatment given and outcomes?

Yes

Is sufficient discussion included of the importance of the findings and their relevance to

future understanding of disease processes, diagnosis or treatment?

Yes

Is the case presented with sufficient detail to be useful for other practitioners?

Yes

Competing Interests: No competing interests were disclosed.

Reviewer Expertise: Rheumatology

I confirm that I have read this submission and believe that I have an appropriate level of expertise to confirm that it is of an acceptable scientific standard.

Author Response 10 Aug 2022

Sudeep Adhikari

Dear Reviewer,
Thank you for your feedback to this manuscript.

Competing Interests: none